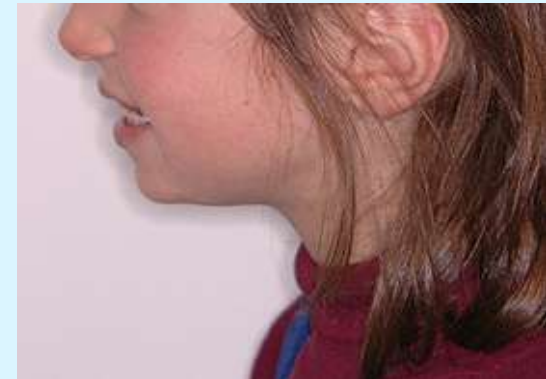
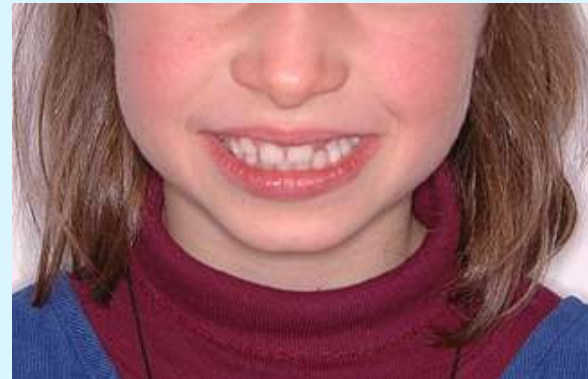
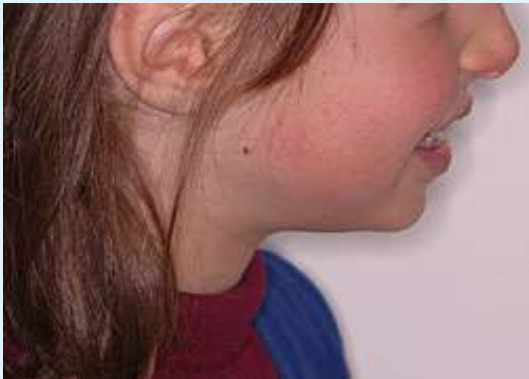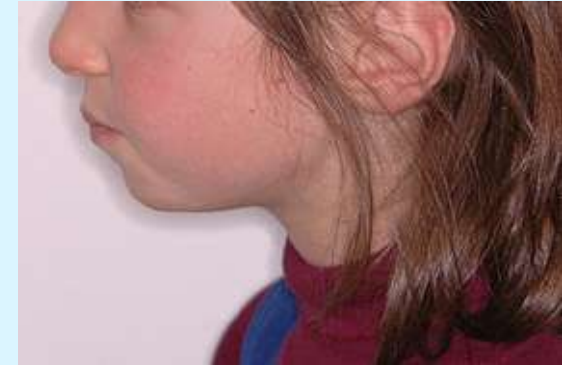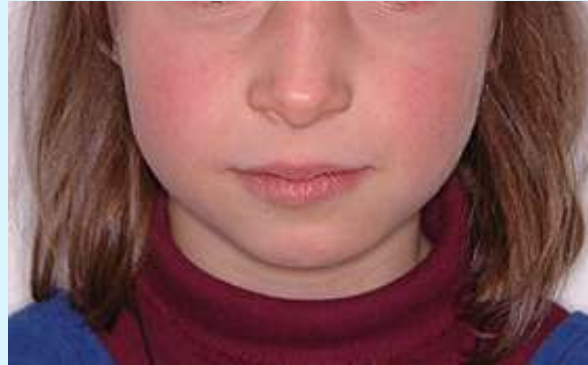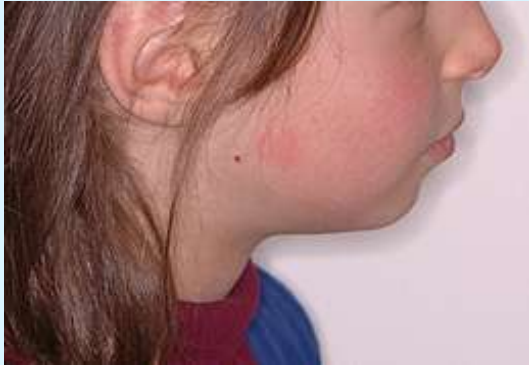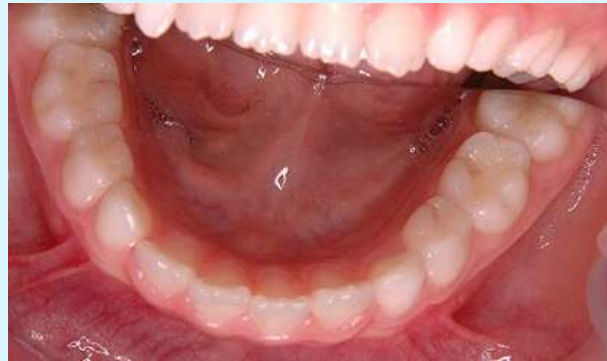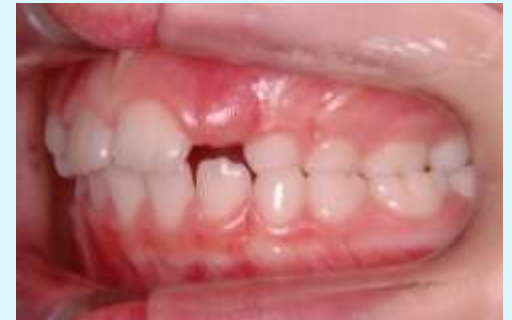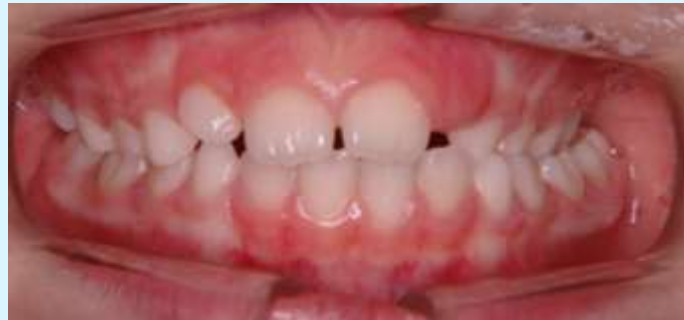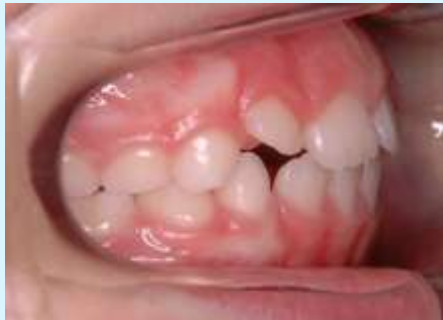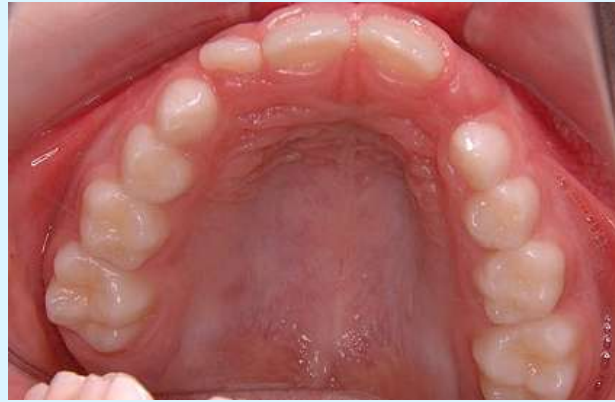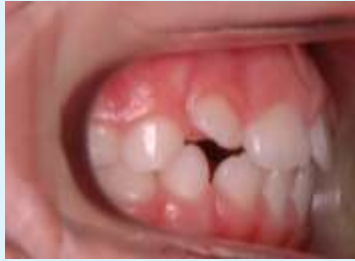Diagnosis

- Asym.dentoalv. CL II/1
- Cross-bite left → MLD left

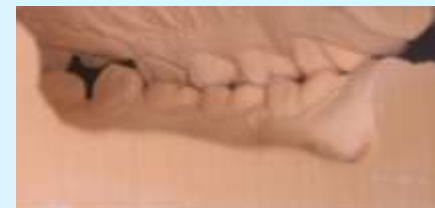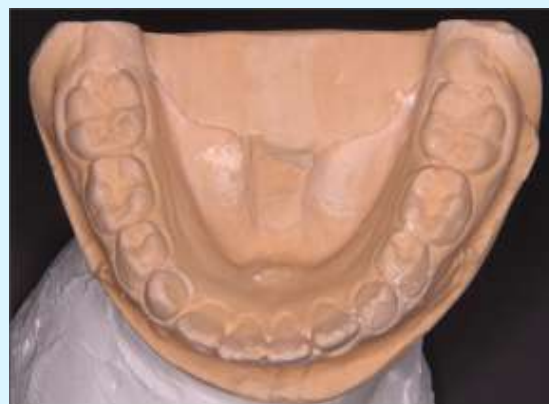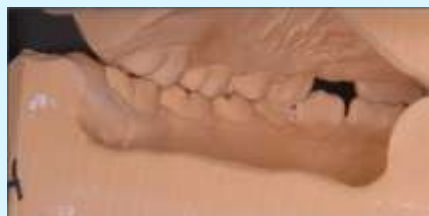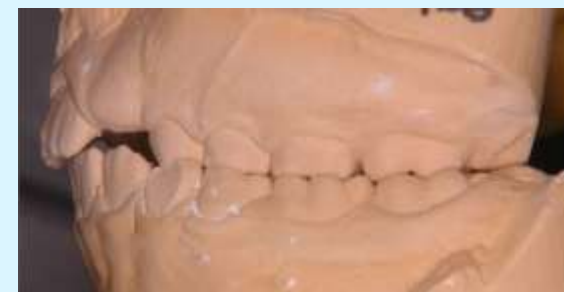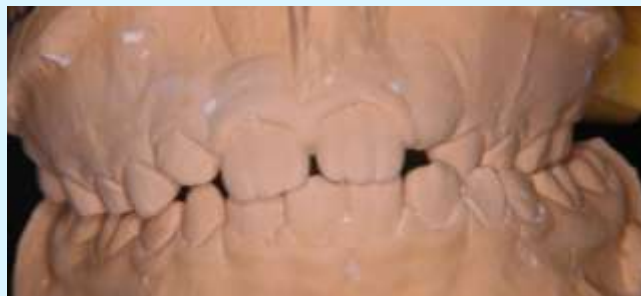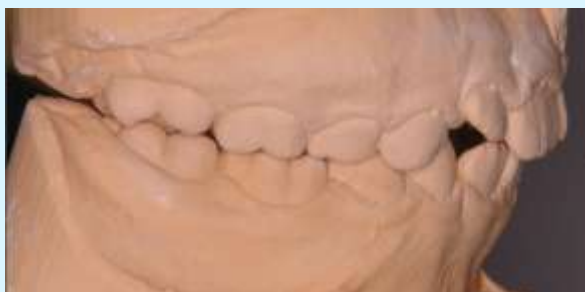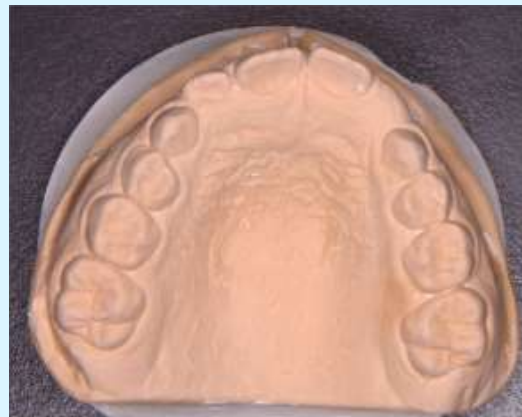Before FKO 2006-11



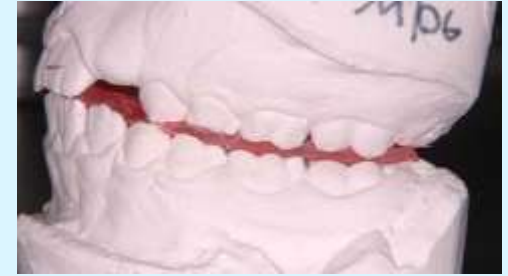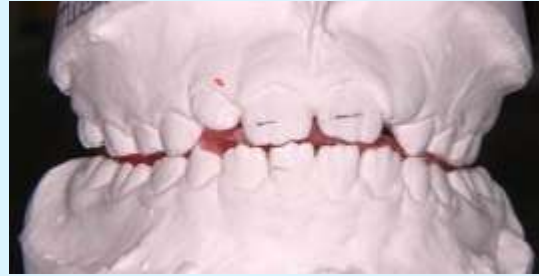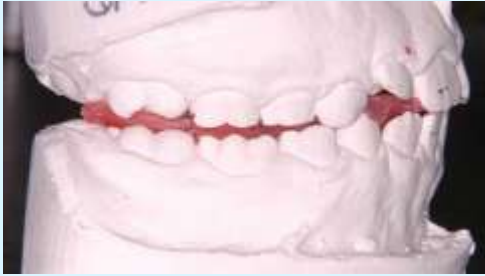Before FKO 2006-11



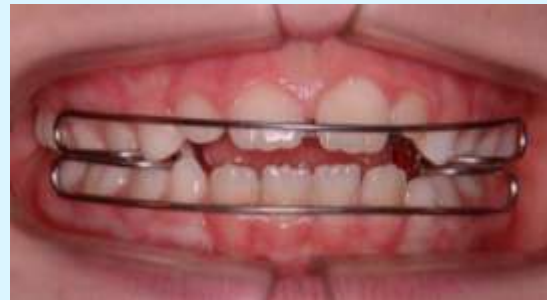Before FKO 2006-11



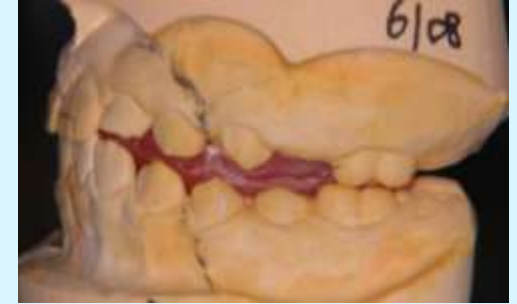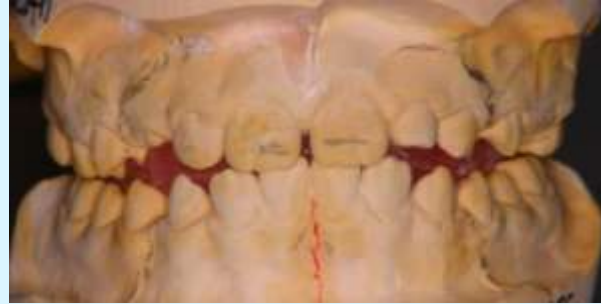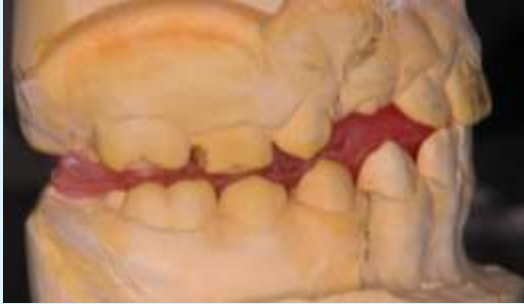1. Konstruktionsbiss



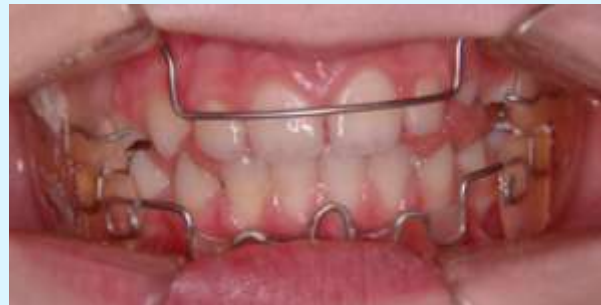
EOA



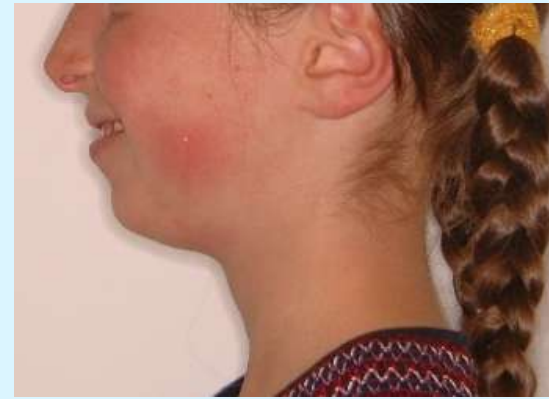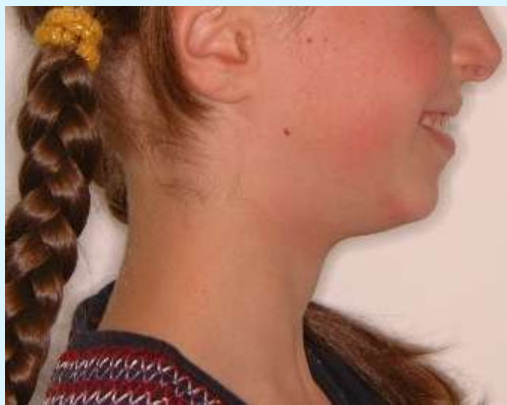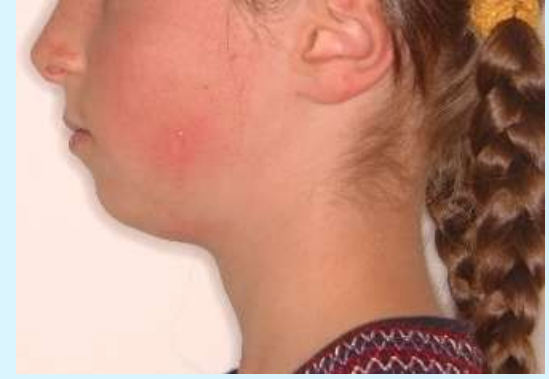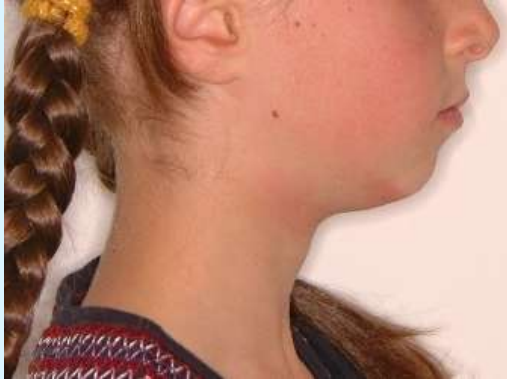2. Konstruktionsbiss



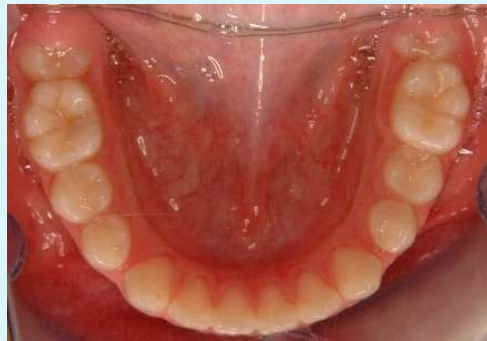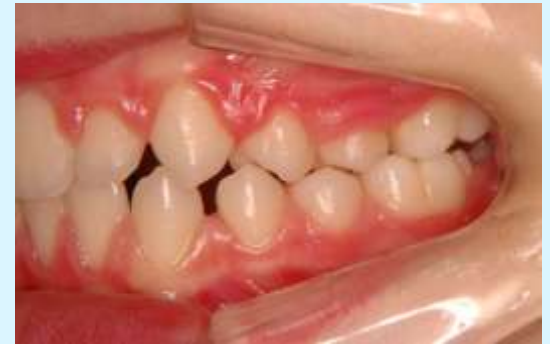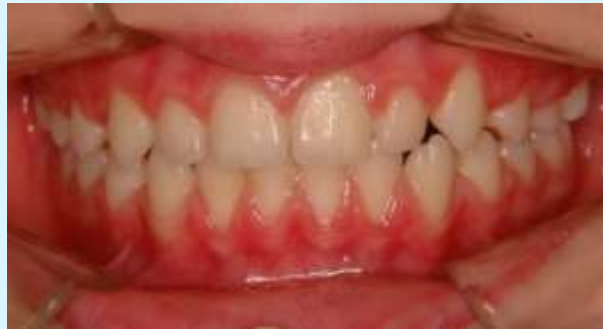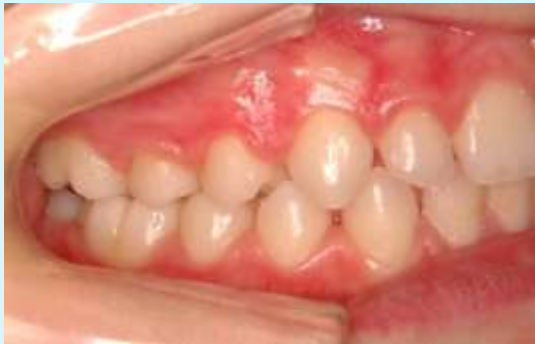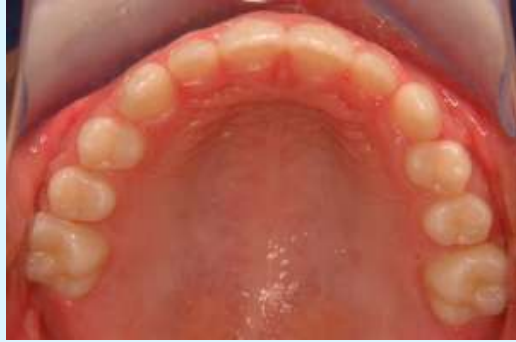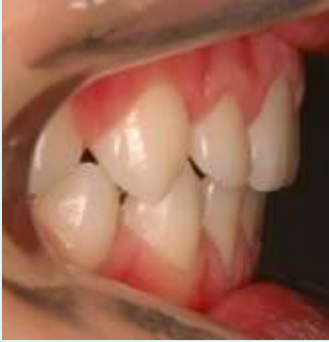Fränkel



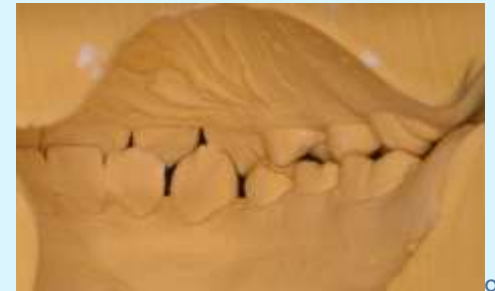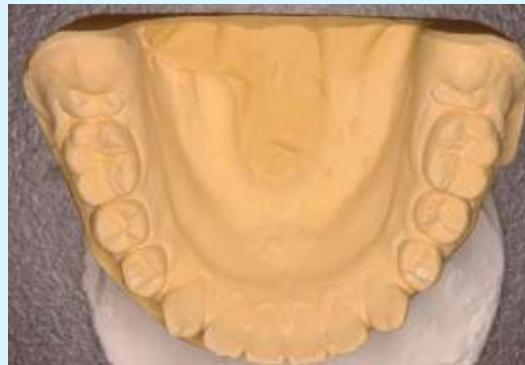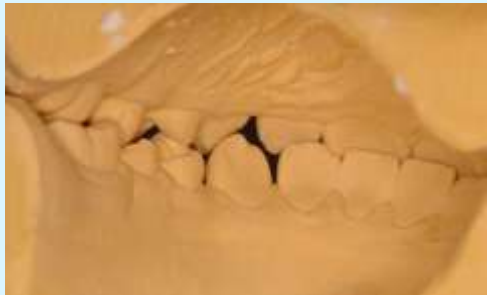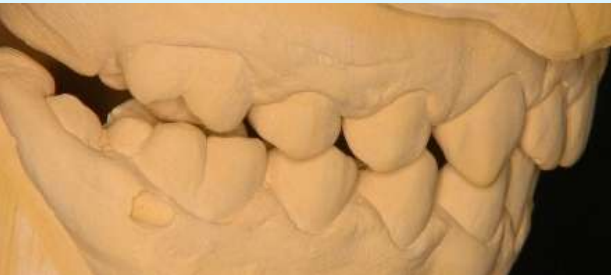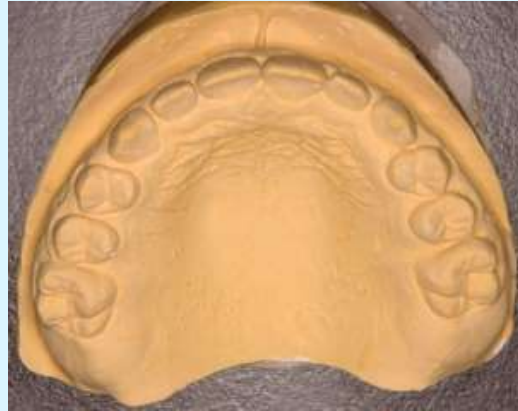After FKO 2008-09



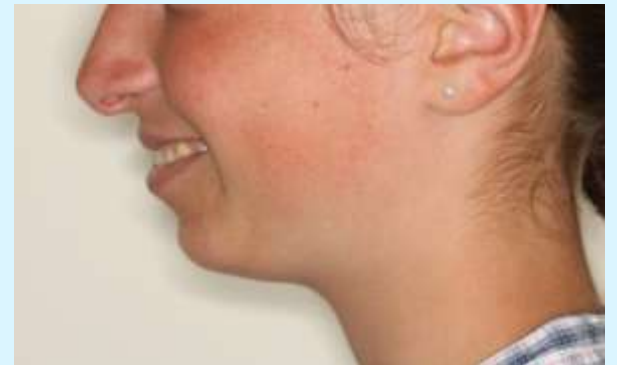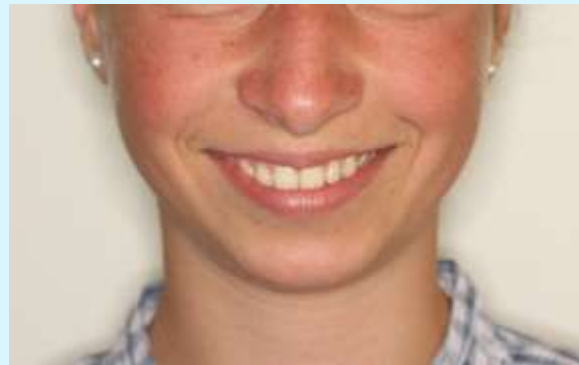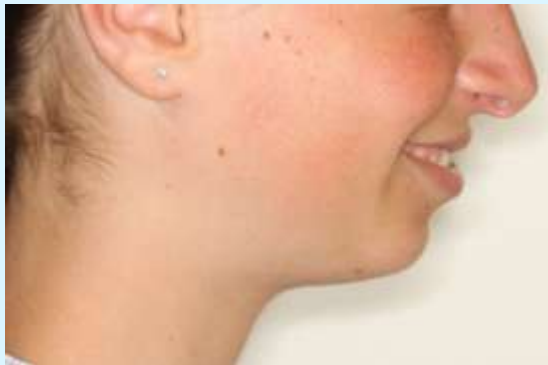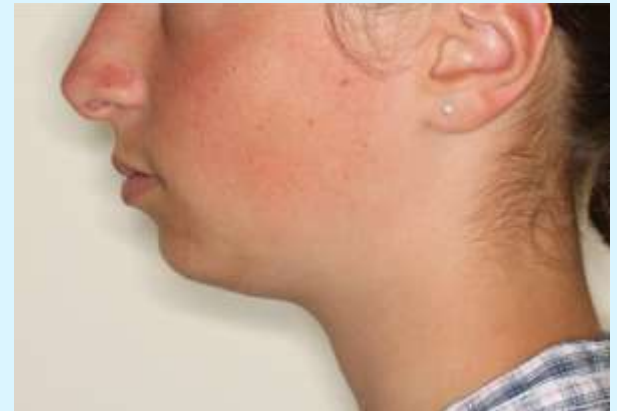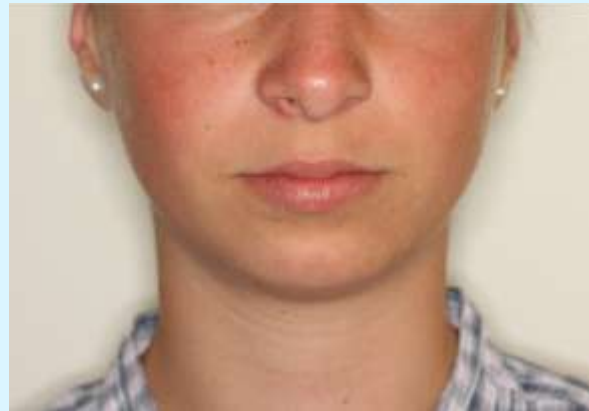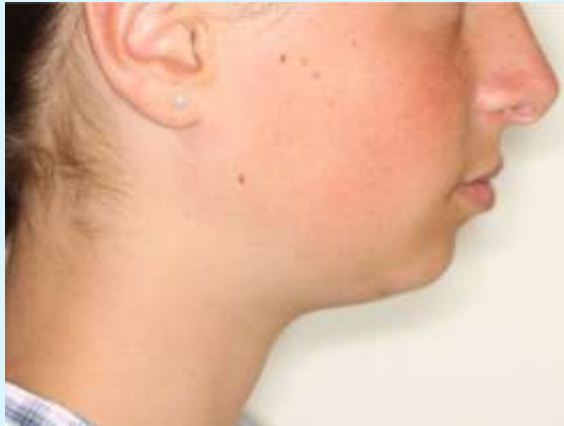After FKO 2008-09



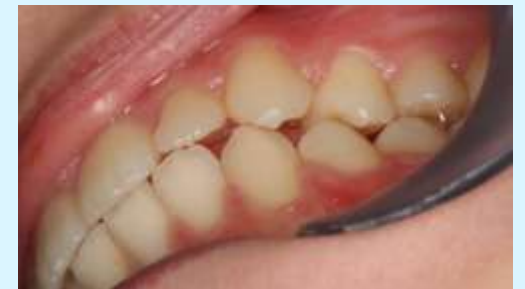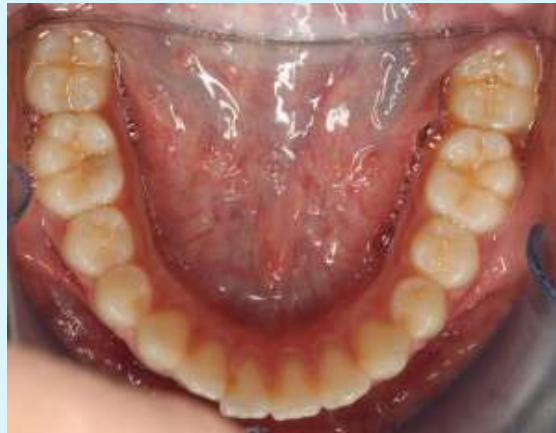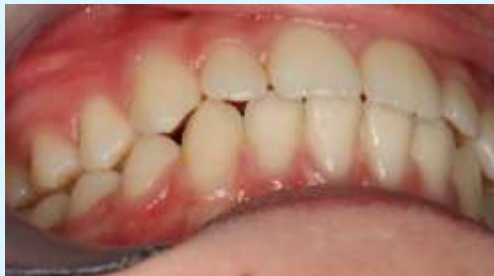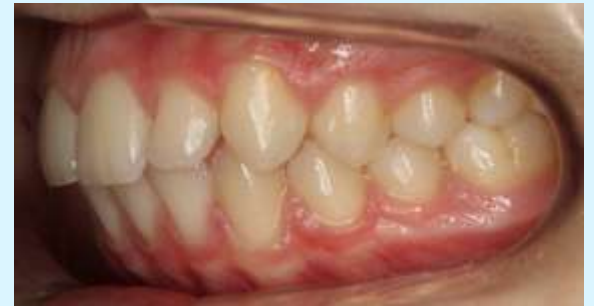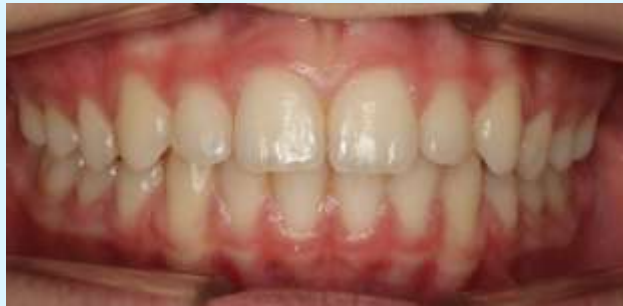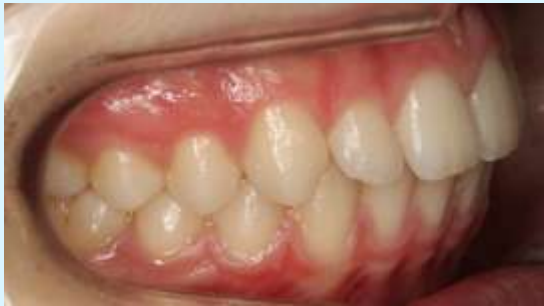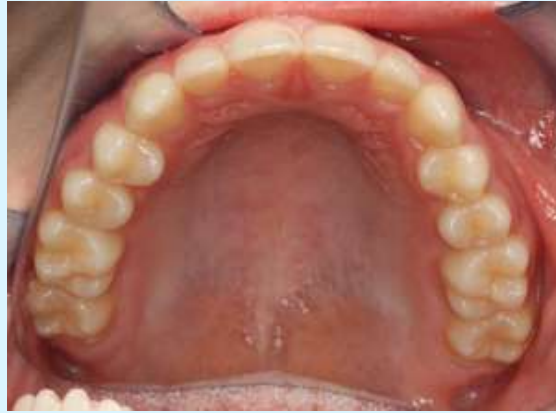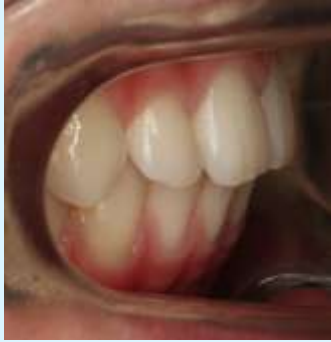FKO 2008-09



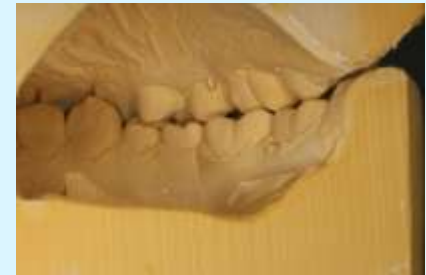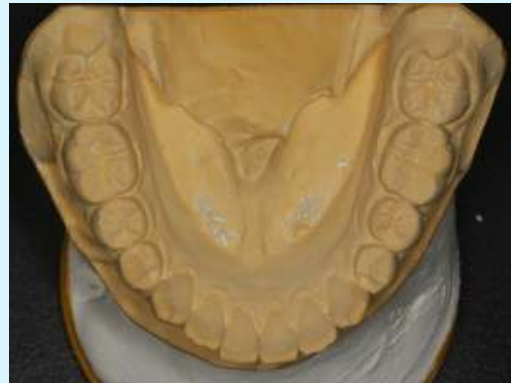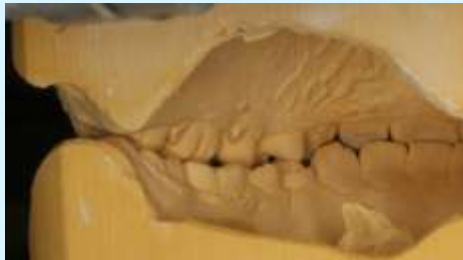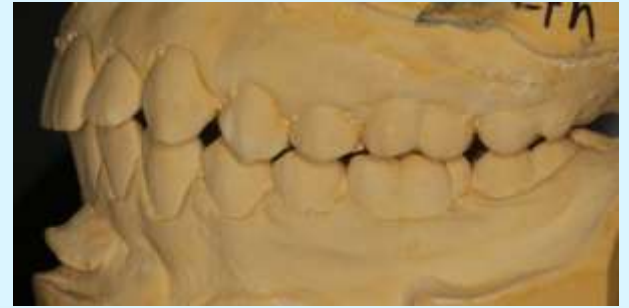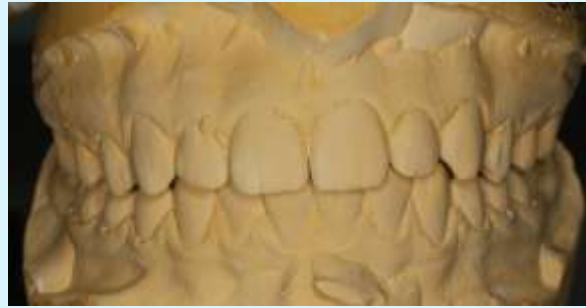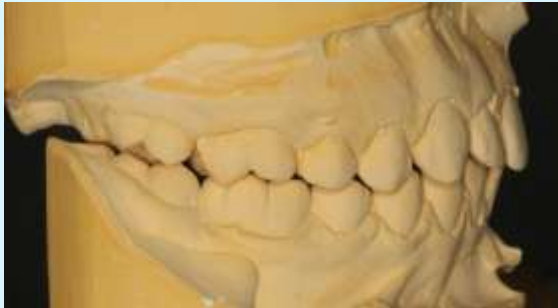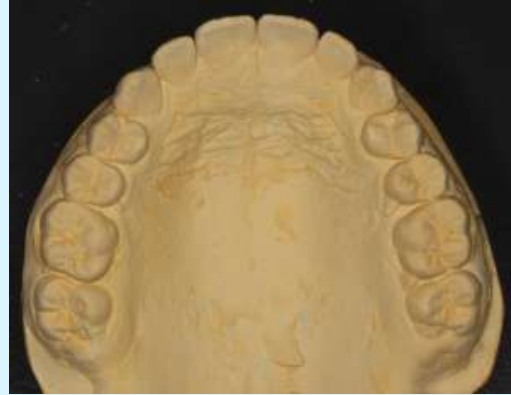After FKO 2013-08



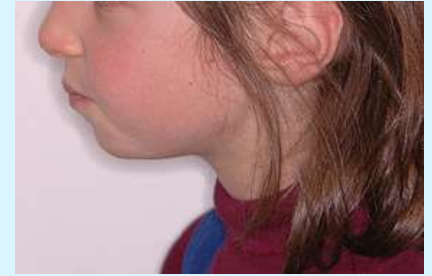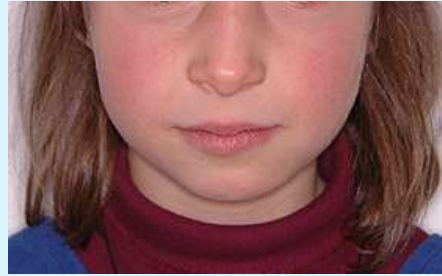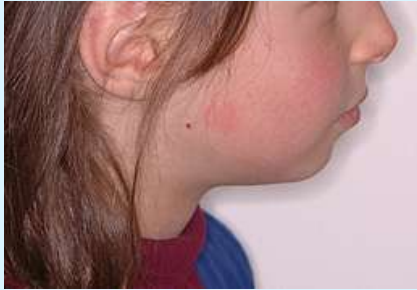After Fko 2012-04



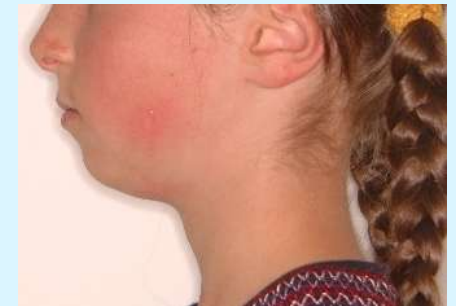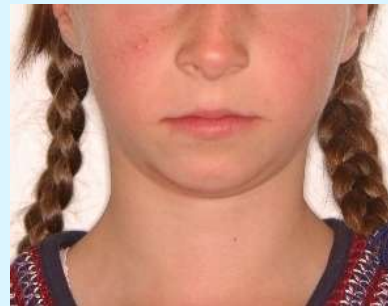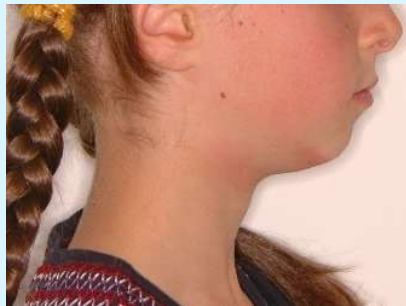After FKO 2012-04



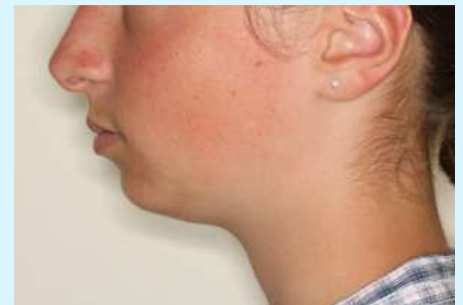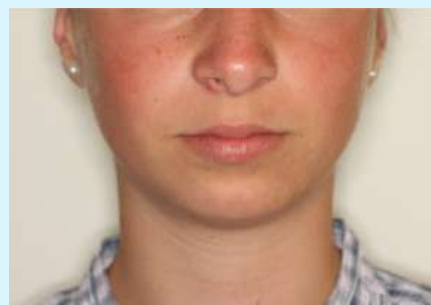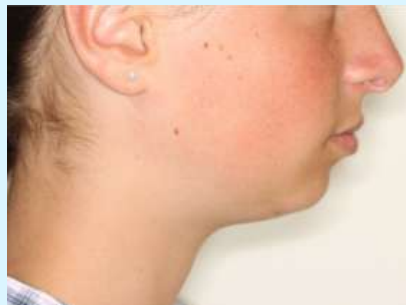Before FKO 2006-11



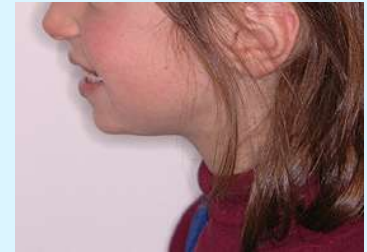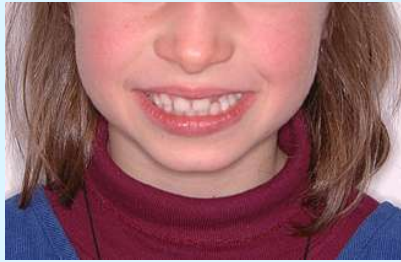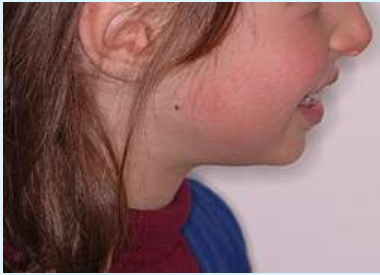After FKO 2008-09



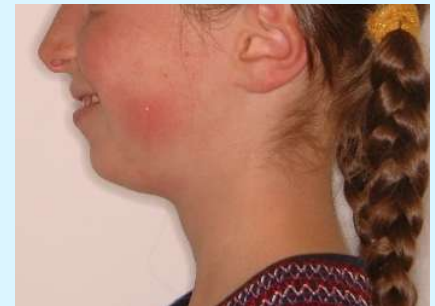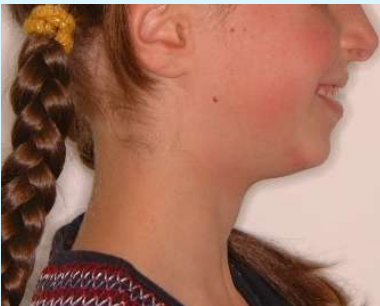After FKO 2013-08



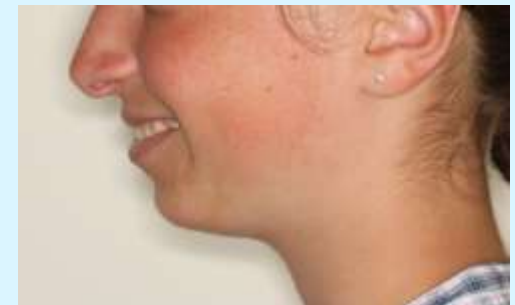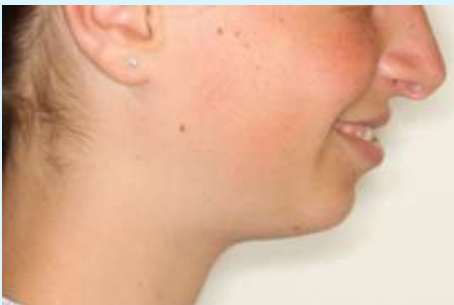Before FKO 2006-11



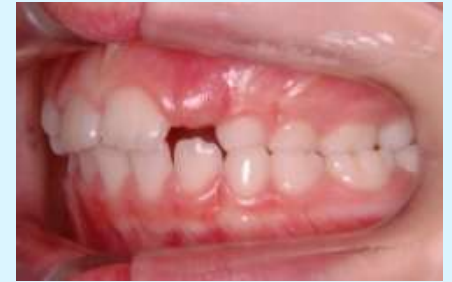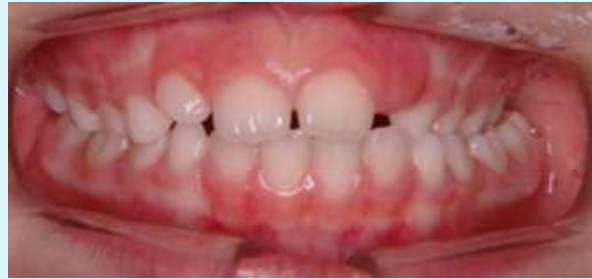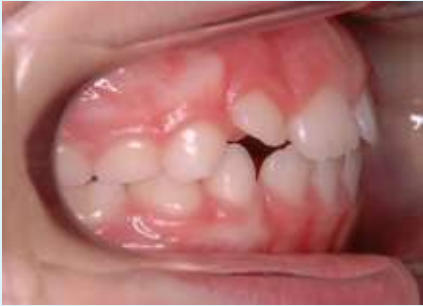After FKO 2008-09



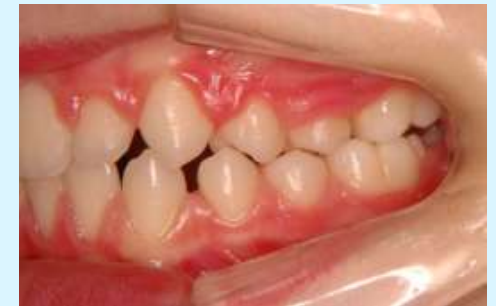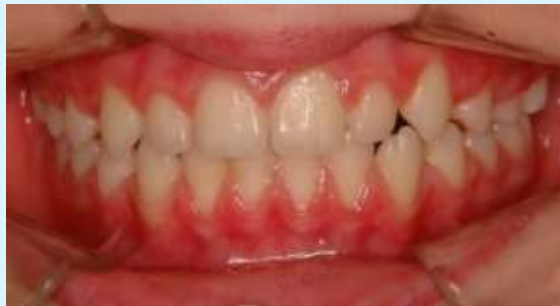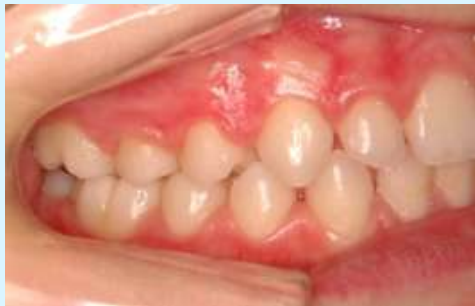After FKO 2013-08



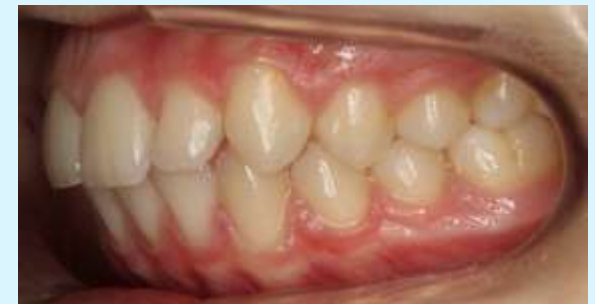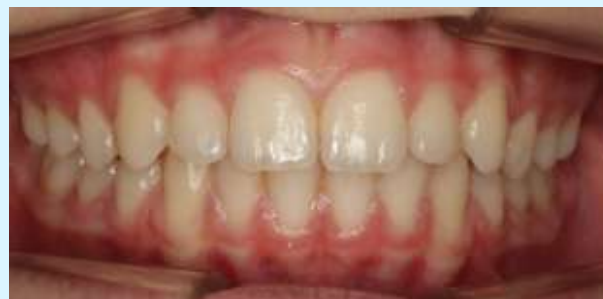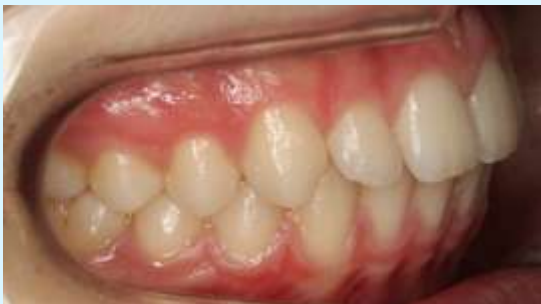Before FKO 2006-11



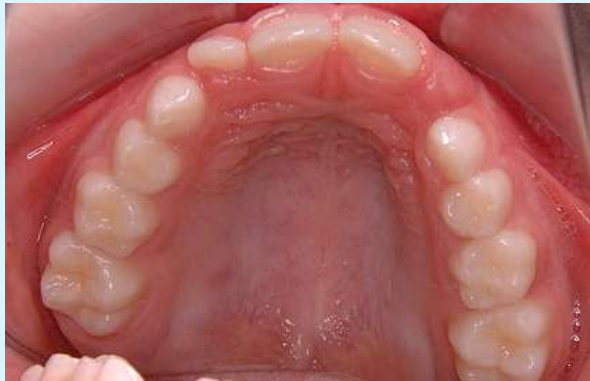After FKO 2008-09



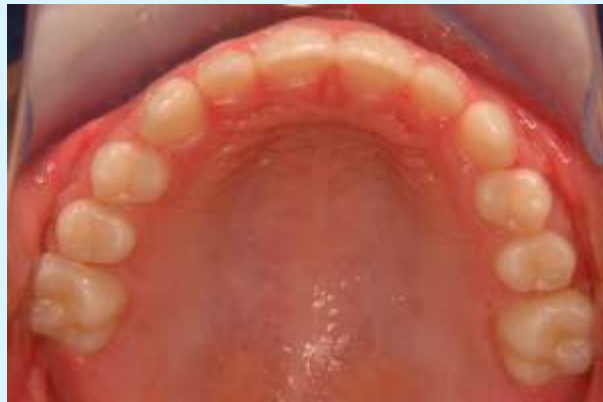After Fko 2012-04



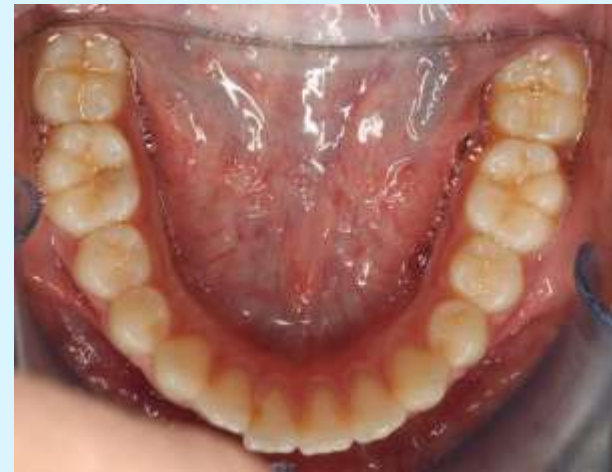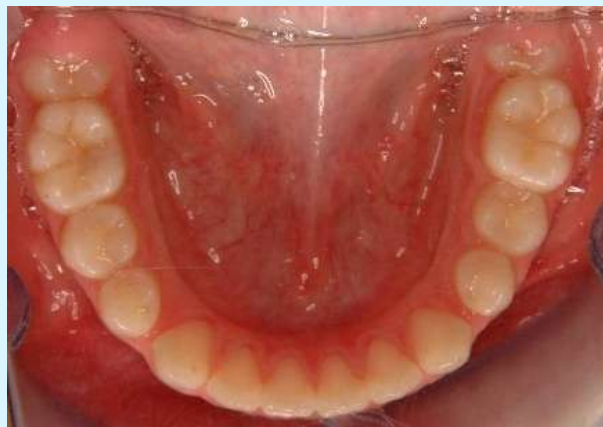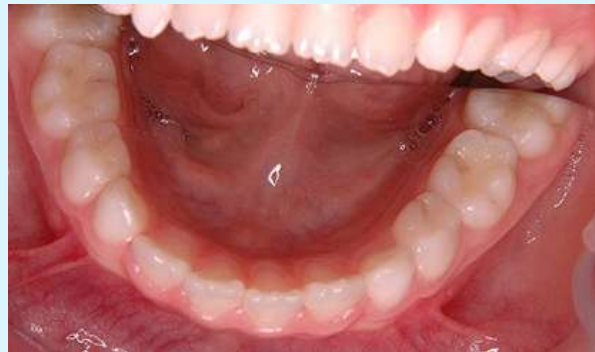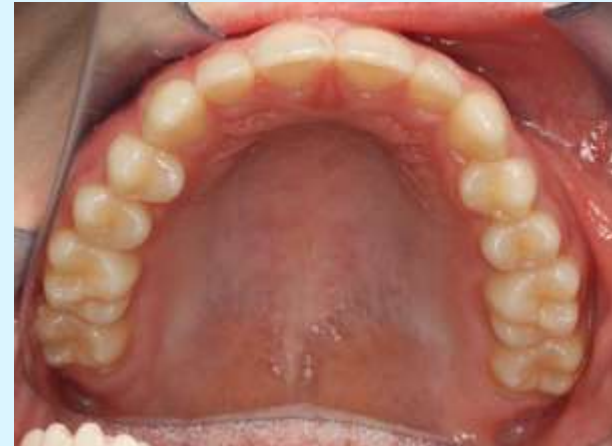Before FKO 2006-11



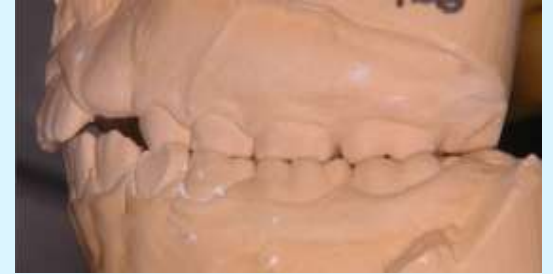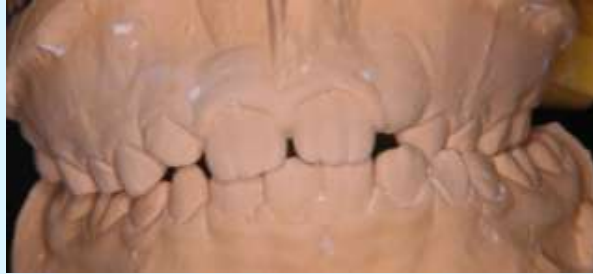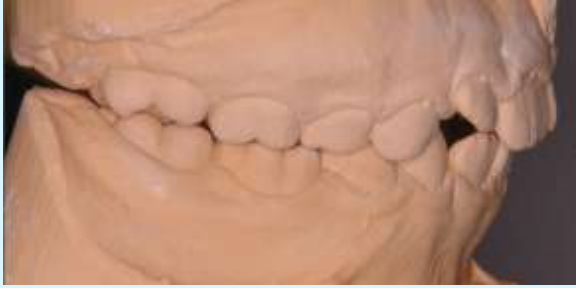After FKO 2008-09



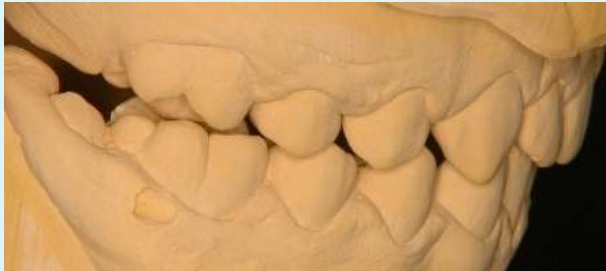After Fko 2012-04



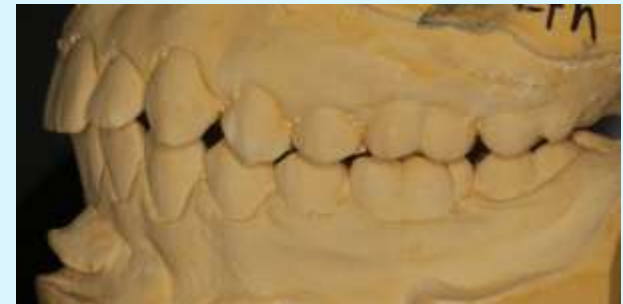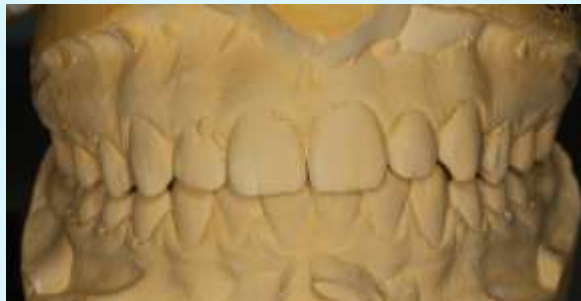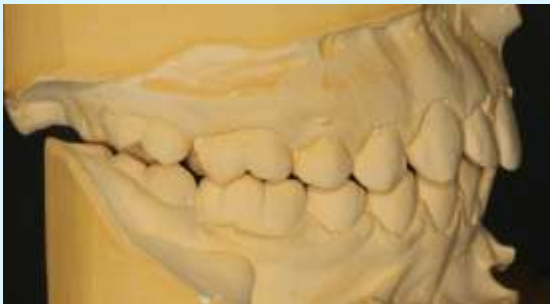Before FKO 2006-11



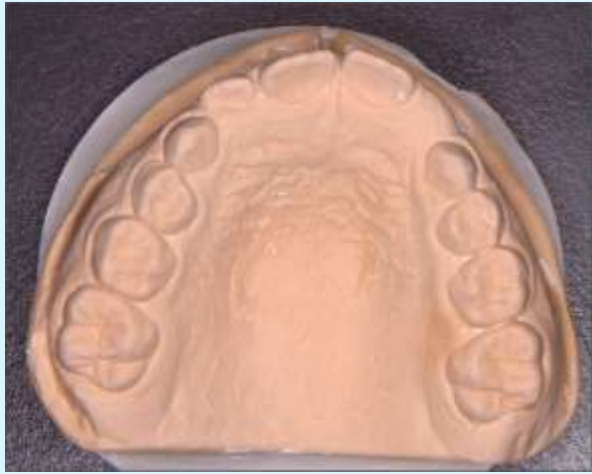After FKO 2008-09



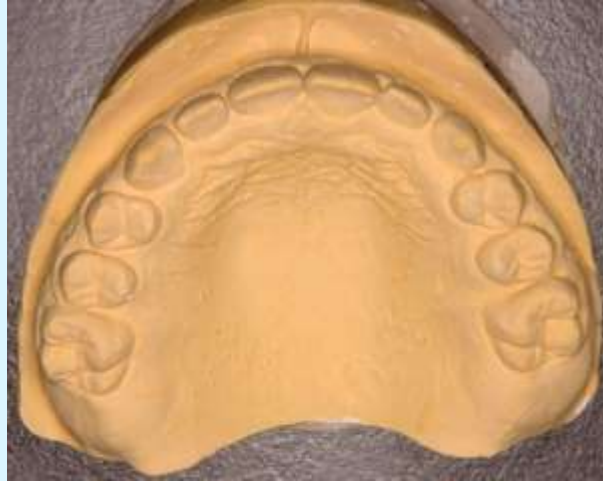After Fko 2012-04



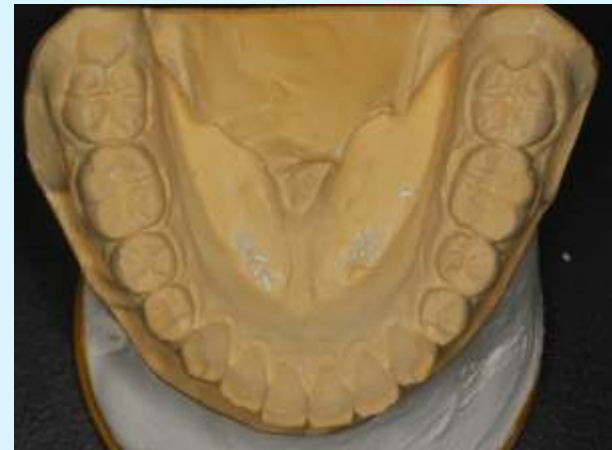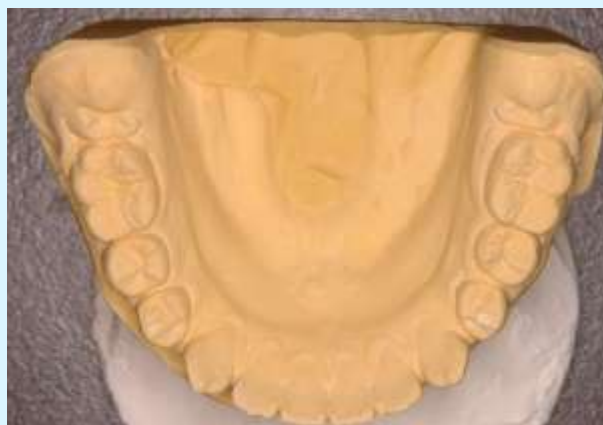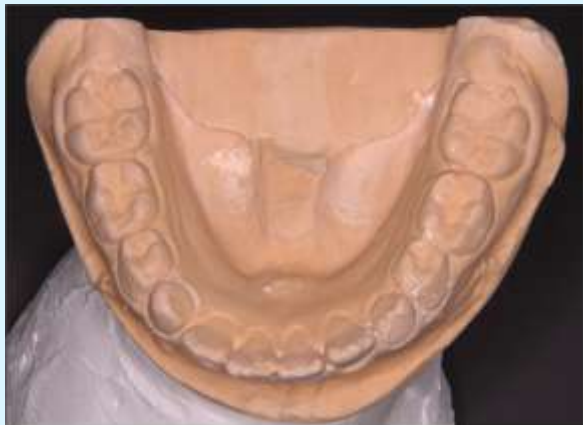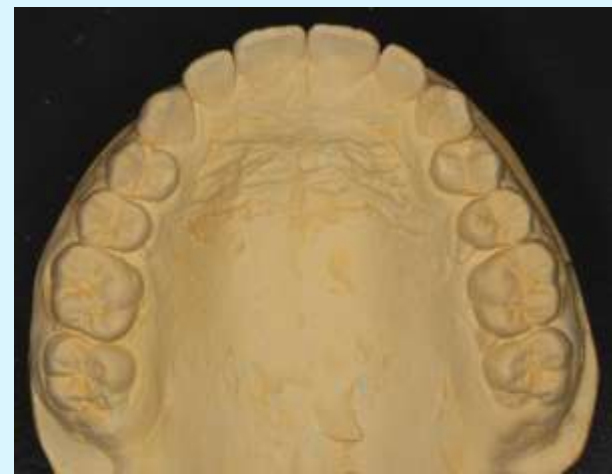Before FKO 2006-11



After FKO 2008-09



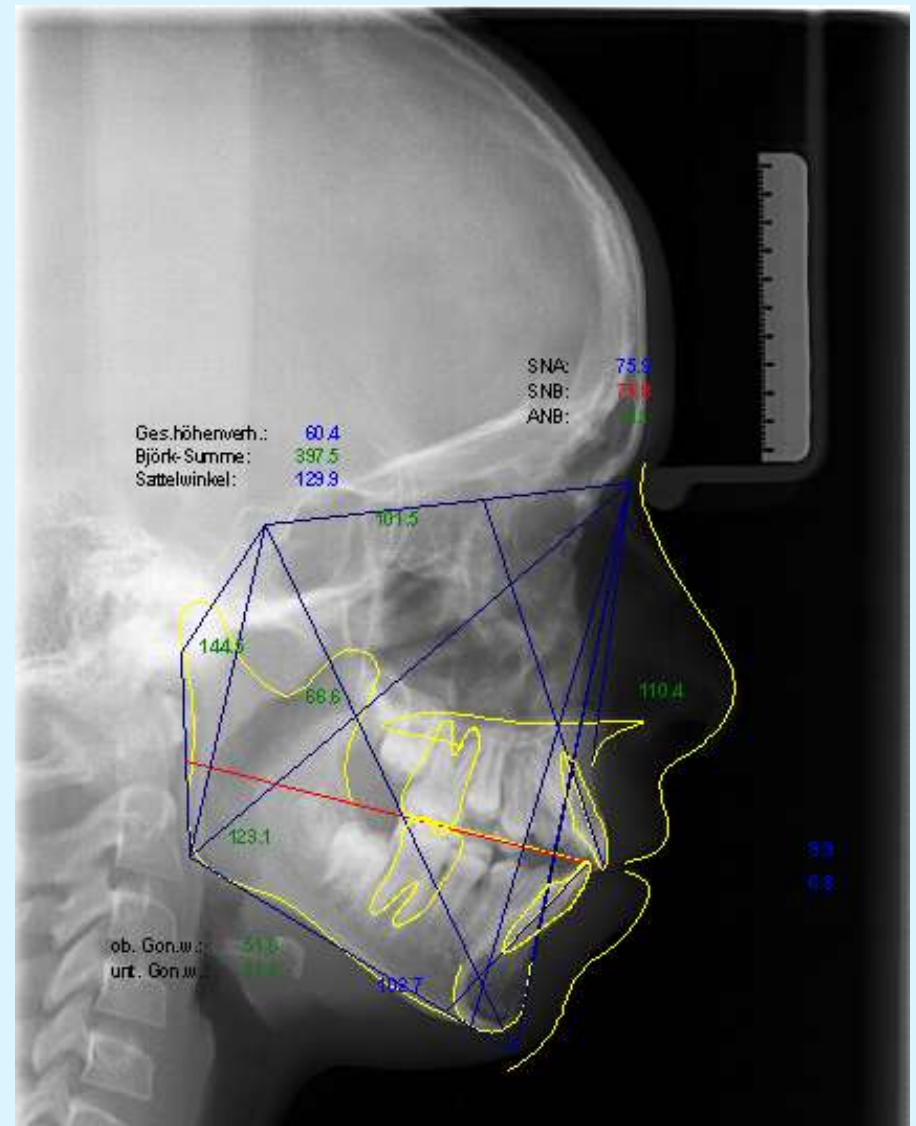
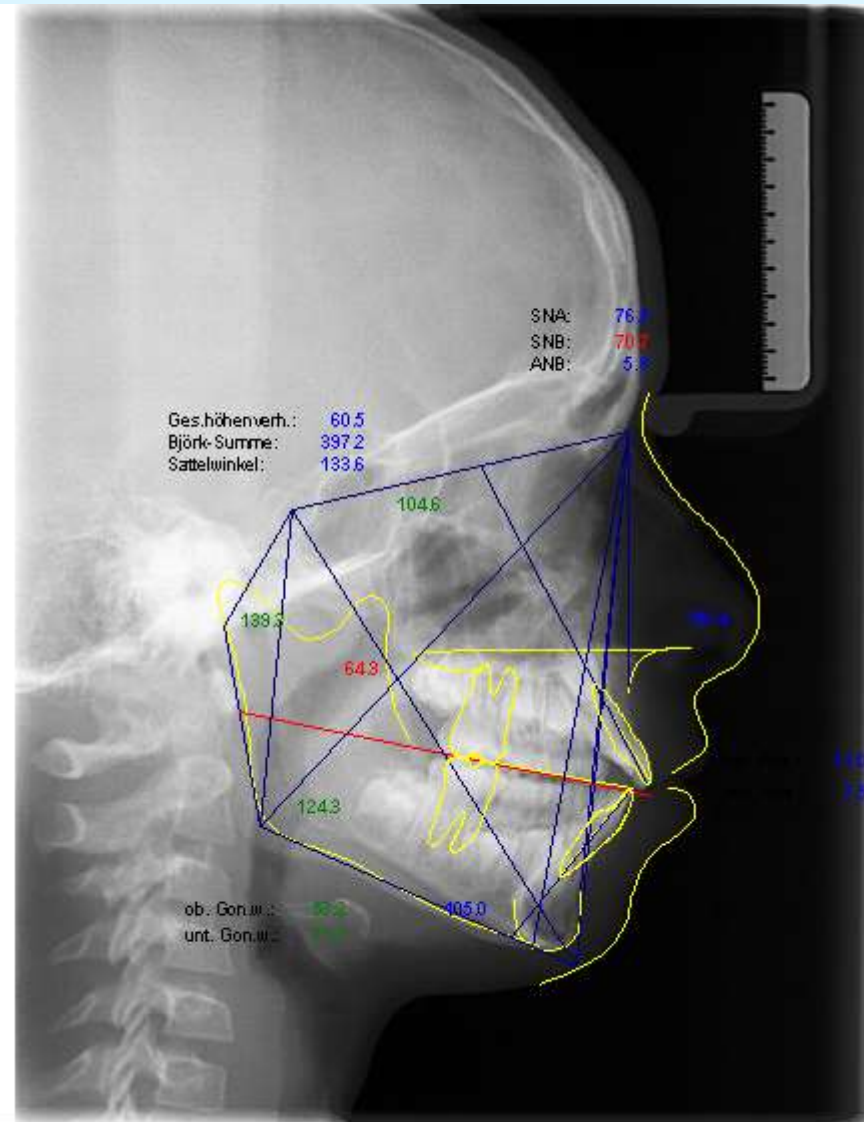
After Fko 2012-04



Jarabak Analyse

Before FKO 2006-11

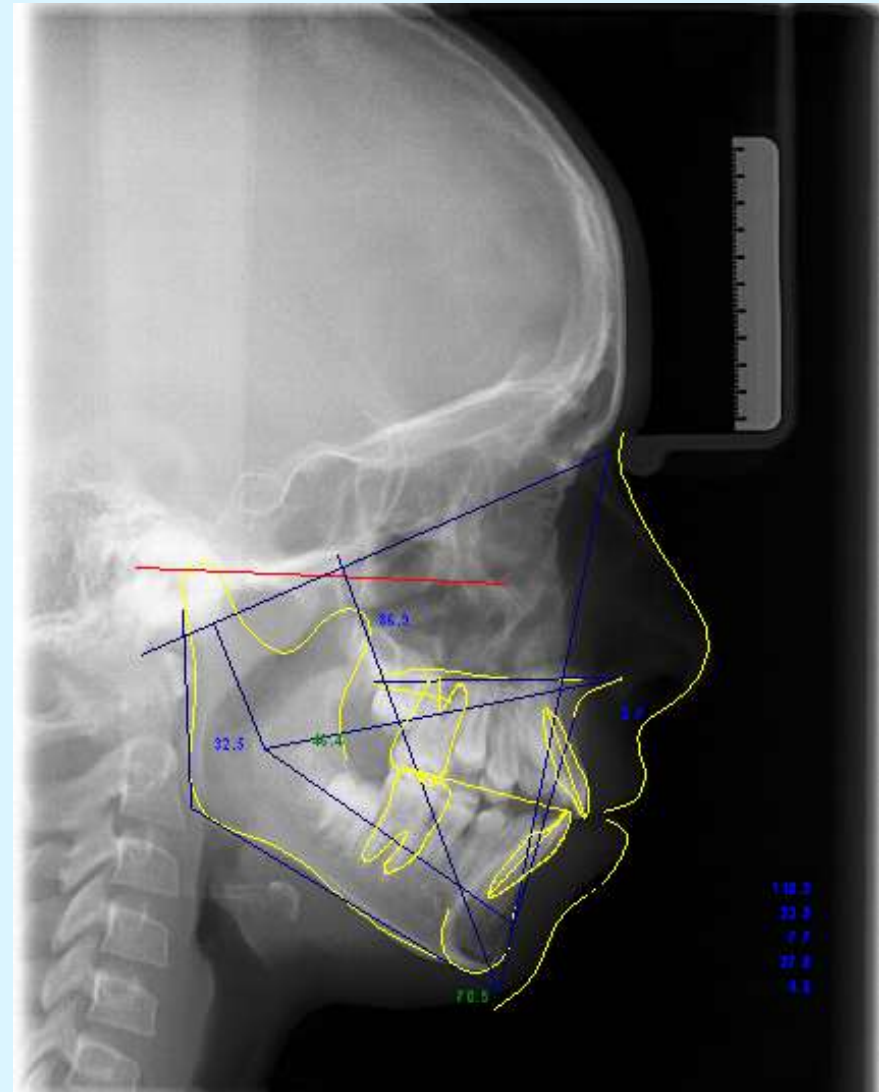
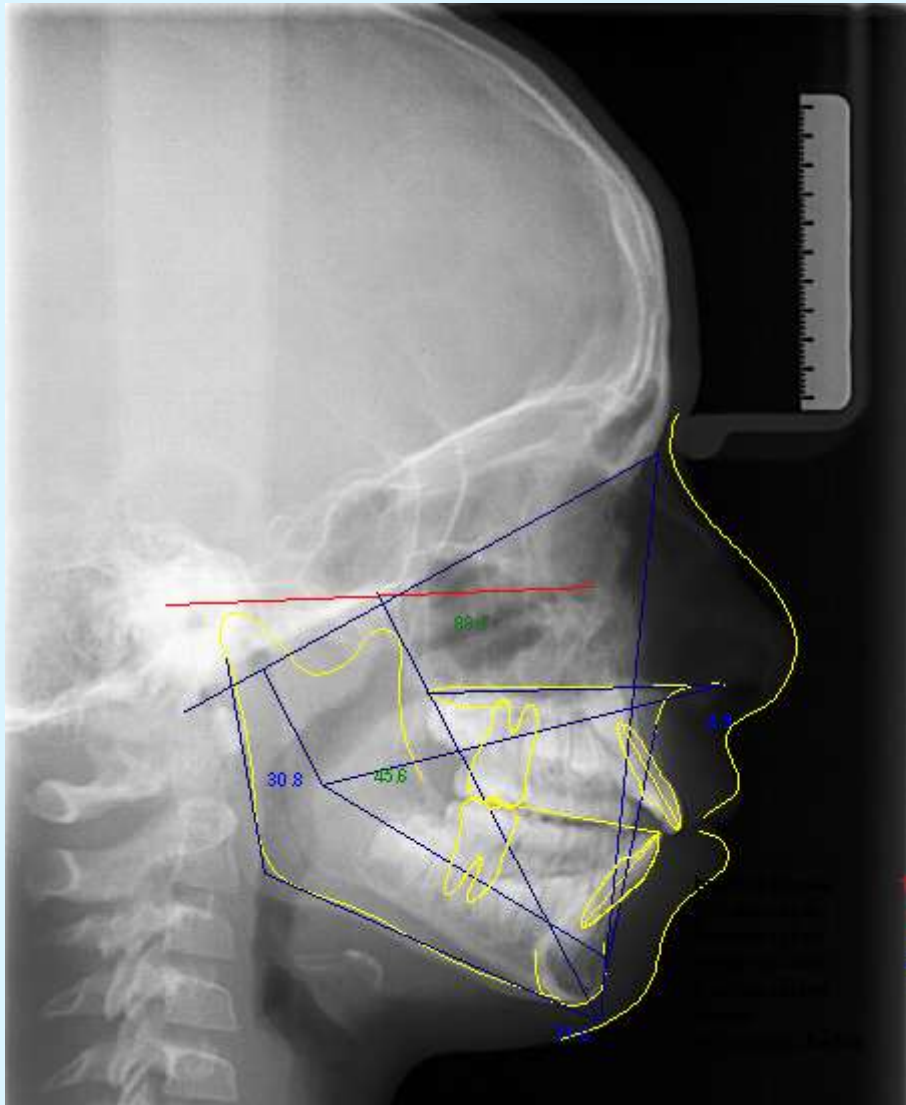
After FKO 2008-09

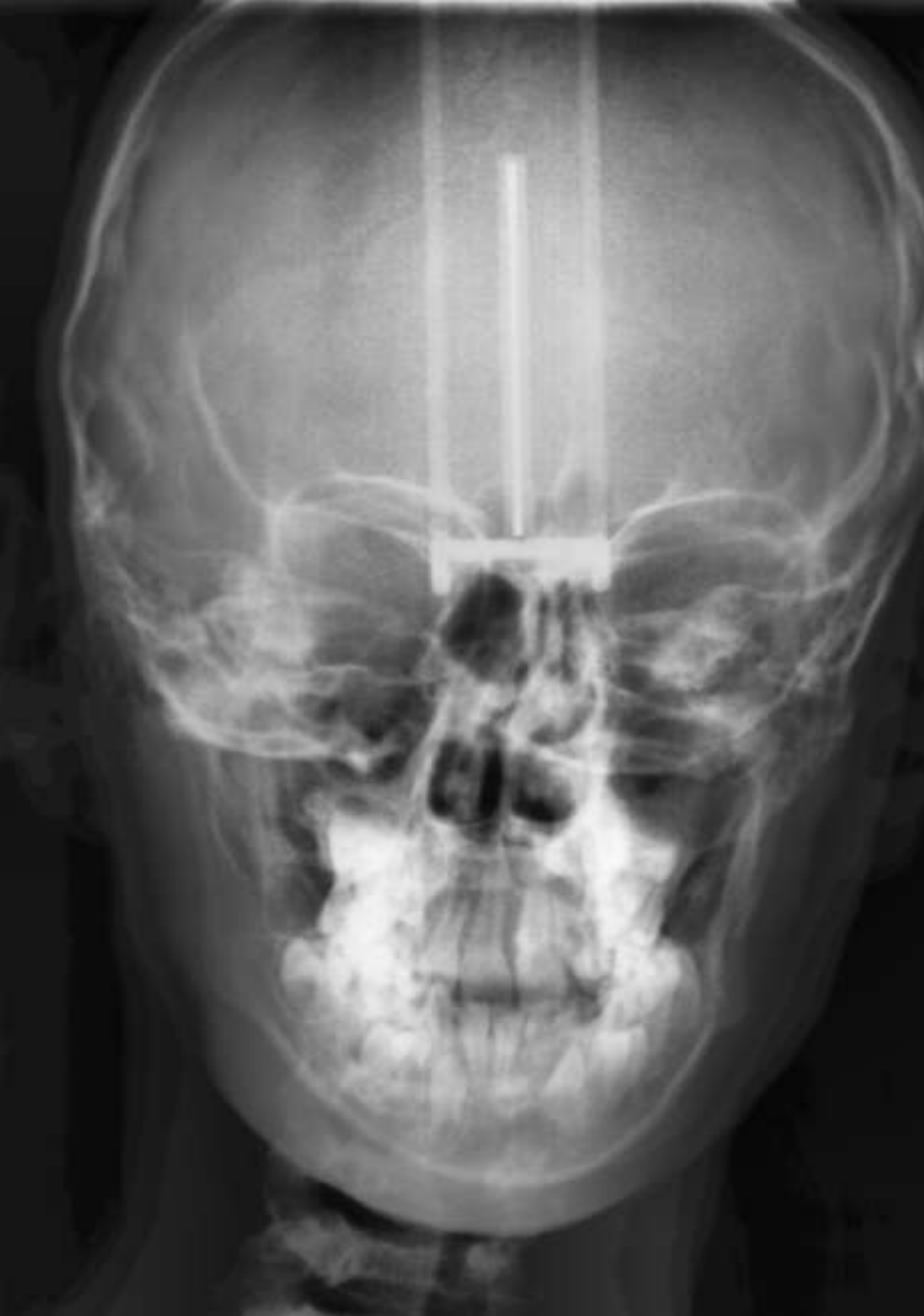

Ricketts Analyse

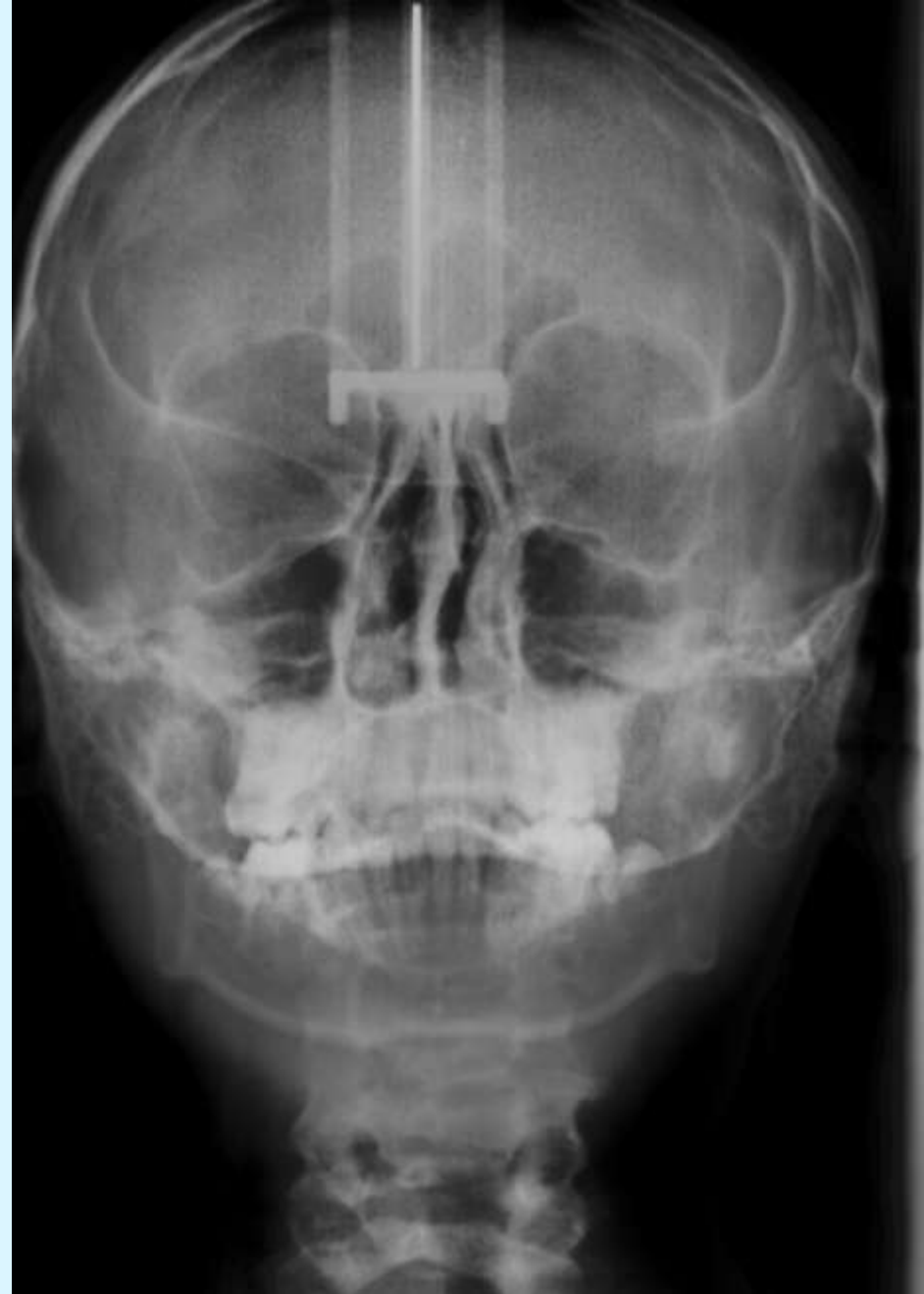Before FKO 2006-11

After FKO 2008-09

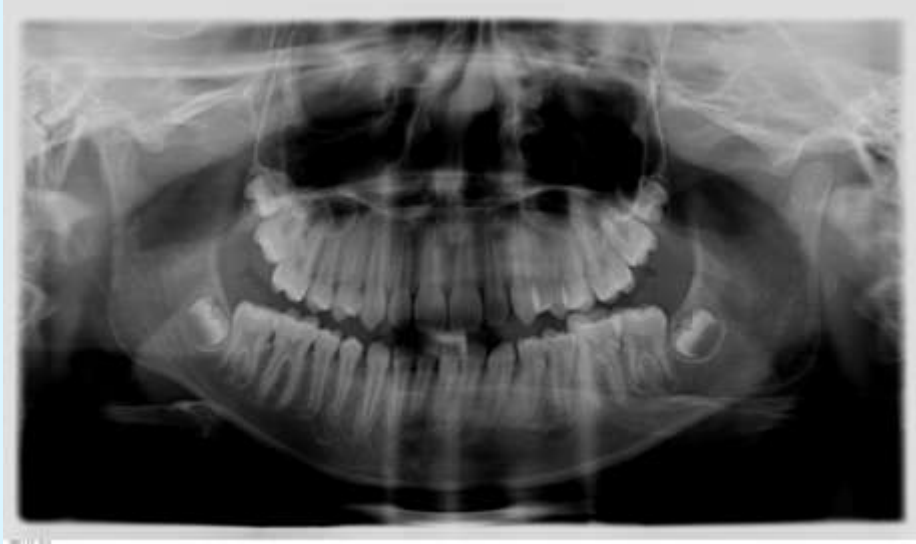



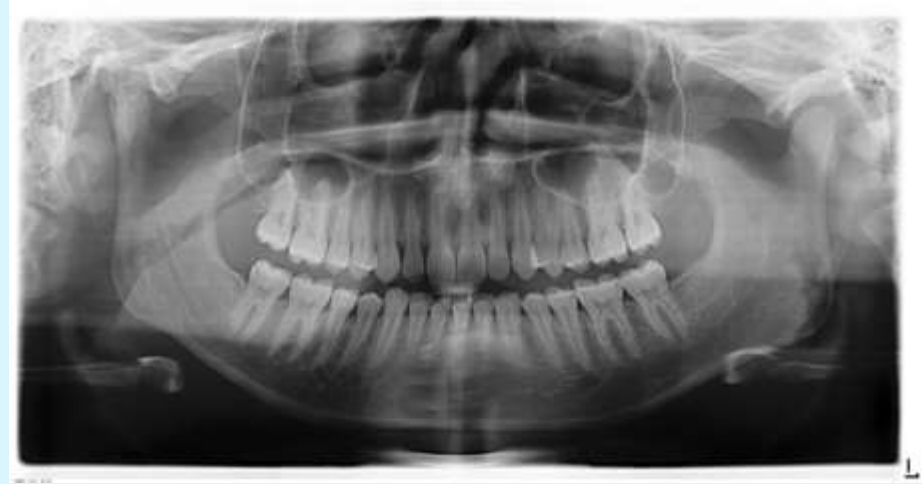2006-11 before FKO → crossbite left



2009-08 after FKO



2009-08



2015-04