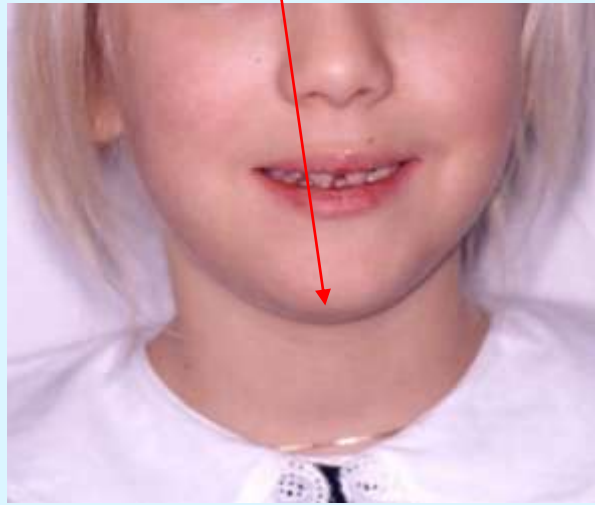
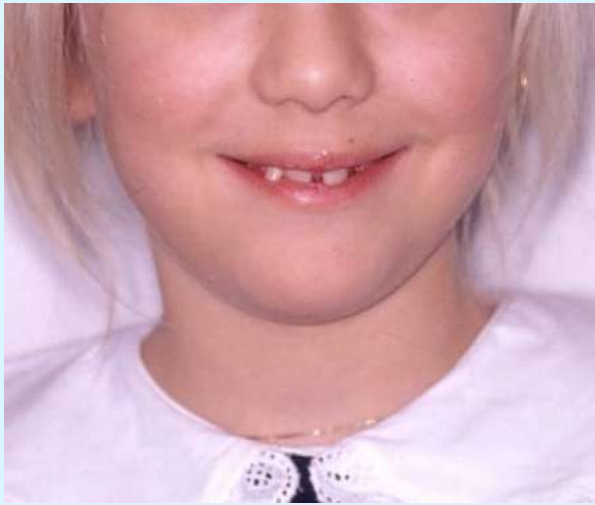
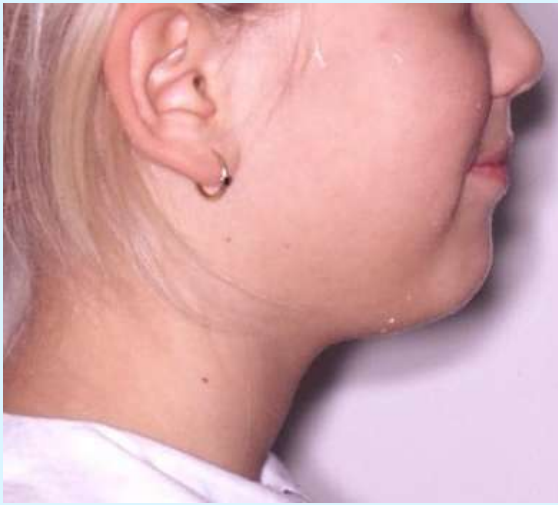
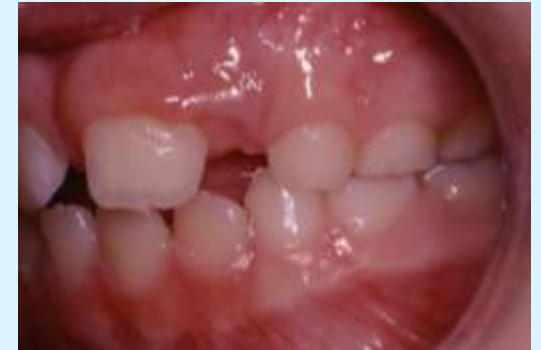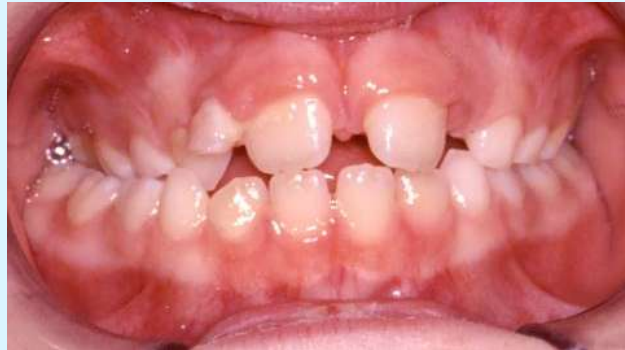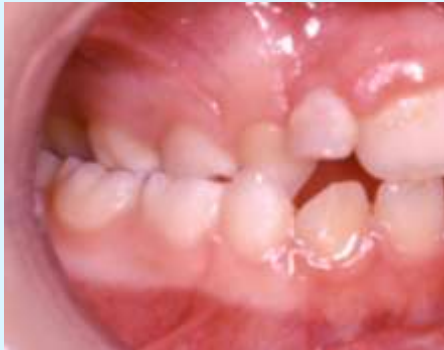- Diagnose:**
- asym. Kl.II/1-2 und dentoalv. Leicht offener Biss
  - Kreuzbiss rechts 6- III/ m. mandib.  
Mittellinie-Verschiebung nach rechts (leichte  
Gesichts Asym. Rechts)
  - OK-Bogen rechts schmaler als links  
( transv.max. Asym.)
  - OK-Raummangel
  - MOH und Schnarchen
  - chron. Angina

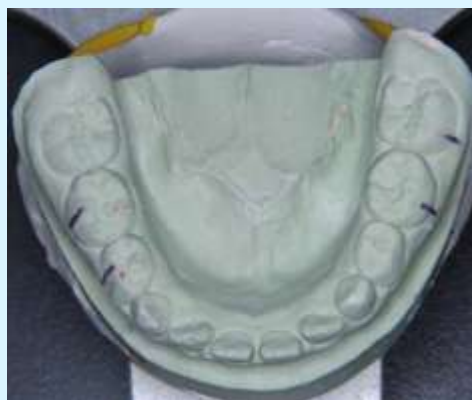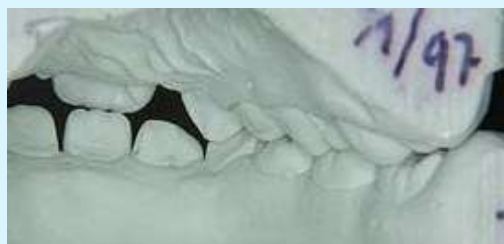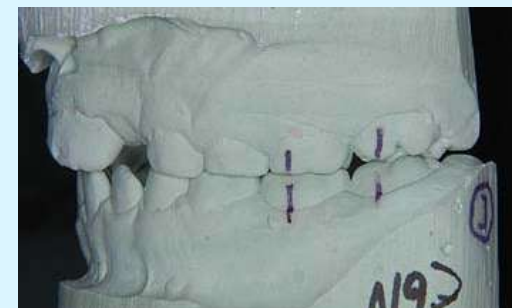
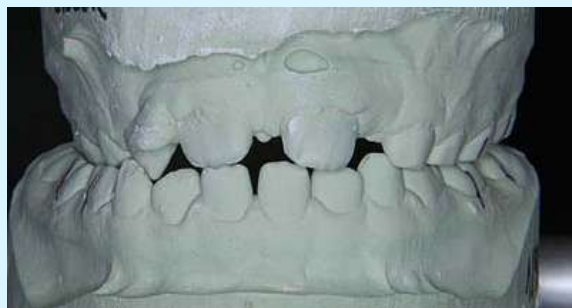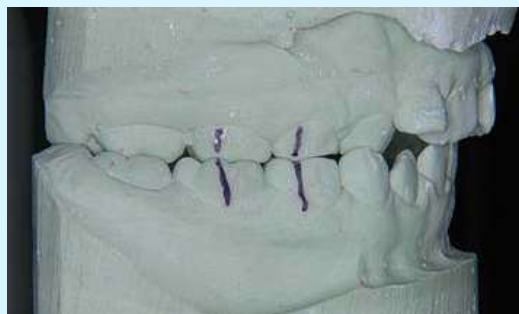Before FKO 1997-01 →note the chin-deviation to right



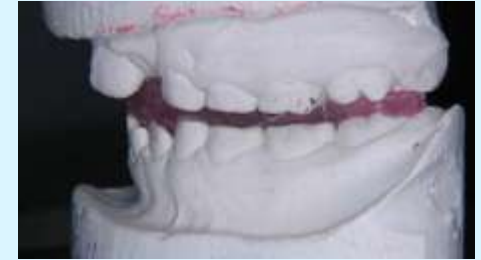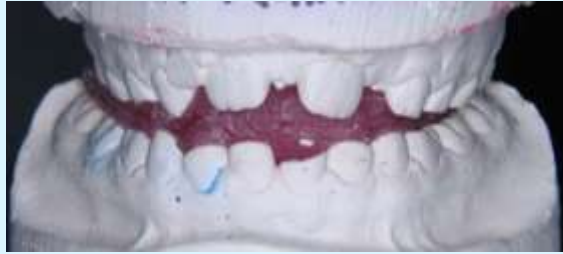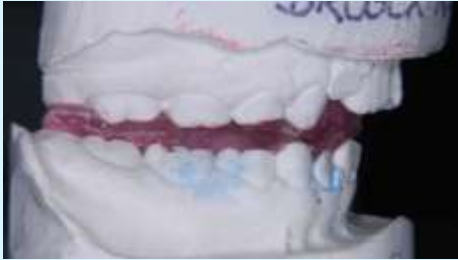Before FKO 1997-01



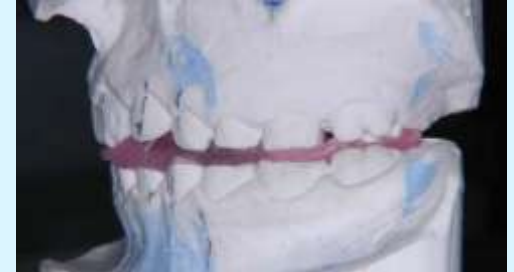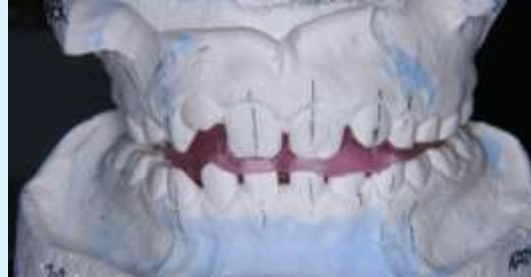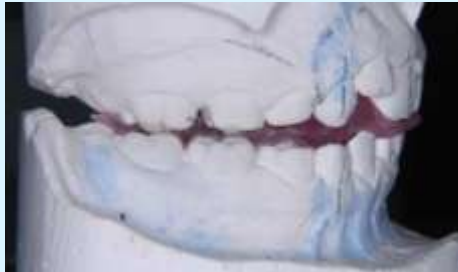Before FKO 1997-01



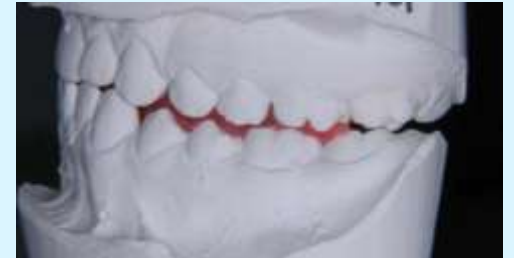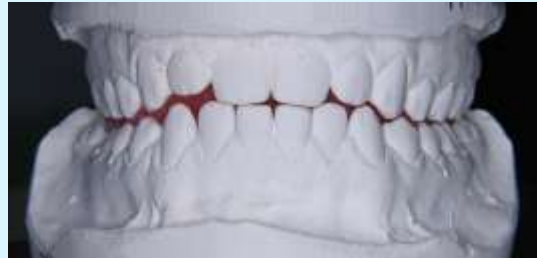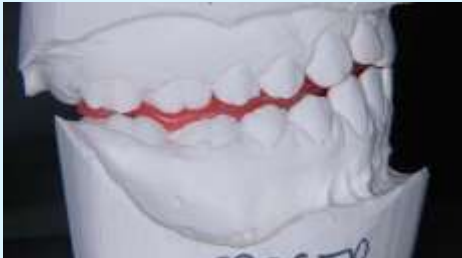## Konstruktionsbiss 1997-01



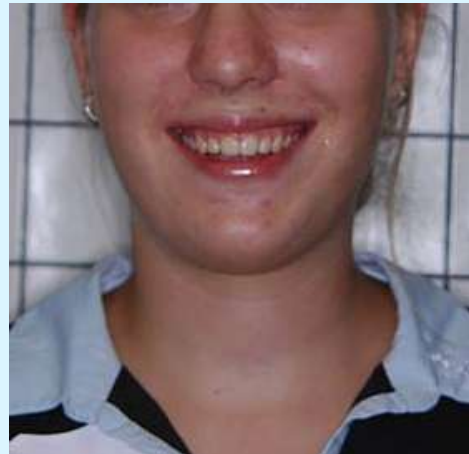## Konstruktionsbiss 1998-10



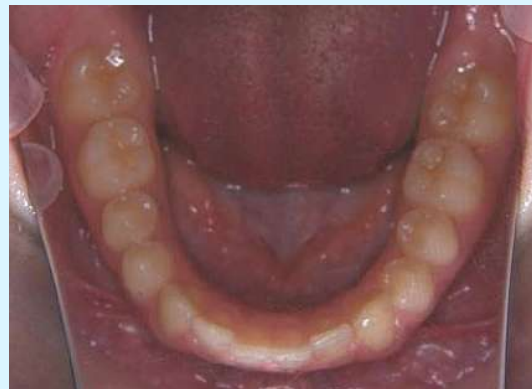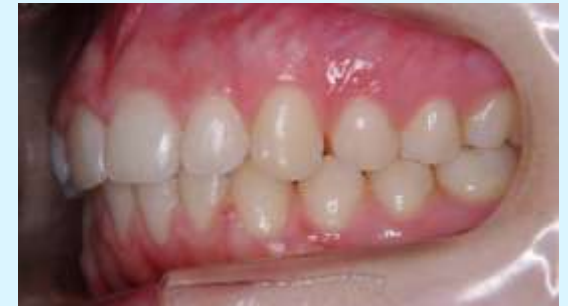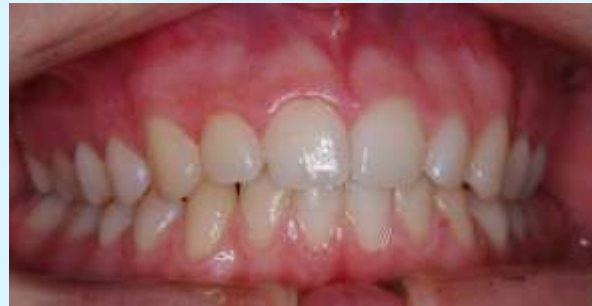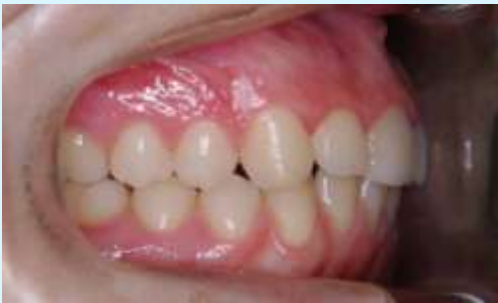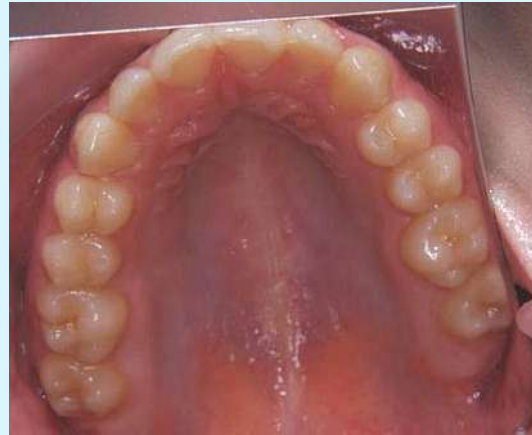
## Konstruktionsbiss 2003-09



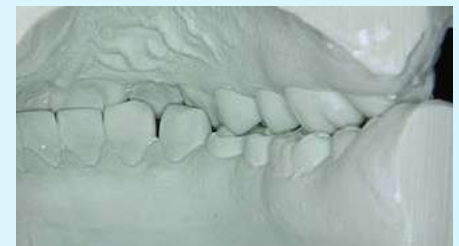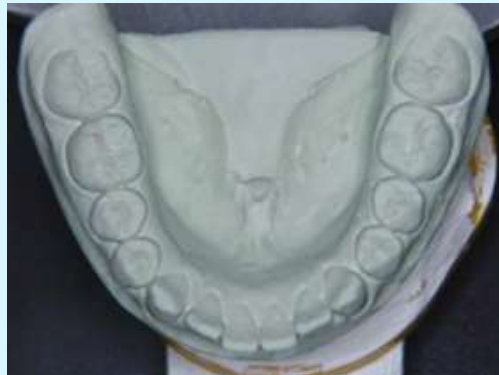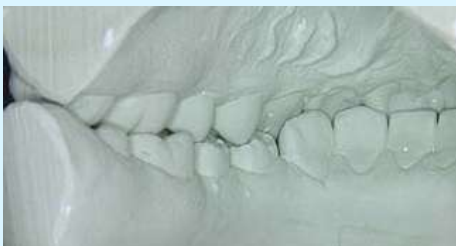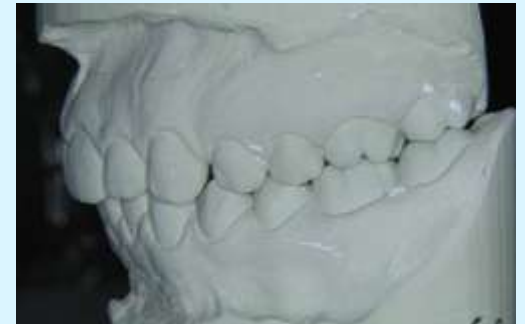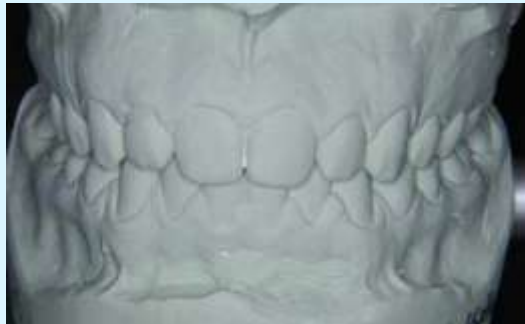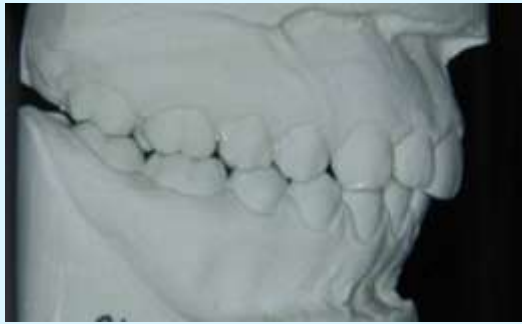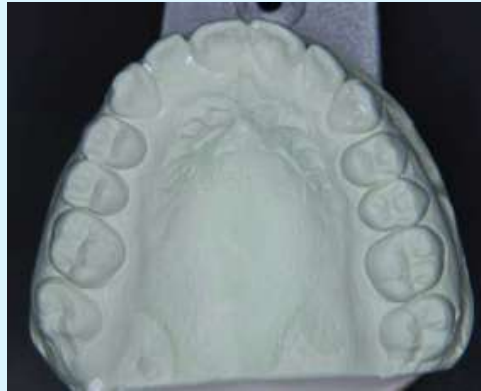After FKO 2005-08



After FKO 2005-08

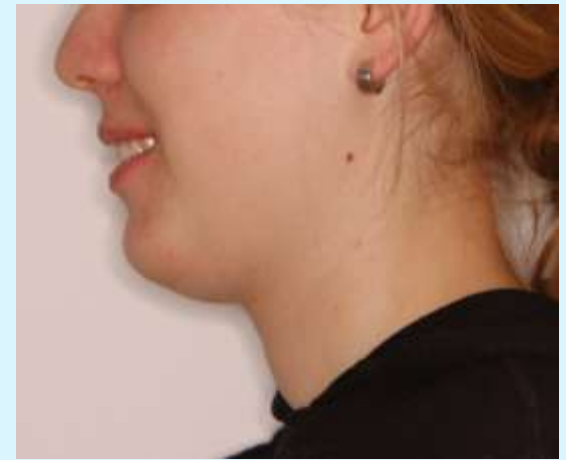
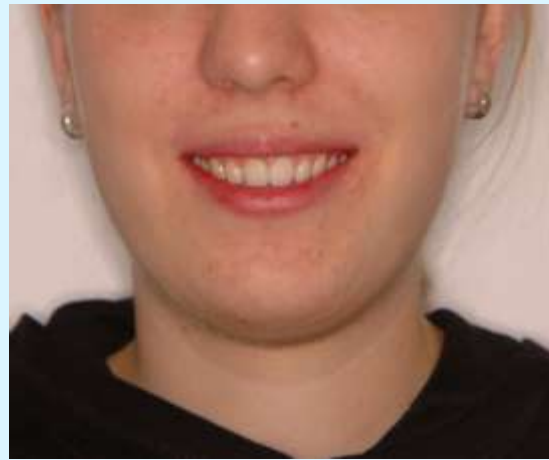
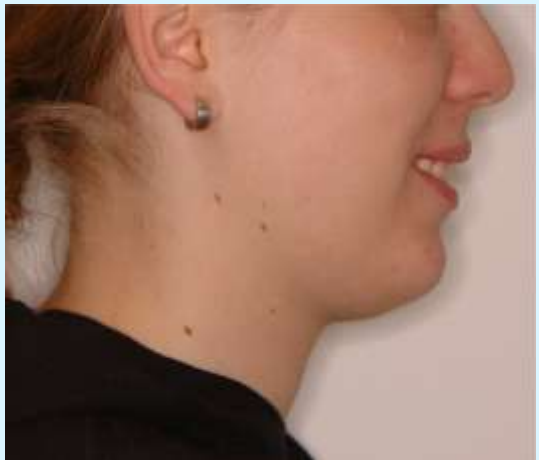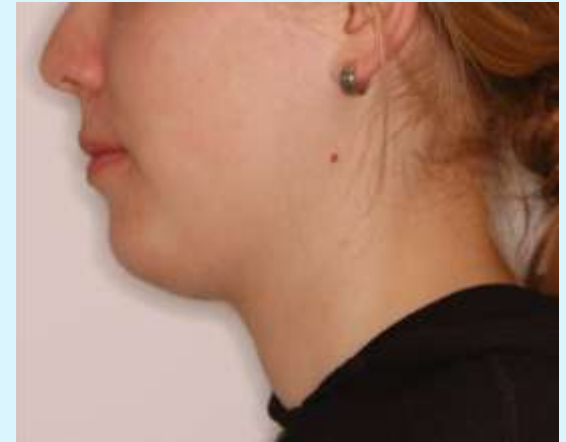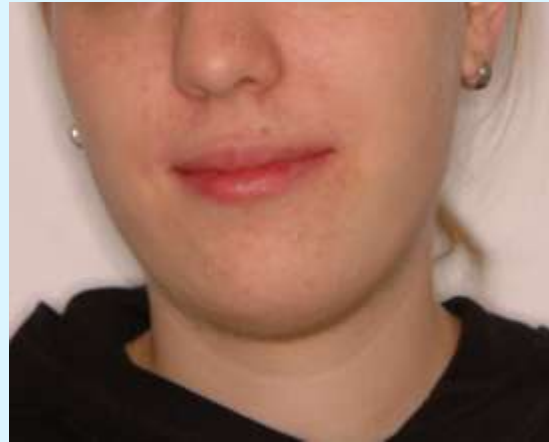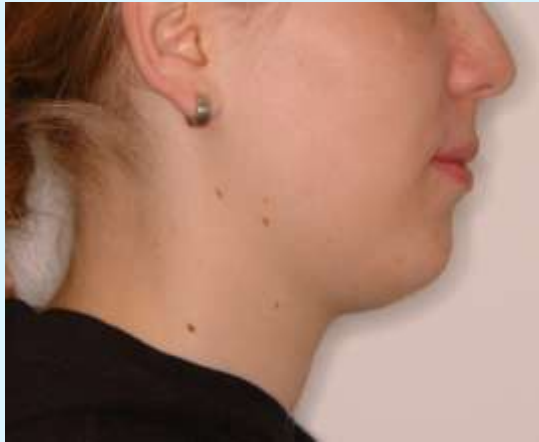After FKO 2005-08

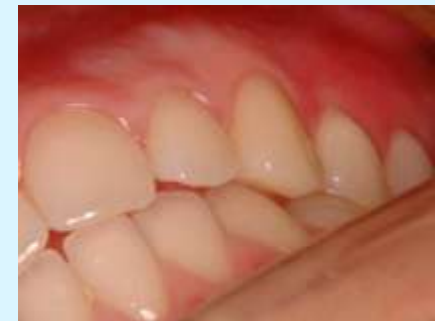
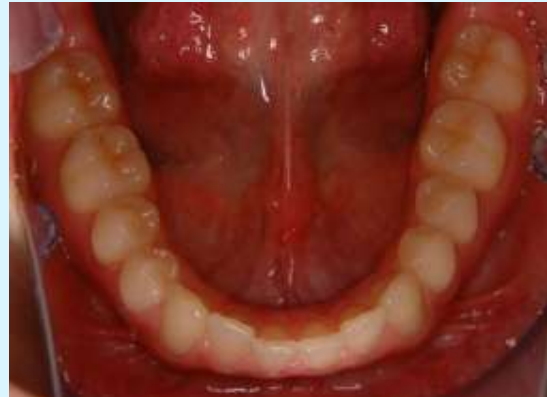
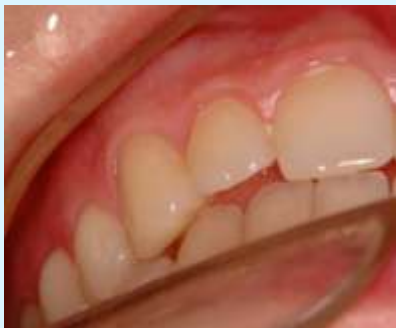
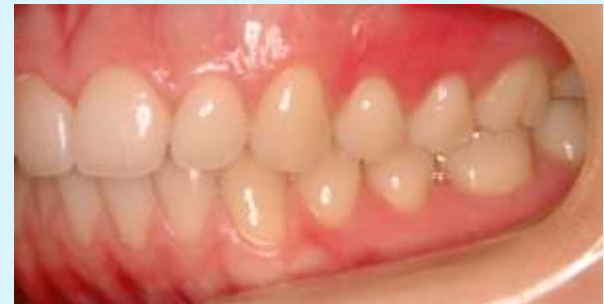
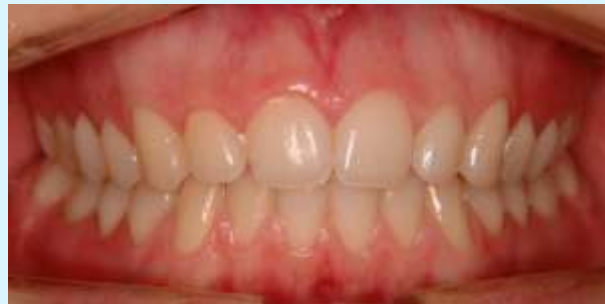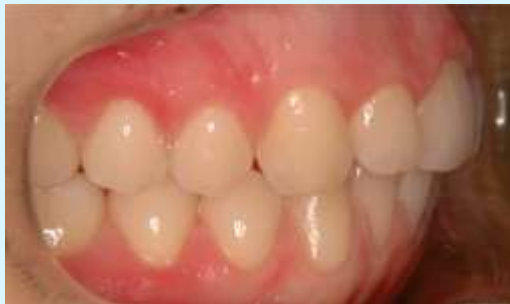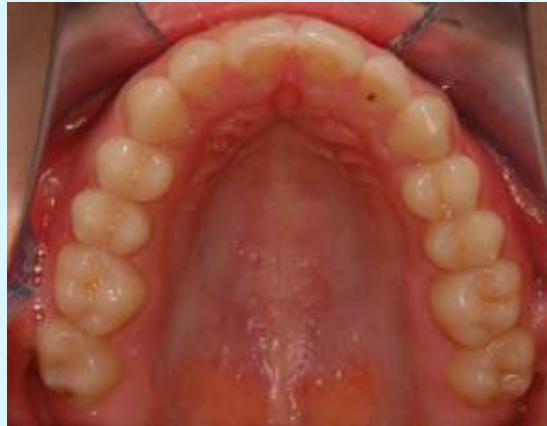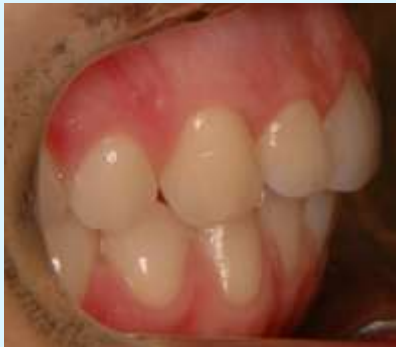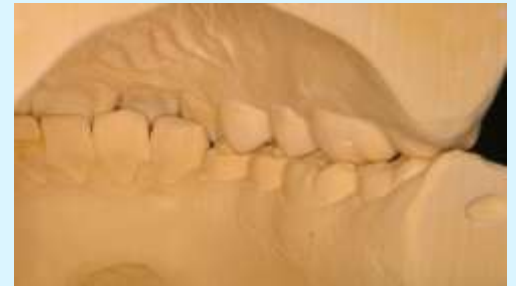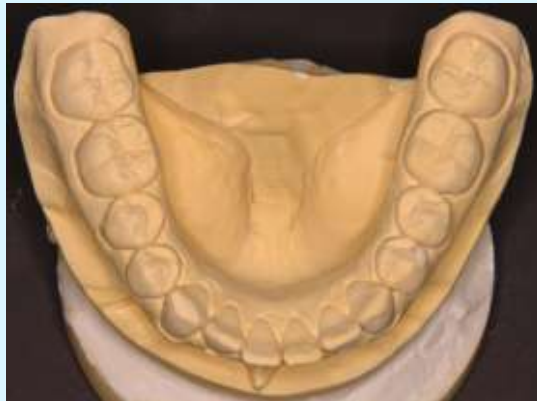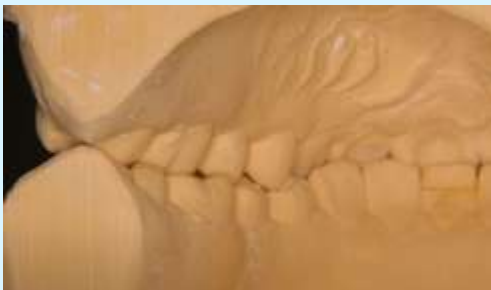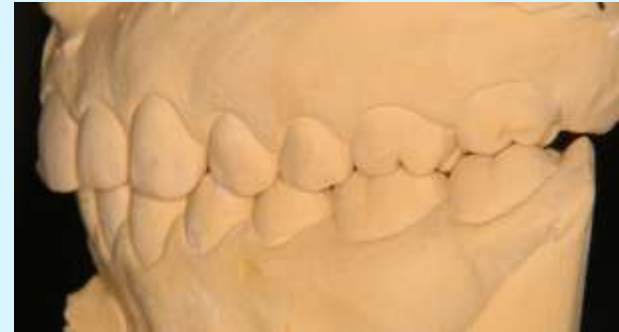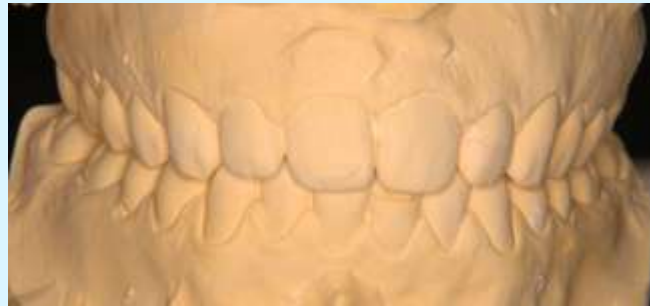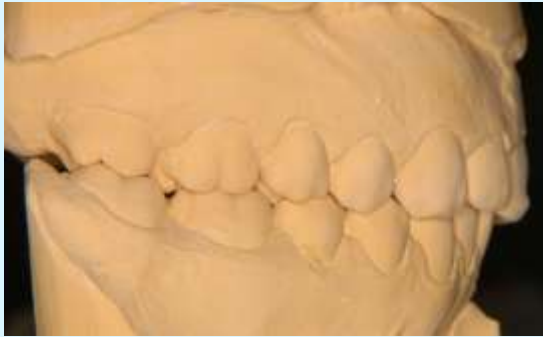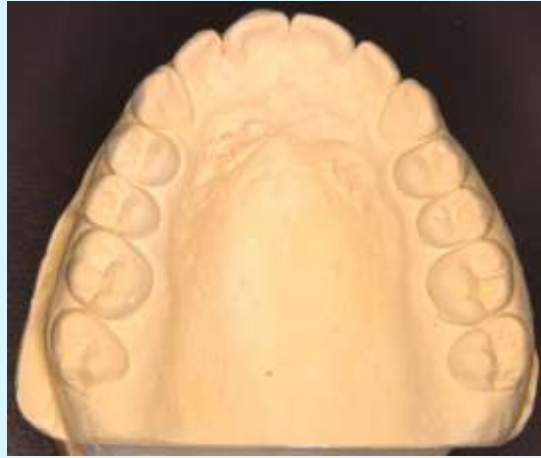After KFO 2010-03



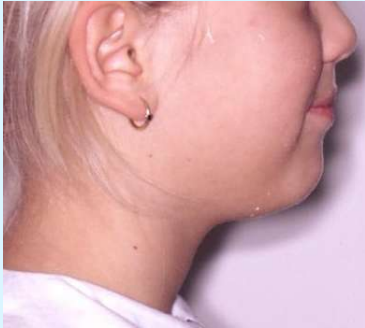After KFO 2010-03



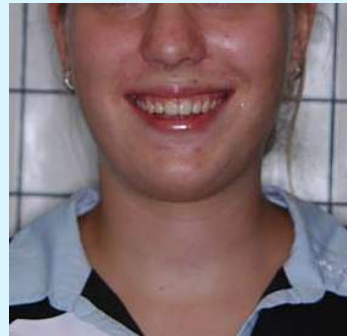After KFO 2010-03



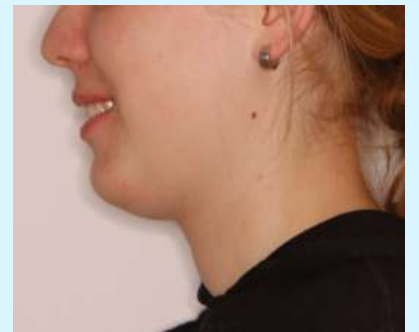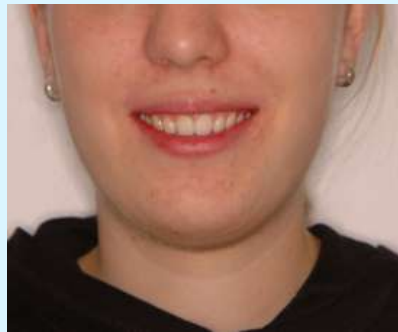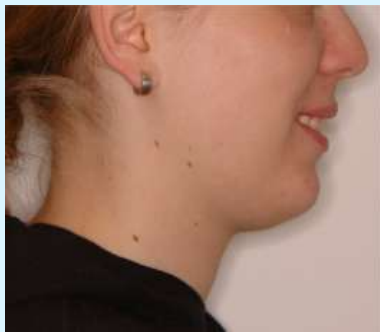Before FKO 1997-01



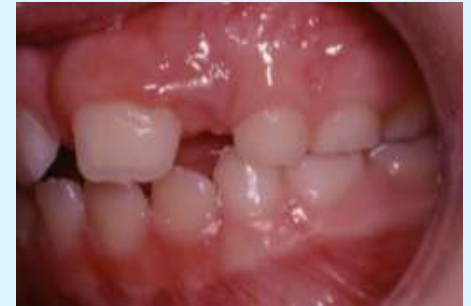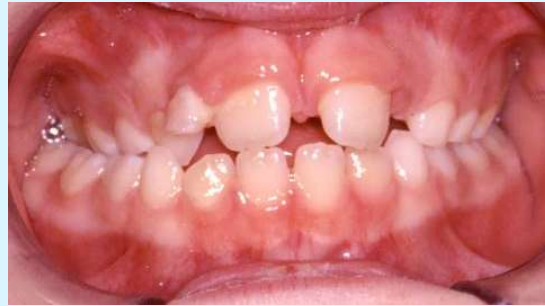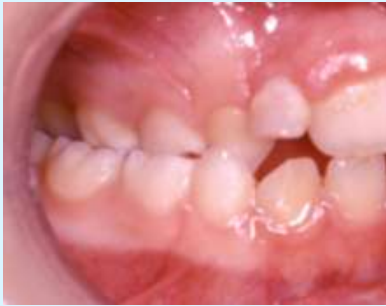After FKO 2005-08



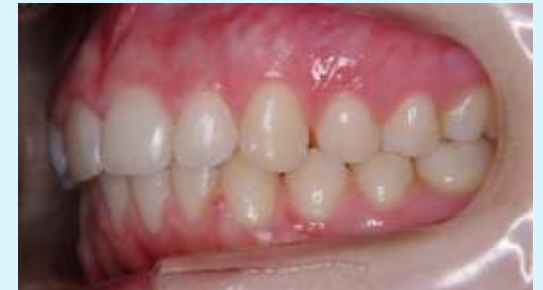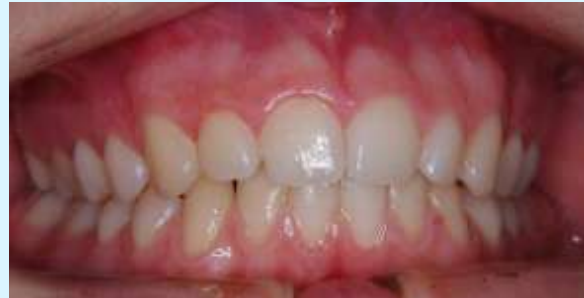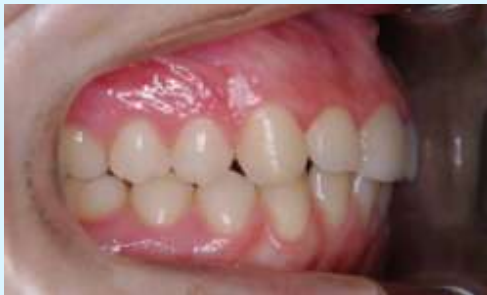After KFO 2010-03



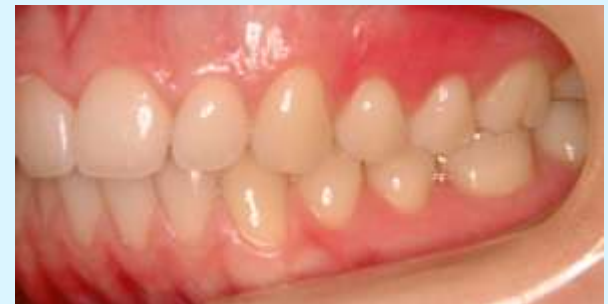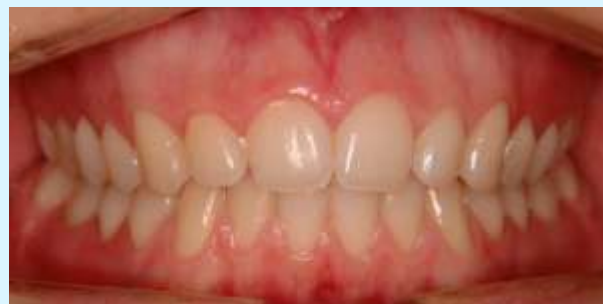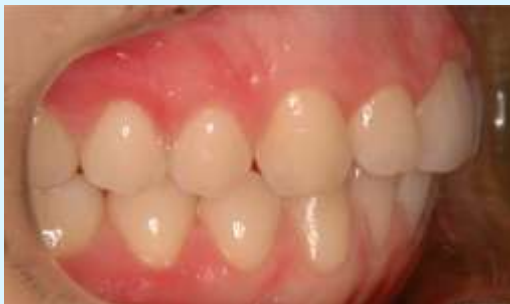Before FKO 1997-01



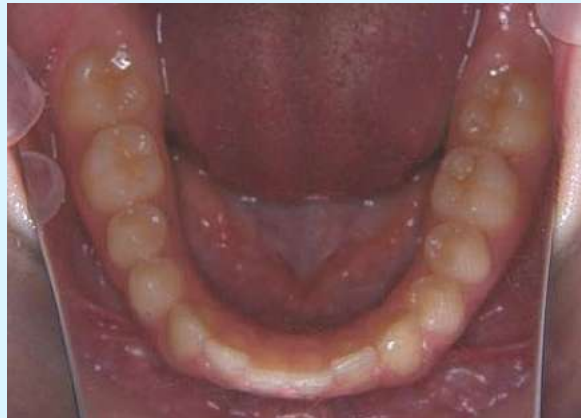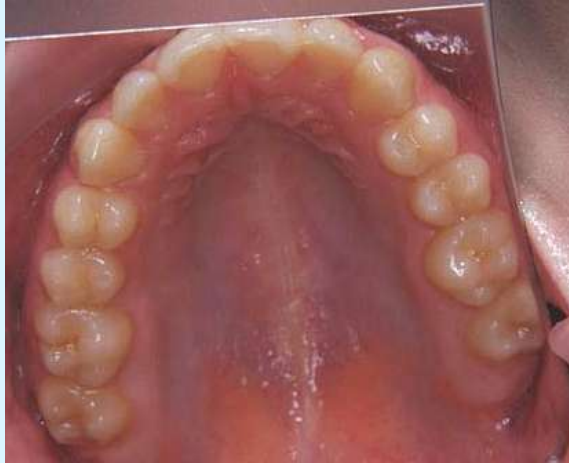After FKO 2005-08



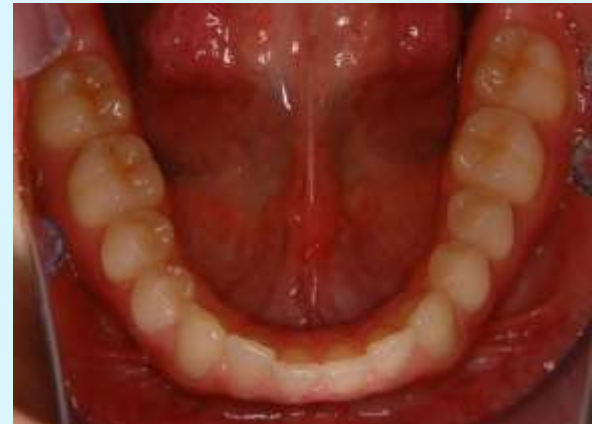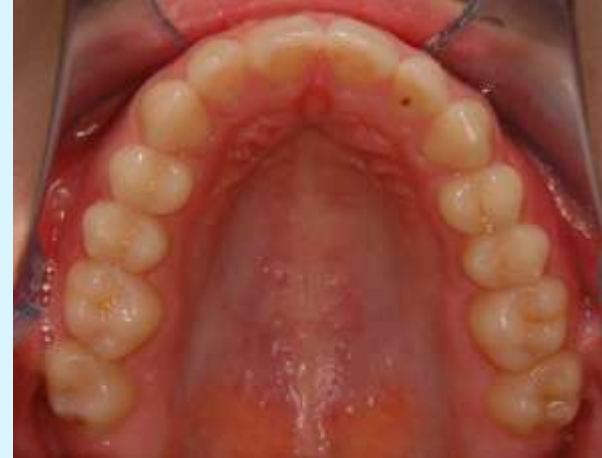After KFO 2010-03



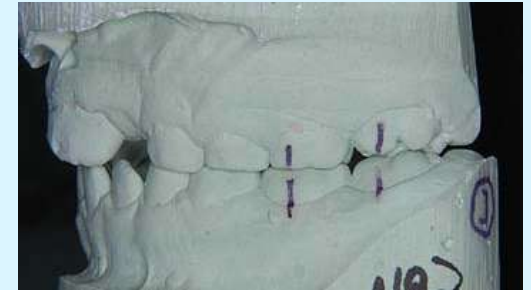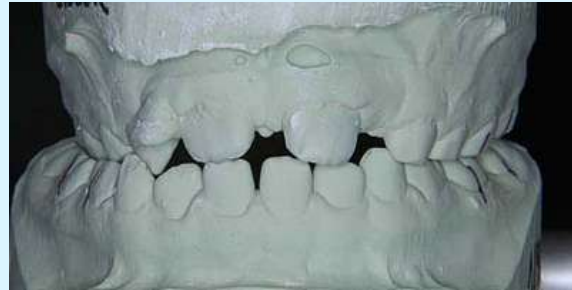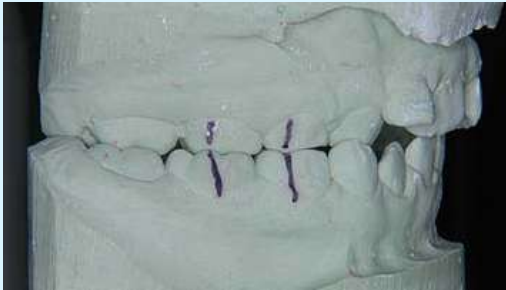After FKO 2005-08



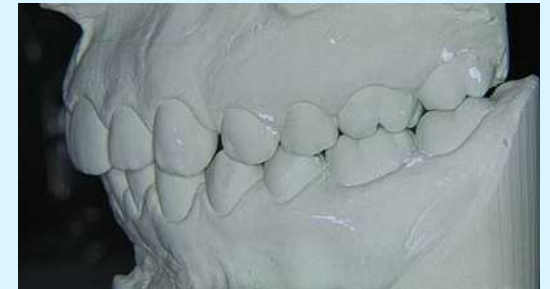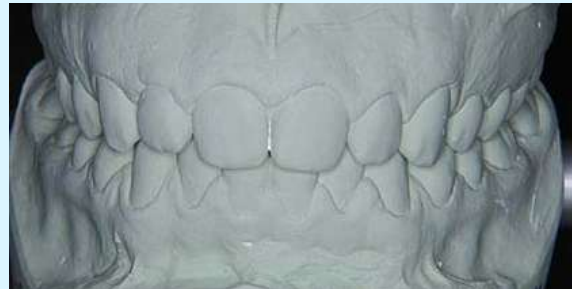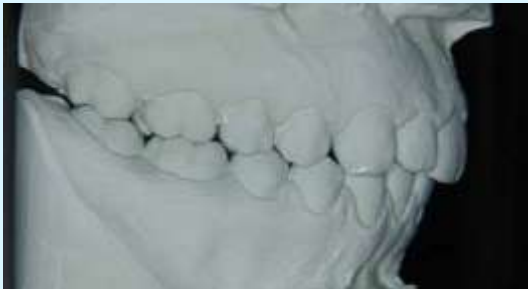After KFO 2010-03



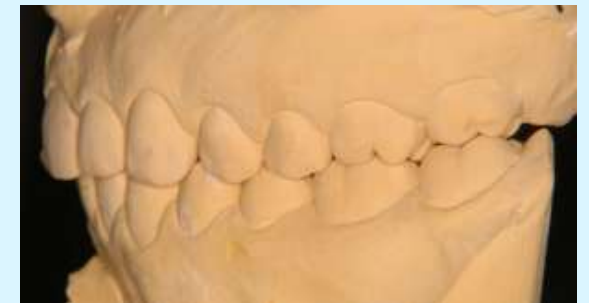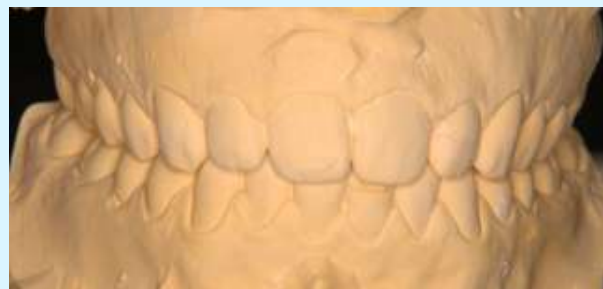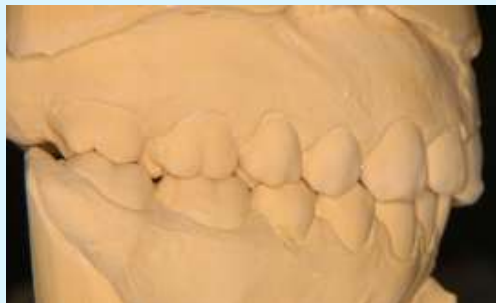Before FKO 1997-01



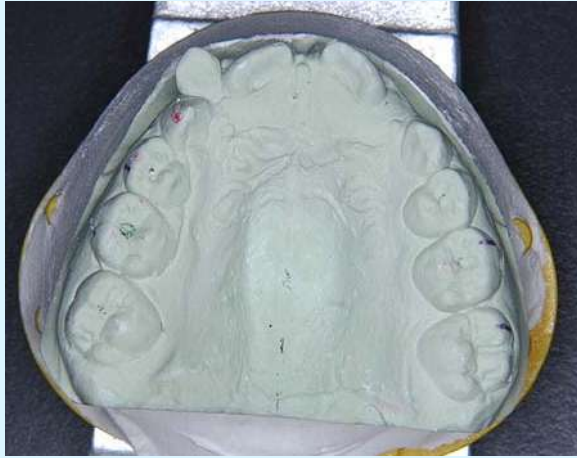After FKO 2005-08



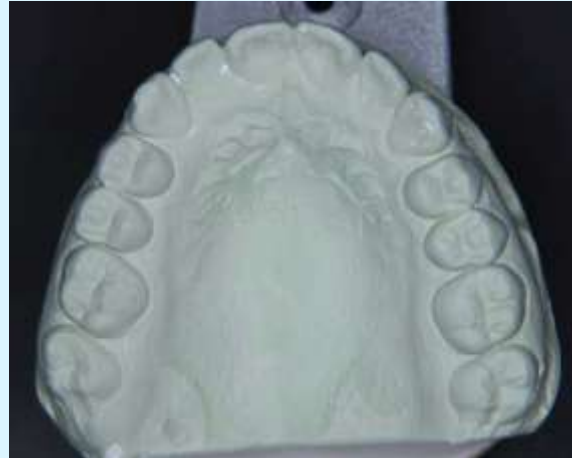After KFO 2010-03



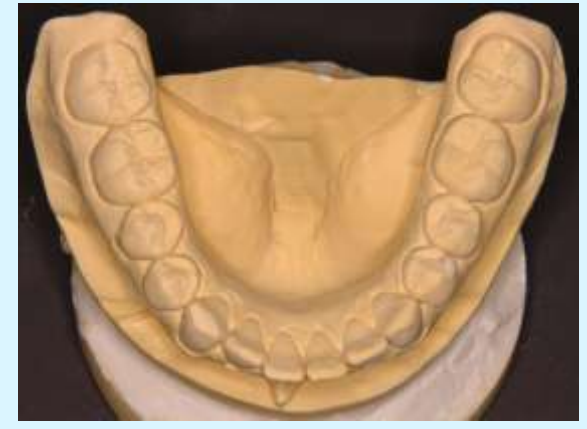
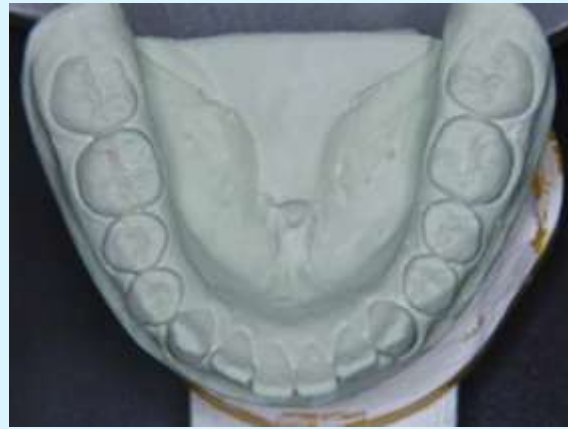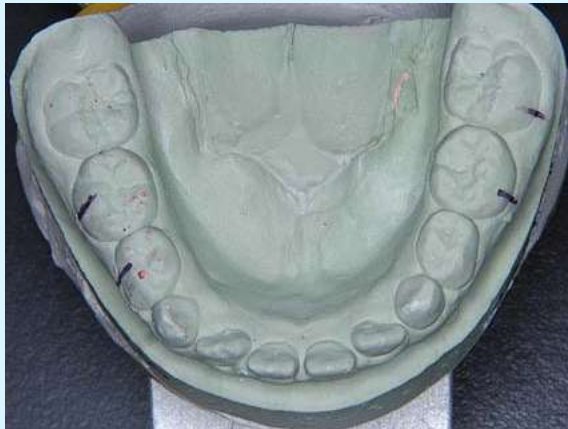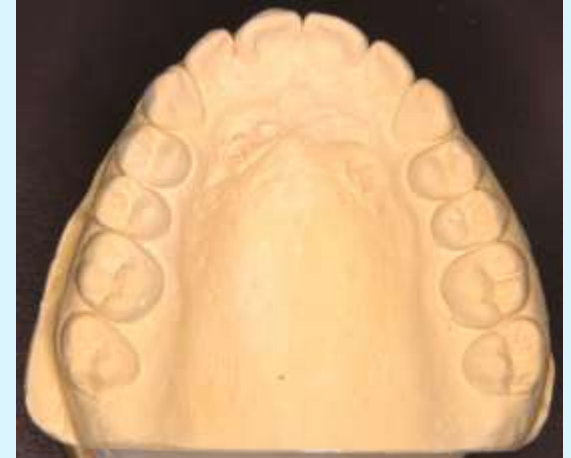Before FKO 1997-01



After FKO 2005-08

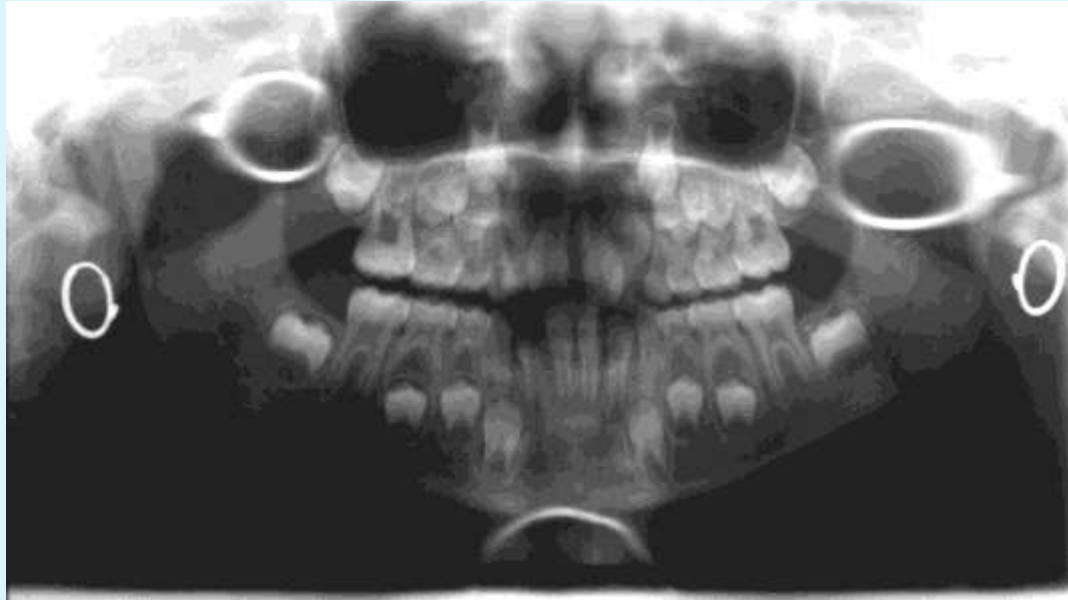


After KFO 2010-03

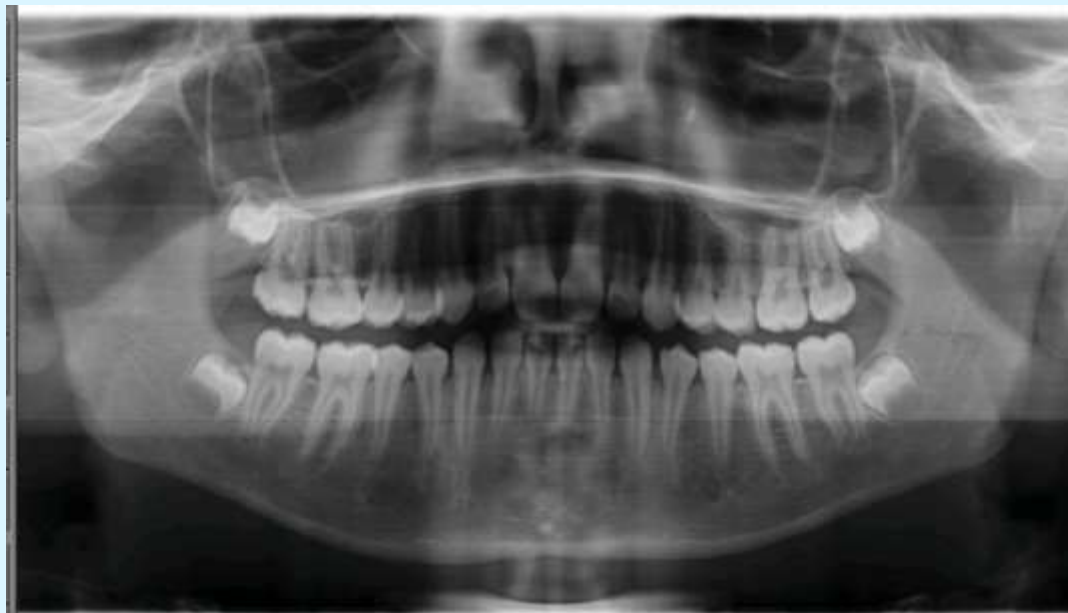



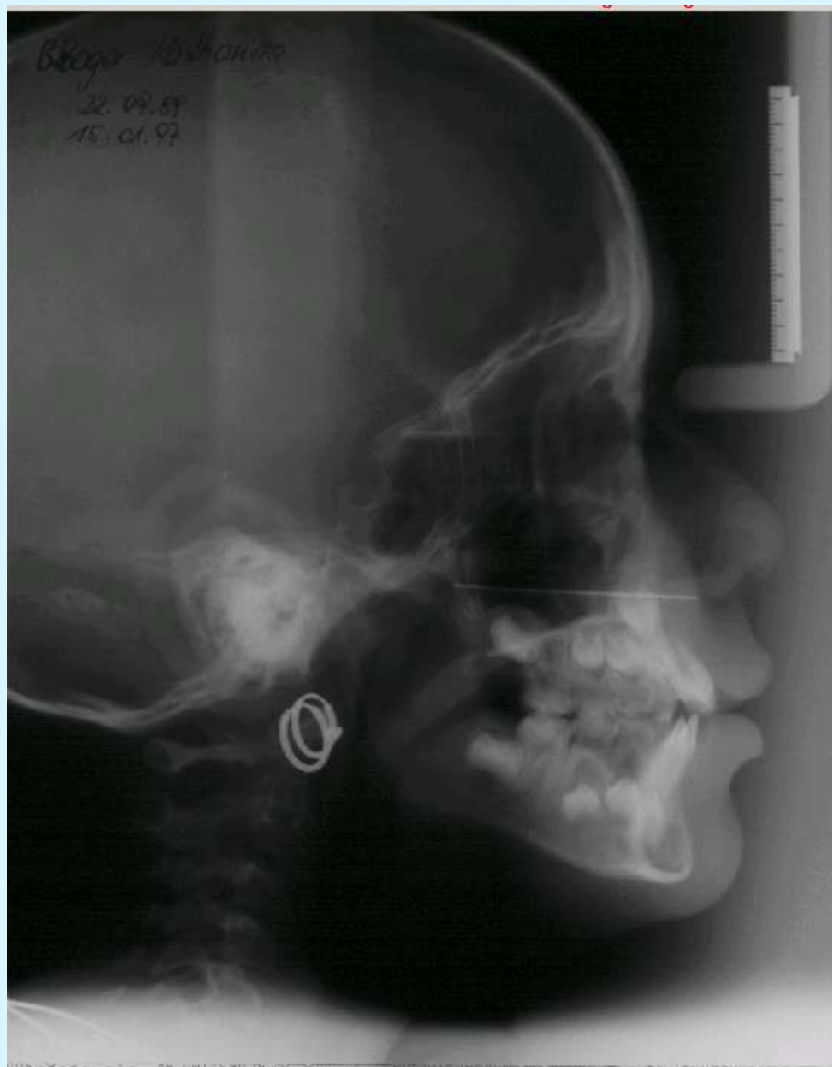Before FKO 1997-01



After FKO 2002-10



Before FKO 1997-01



After FKO 2005-08

