

Diagnosis

- Skel. CL III-tendency
- Skel. Deep-bite
- Dentoalv.1/2 CLII/2
- Steep-upper front w. retroclined 32,42
- Crossbite on 23/33 and 13 buccally outblocked
- Strong frontcrowding!!
- Overbite 2mm

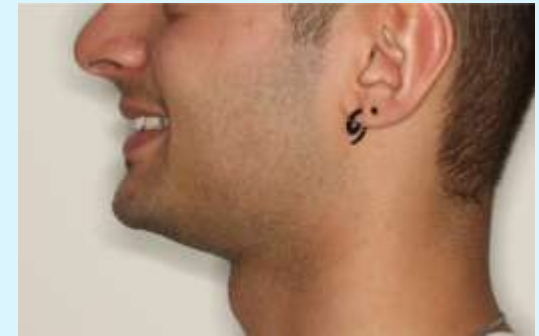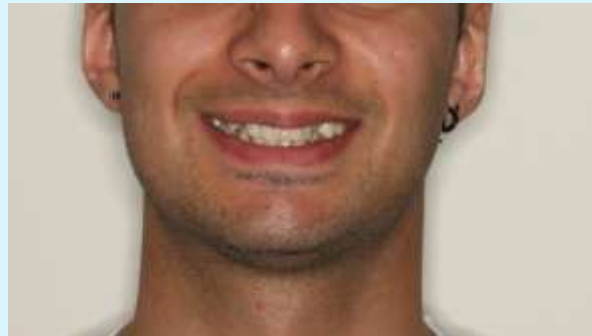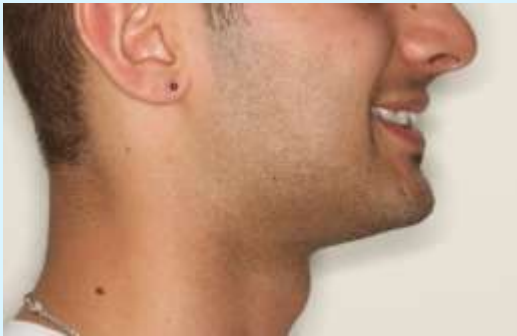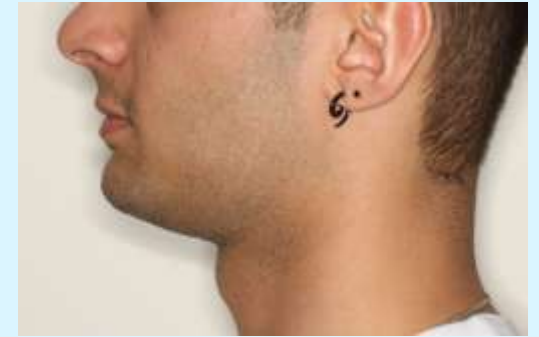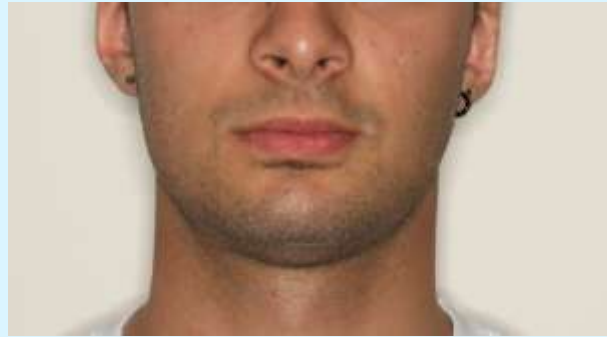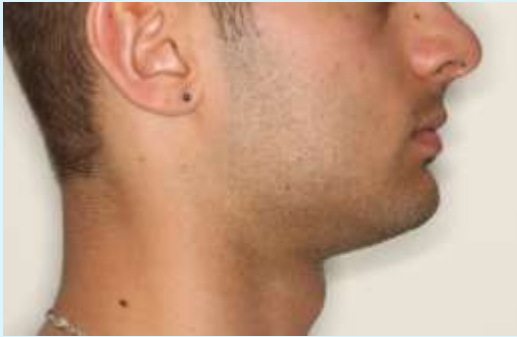Treatment Plan

- Gernectomy of all wisdoms in KH-Feldkirch
- Widening of the upper ant. arch
- Protrusion of upper front
- Verticalisation
- Aligment of frontcrowding
- CL I w. nice ant. guidance

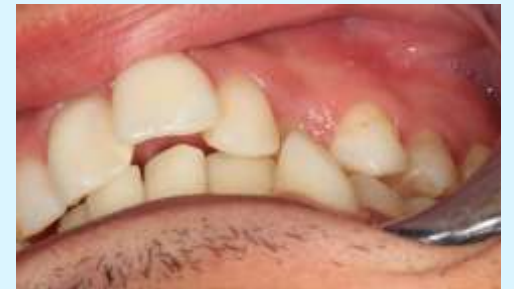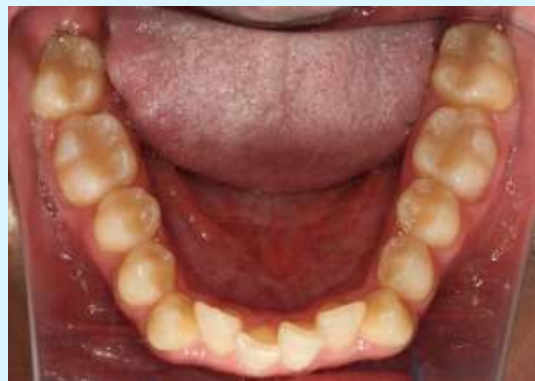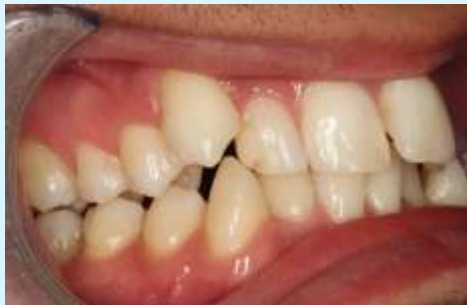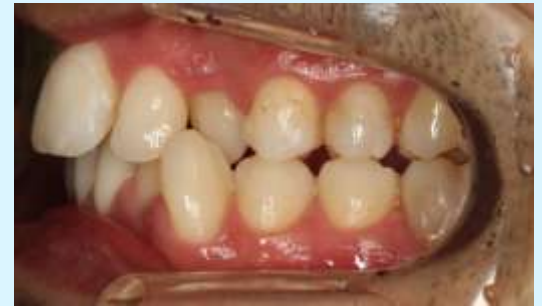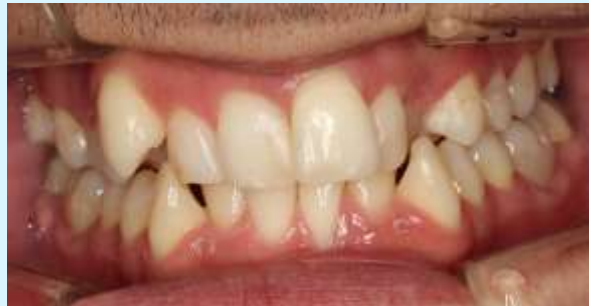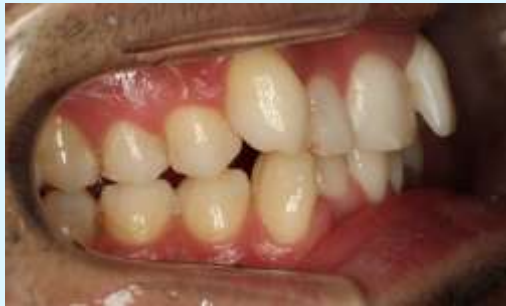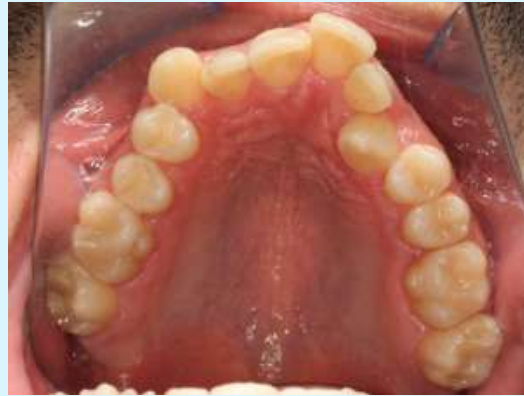
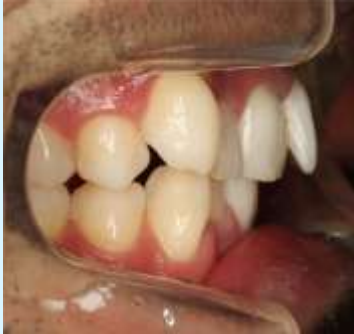Treatment Objectives

- Stage of leveling: UA-016 sentalloy, then 016 AW w. .-spee, in LA-016 Sentalloy, then 016 AW w. C.B.
- Stage of MEAW's: in UA-w. TBB and step down on 14/24 and ant. widening

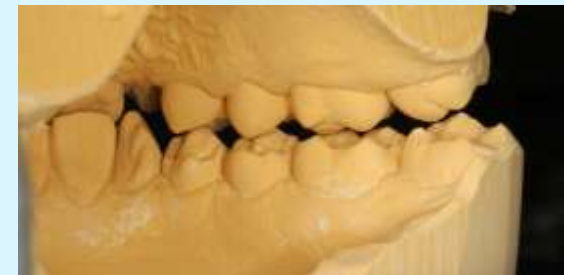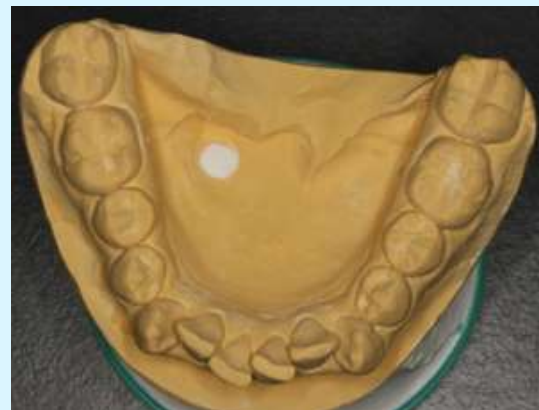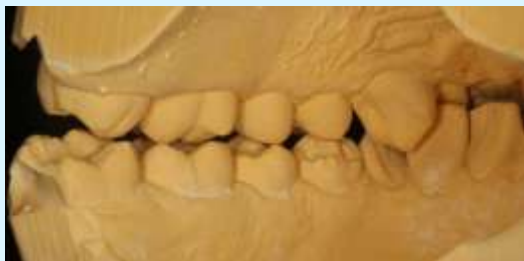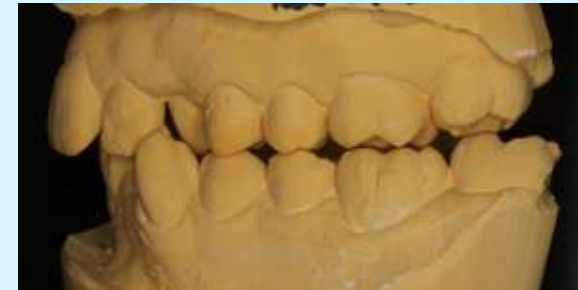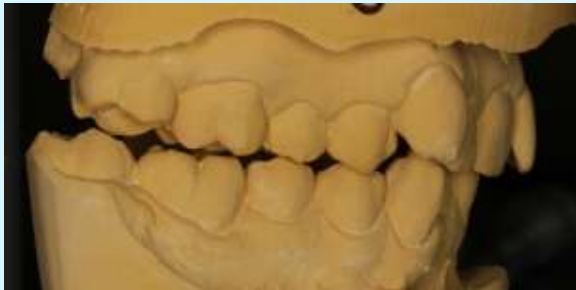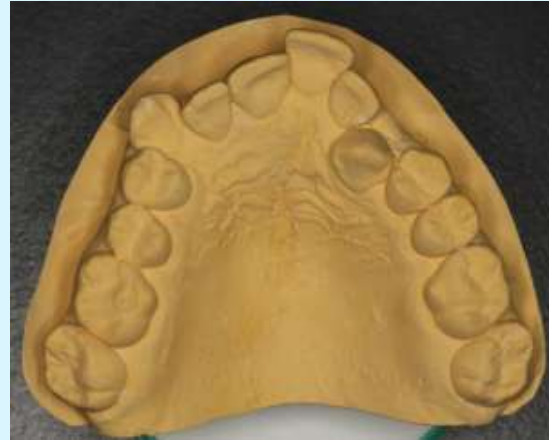2013-04 before KFO

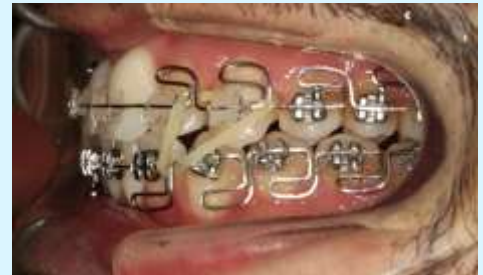
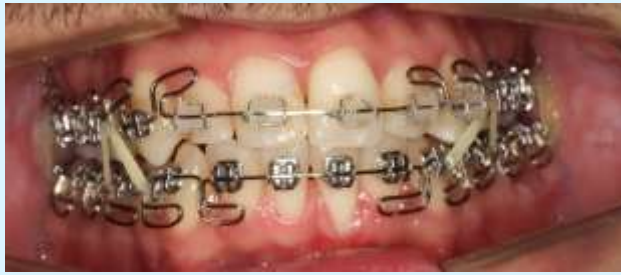
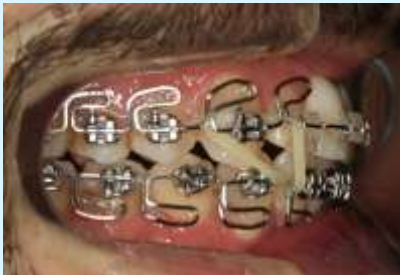
2013-04 before KFO

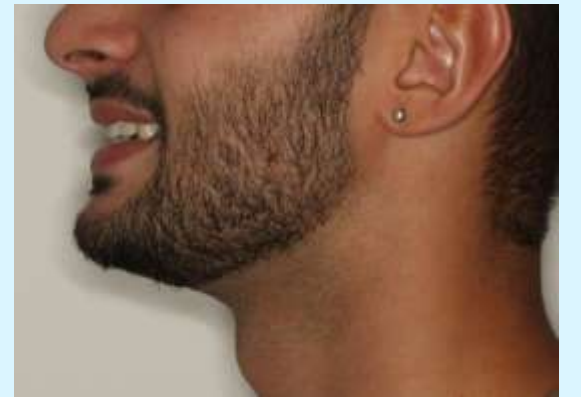
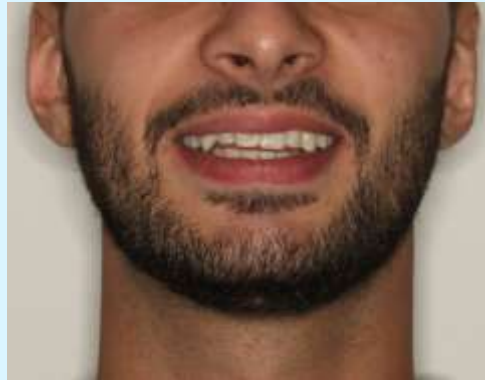
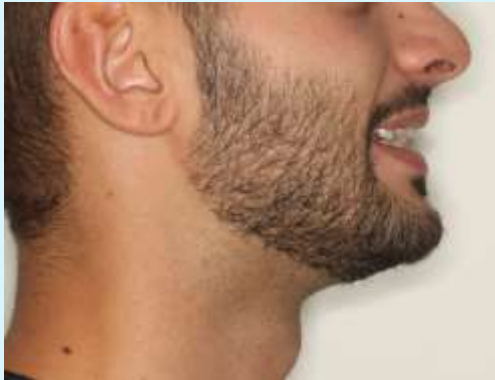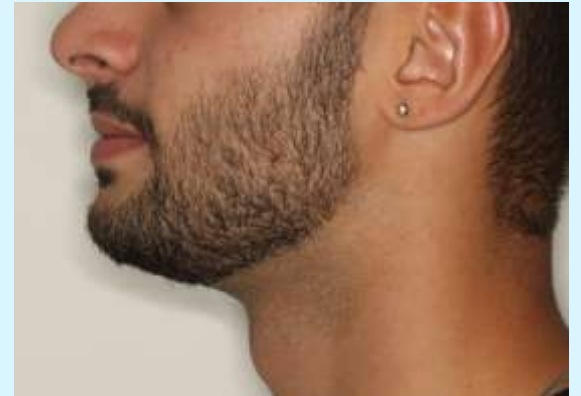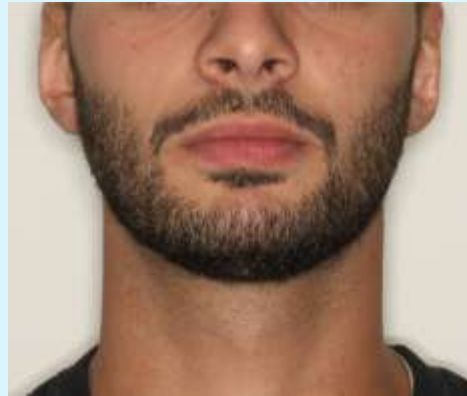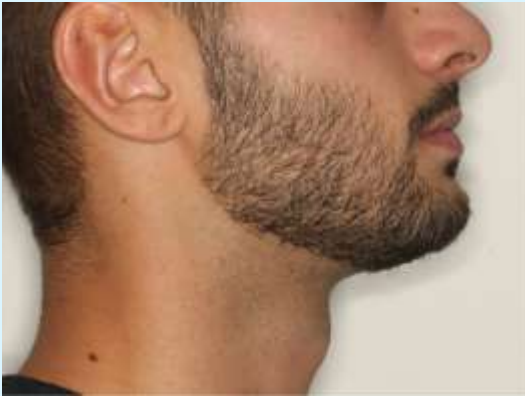2013-04 before KFO

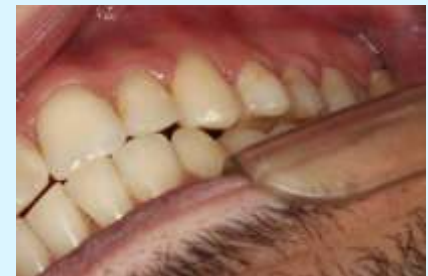
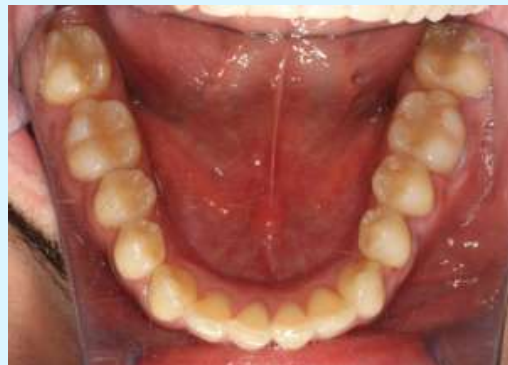
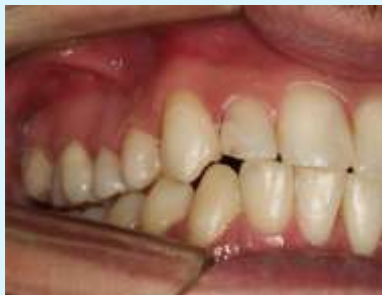
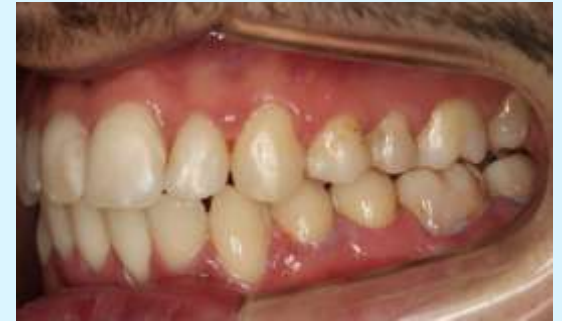
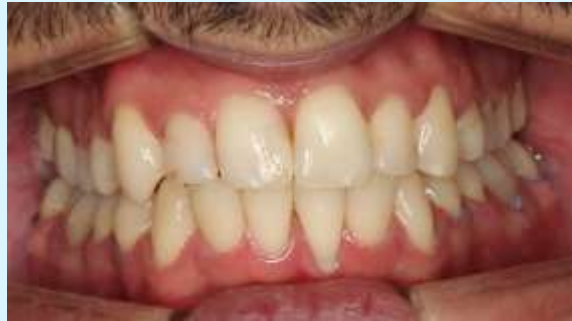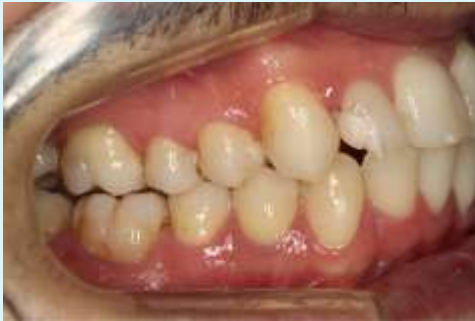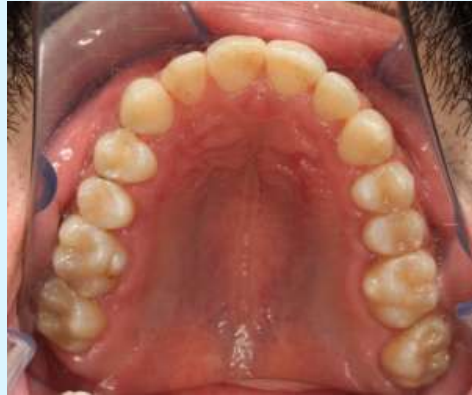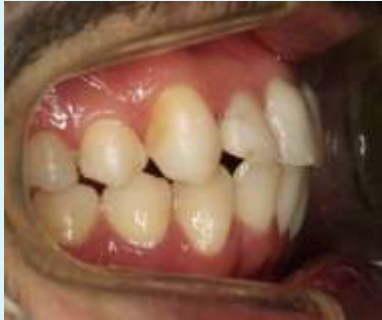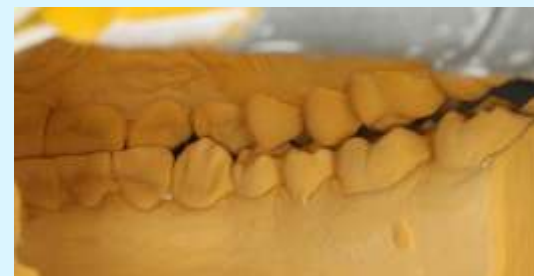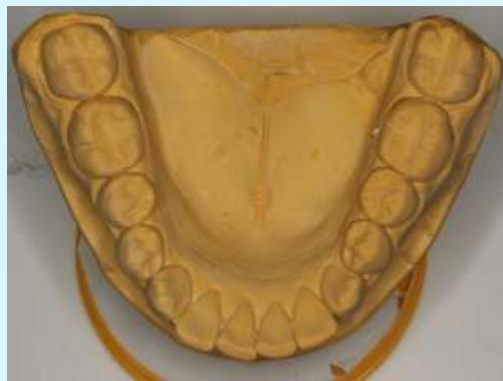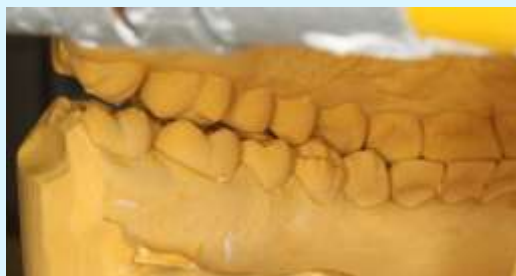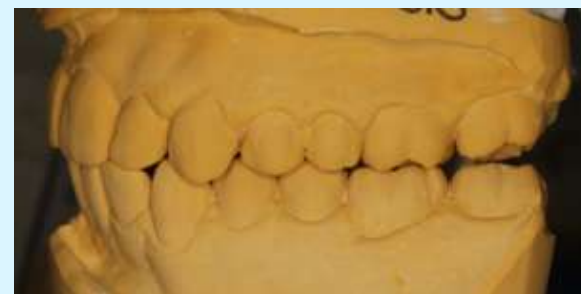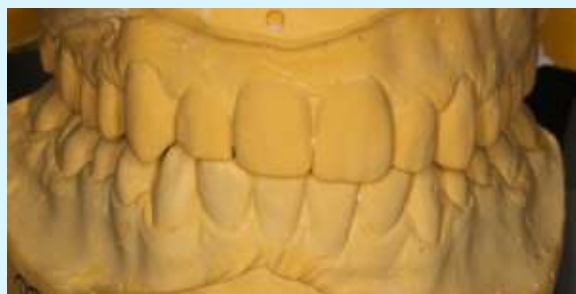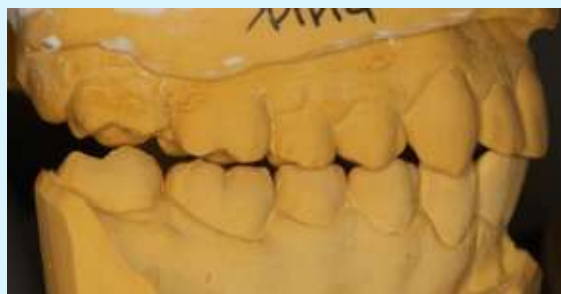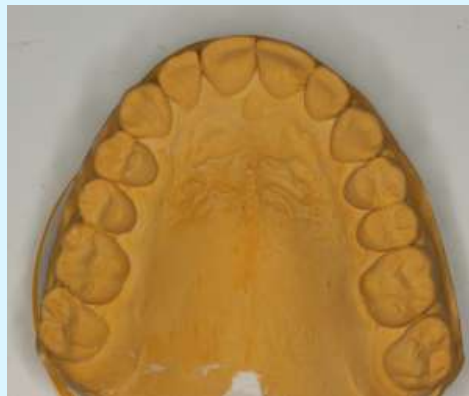2014-11 after KFO



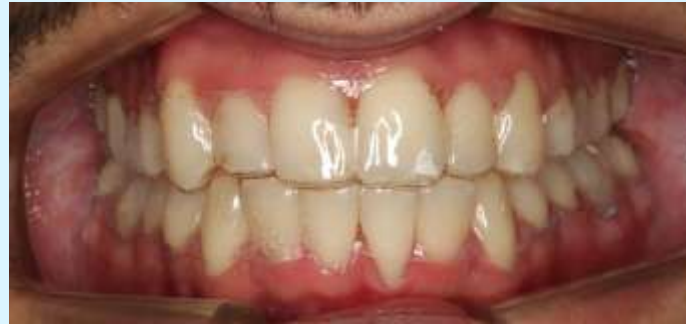2014-11 after KFO



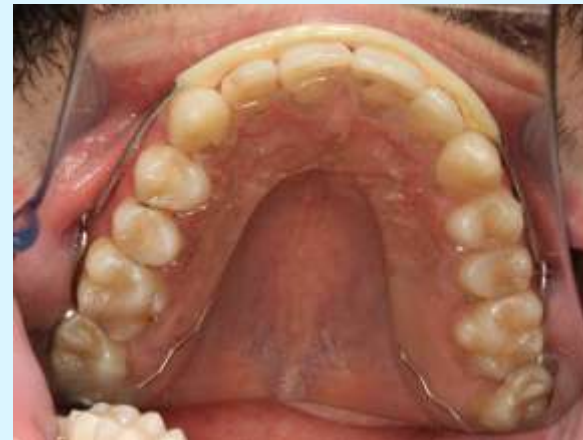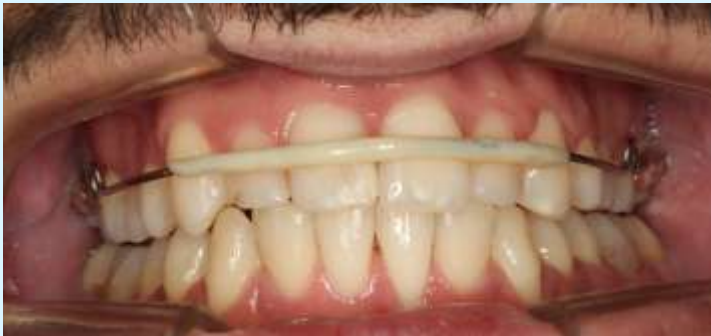2014-11 after KFO



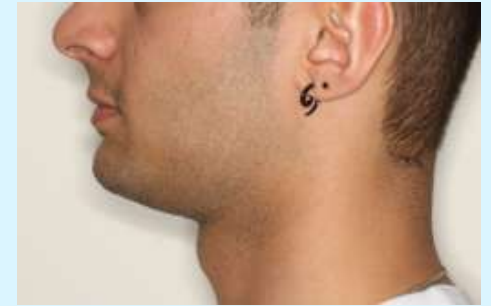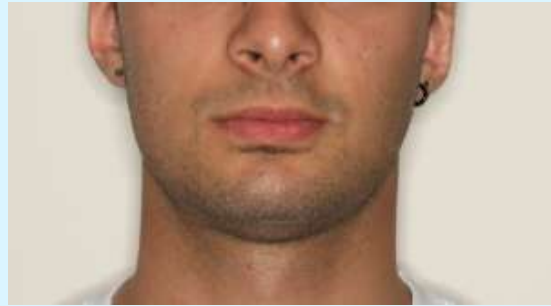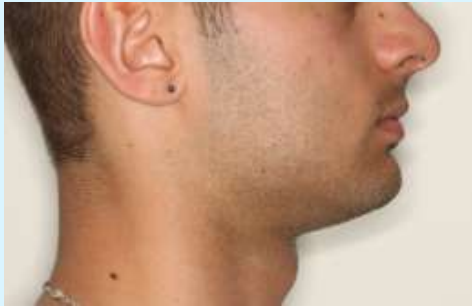2014-11 Splint for the day



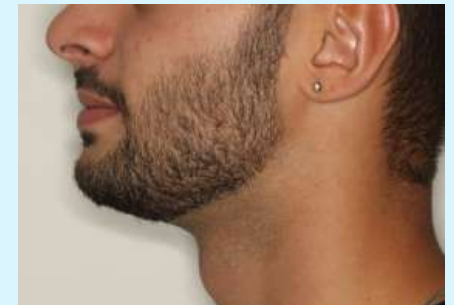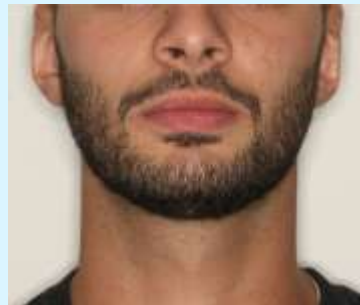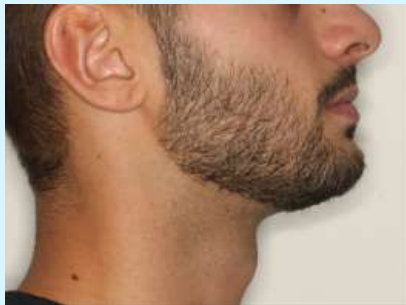2014-11 Sato-Retainer for the night



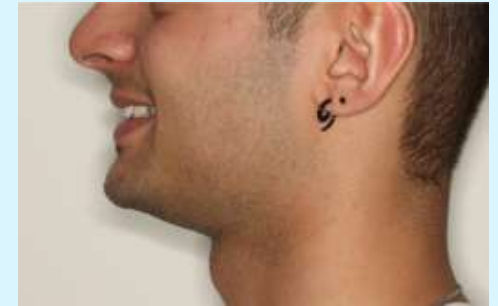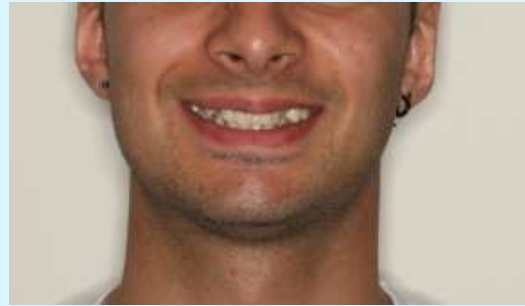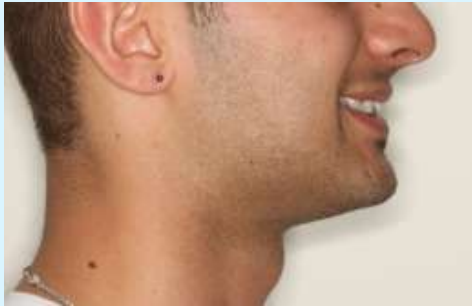2013-04 before KFO



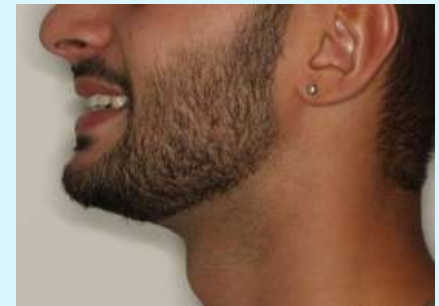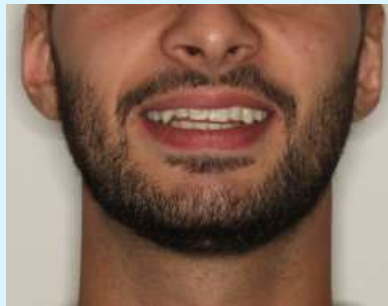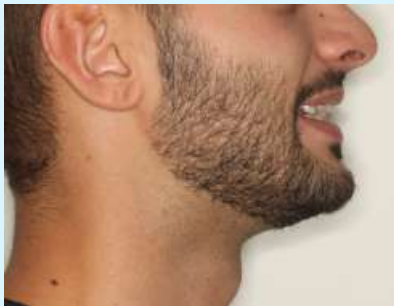2014-11 after KFO



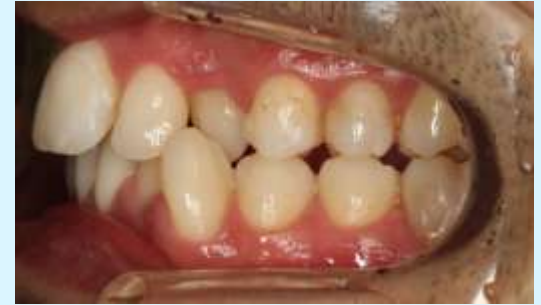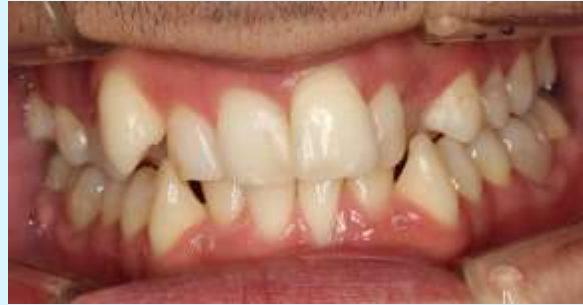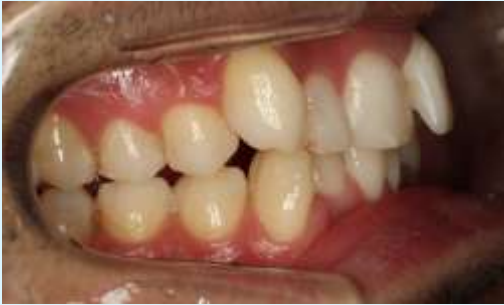2013-04 before KFO



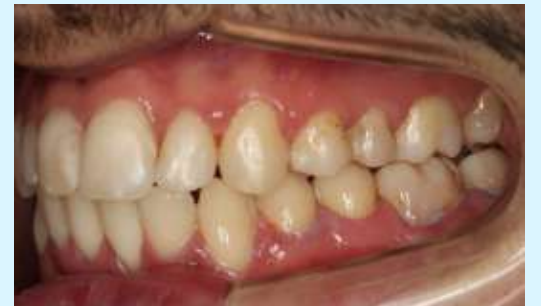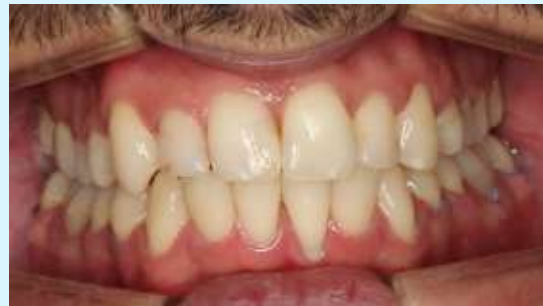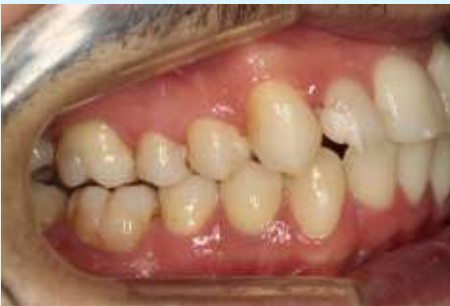2014-11 after KFO



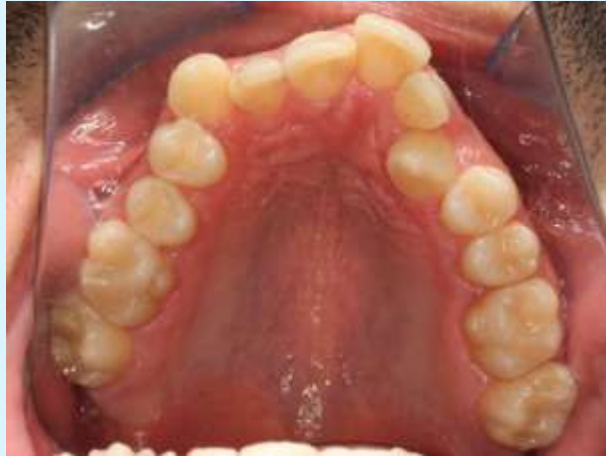2013-04 before KFO



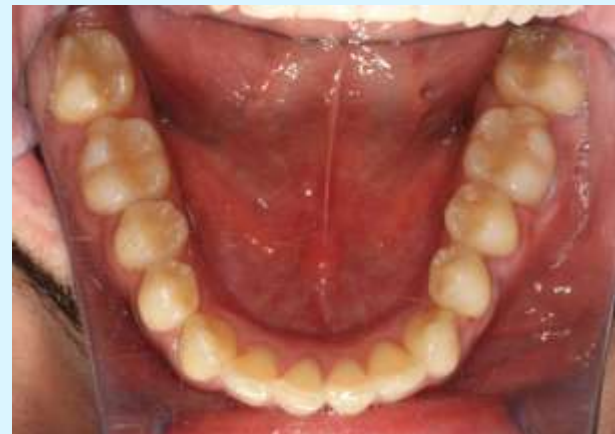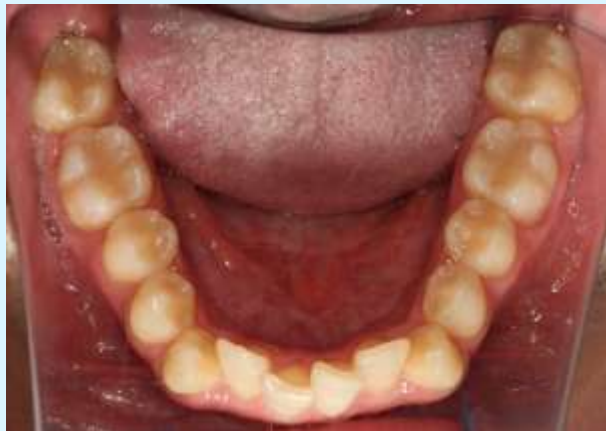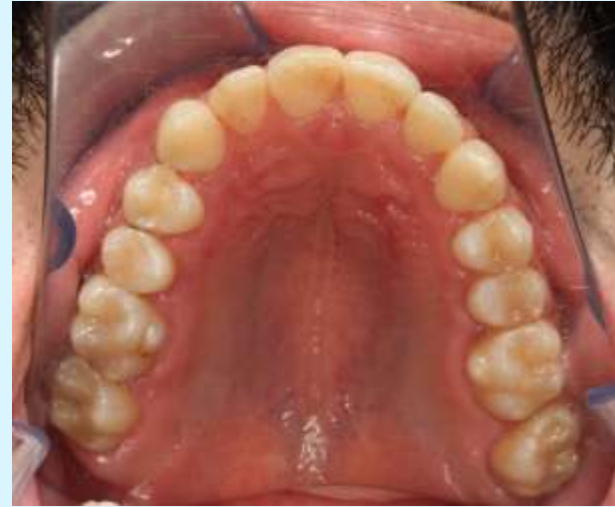2014-11 after KFO



2013-04 before KFO



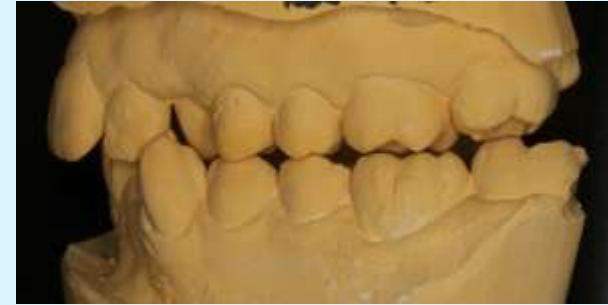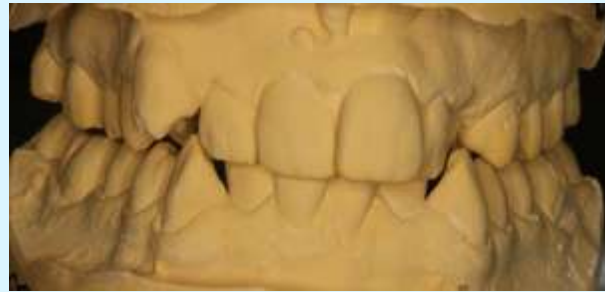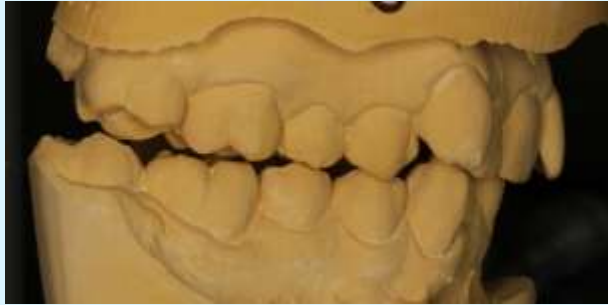2014-11 after KFO



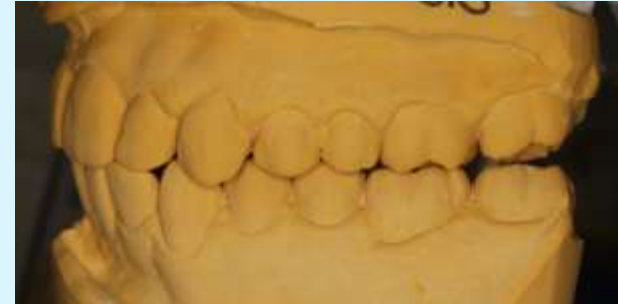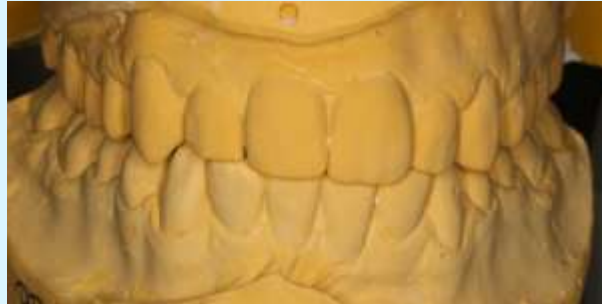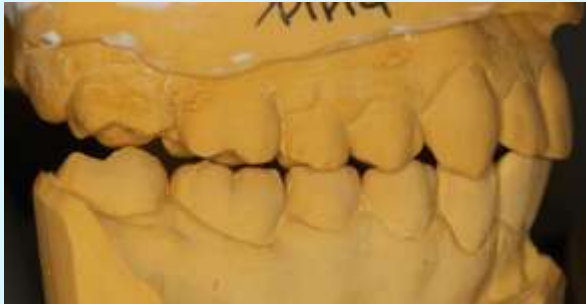15

15

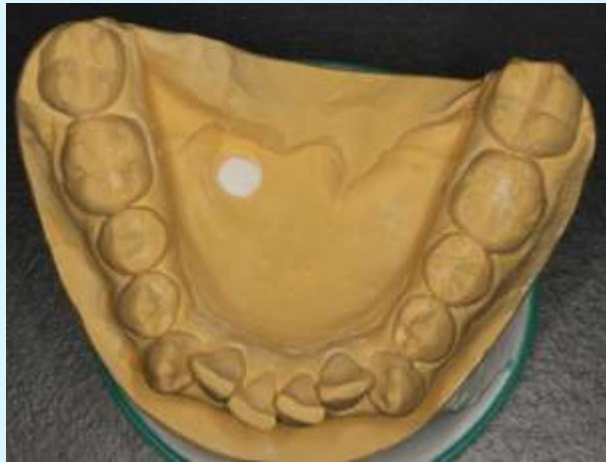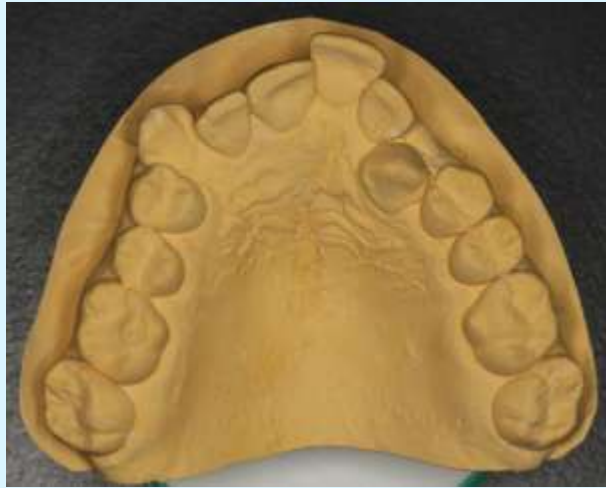2013-04 before KFO



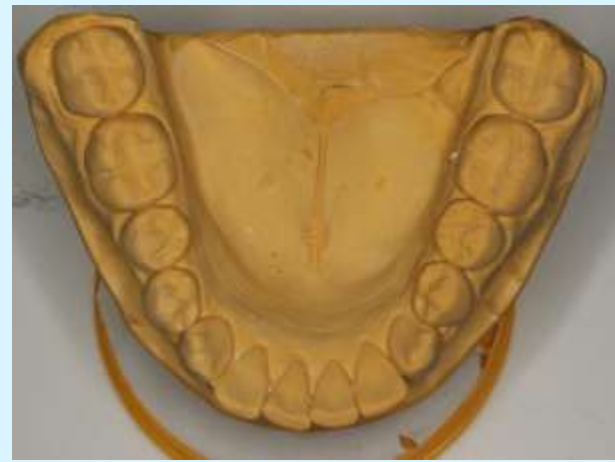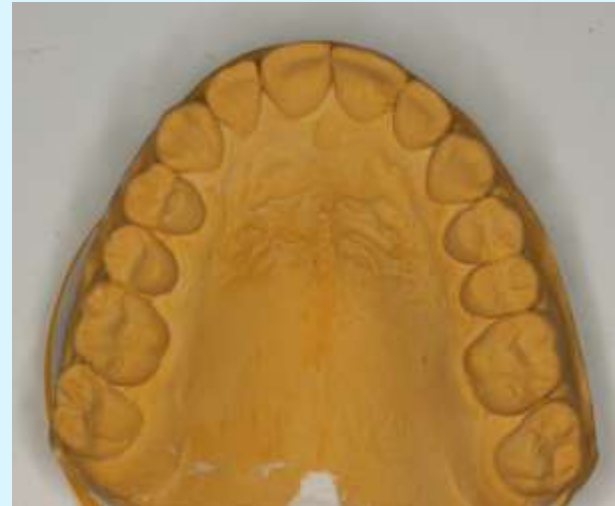
2014-11 after KFO



2013-04 before KFO

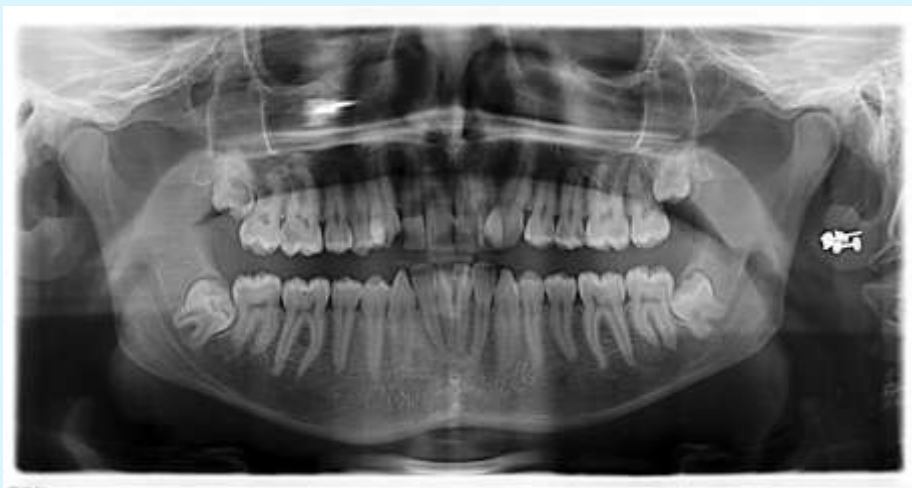

2014-11 after KFO

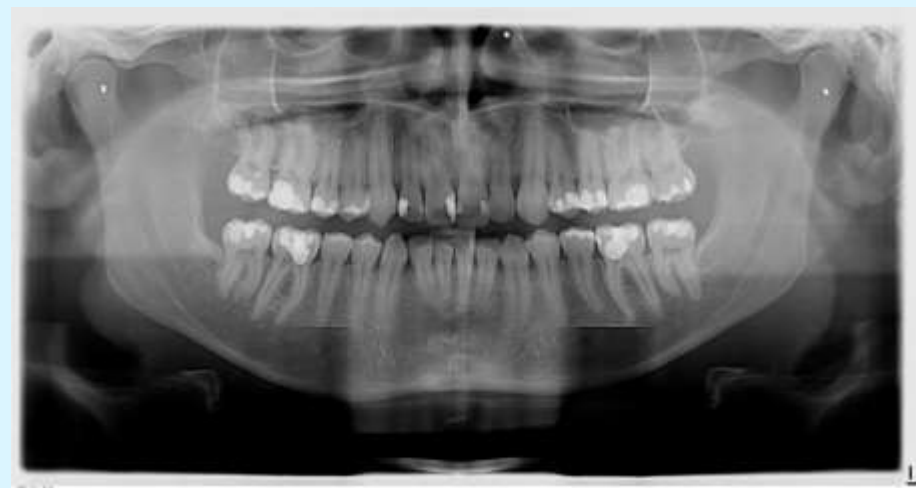

17

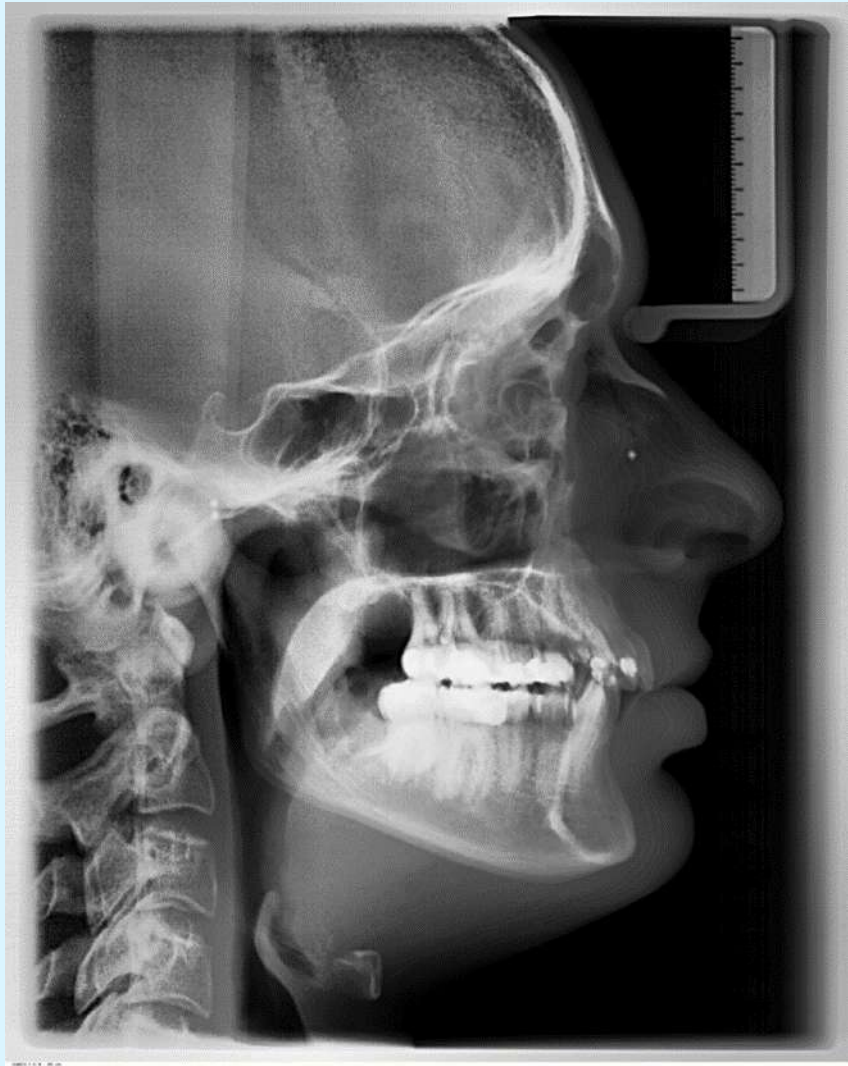17



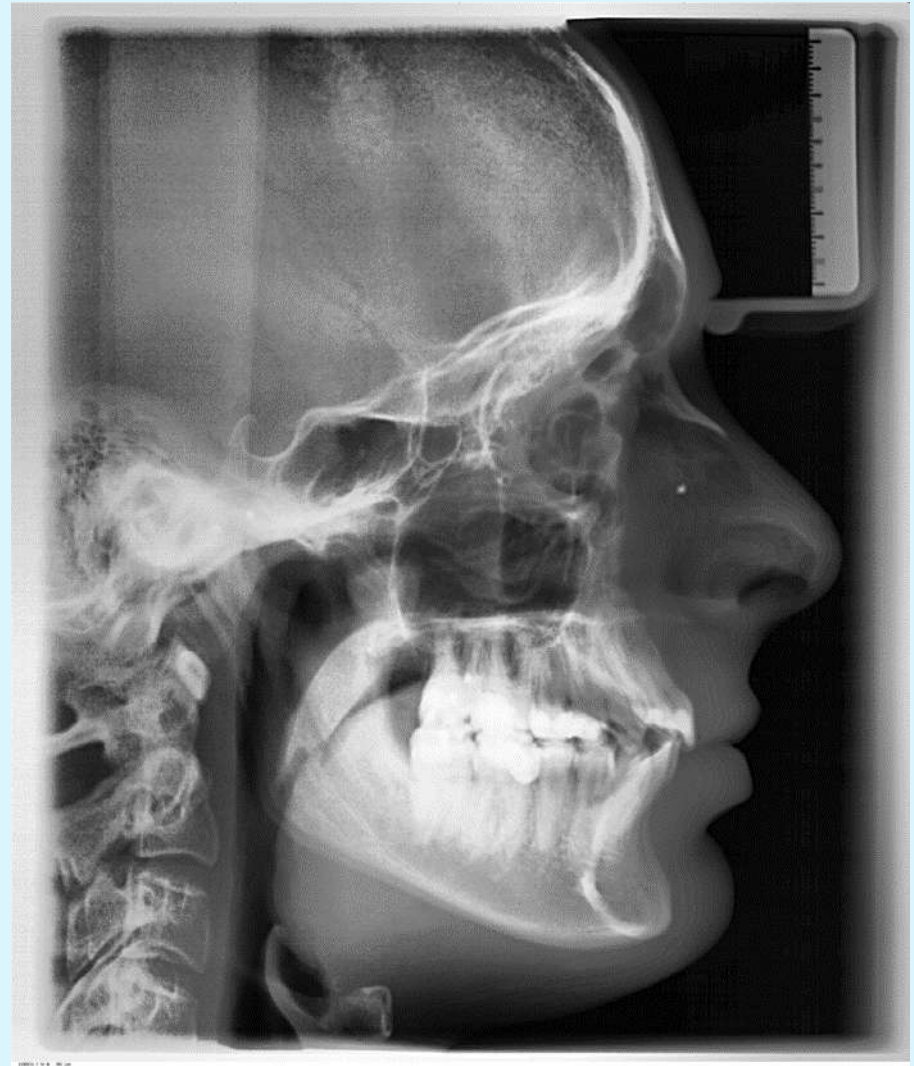2012-08 before KFO



2015-02 after KFO

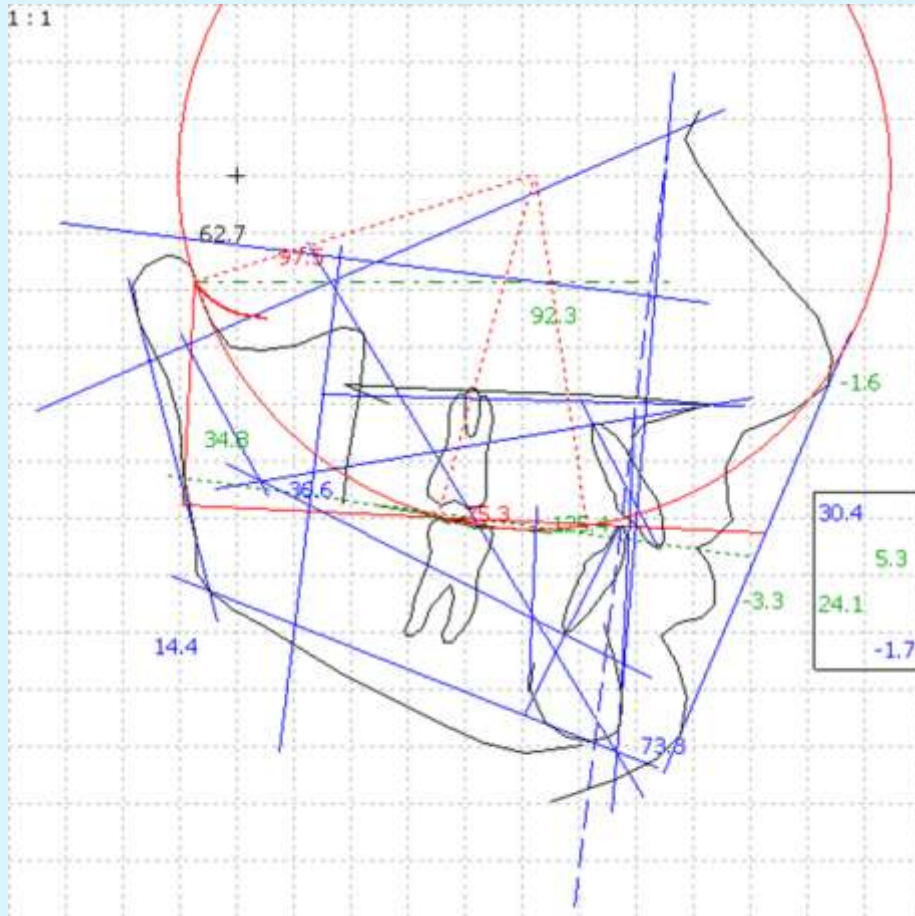


2013-04 before KFO

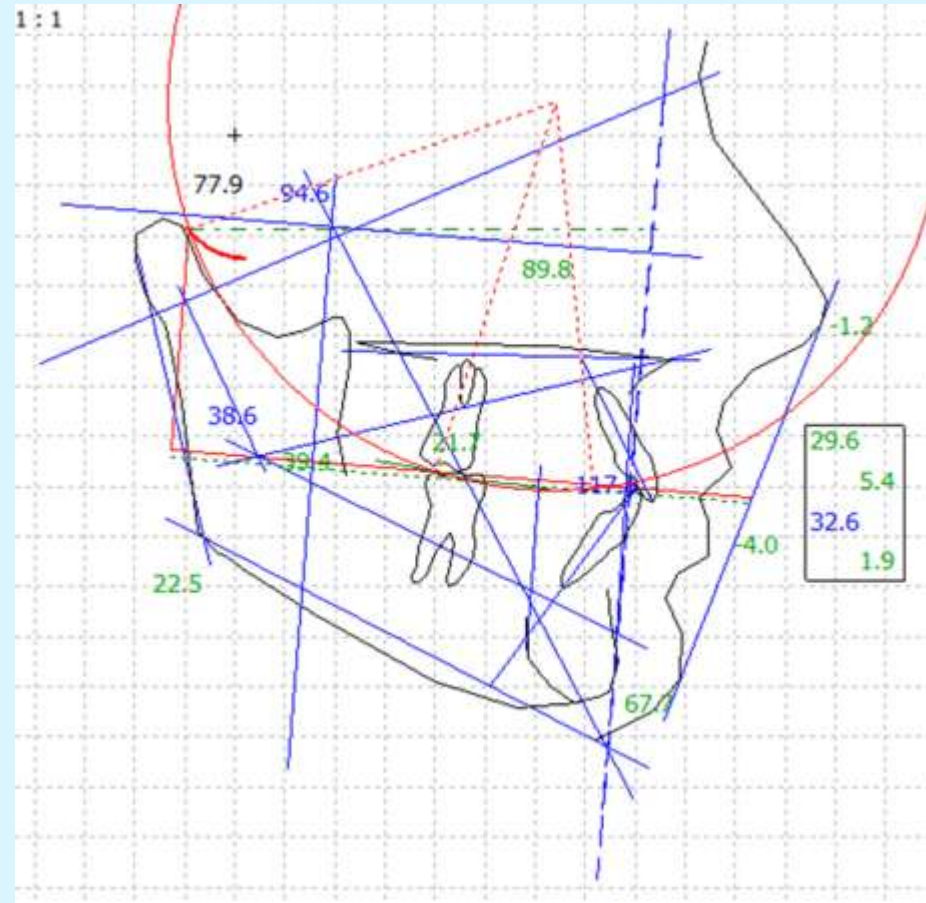


2015-02 after KFO

Slavicek Durchzeichnung

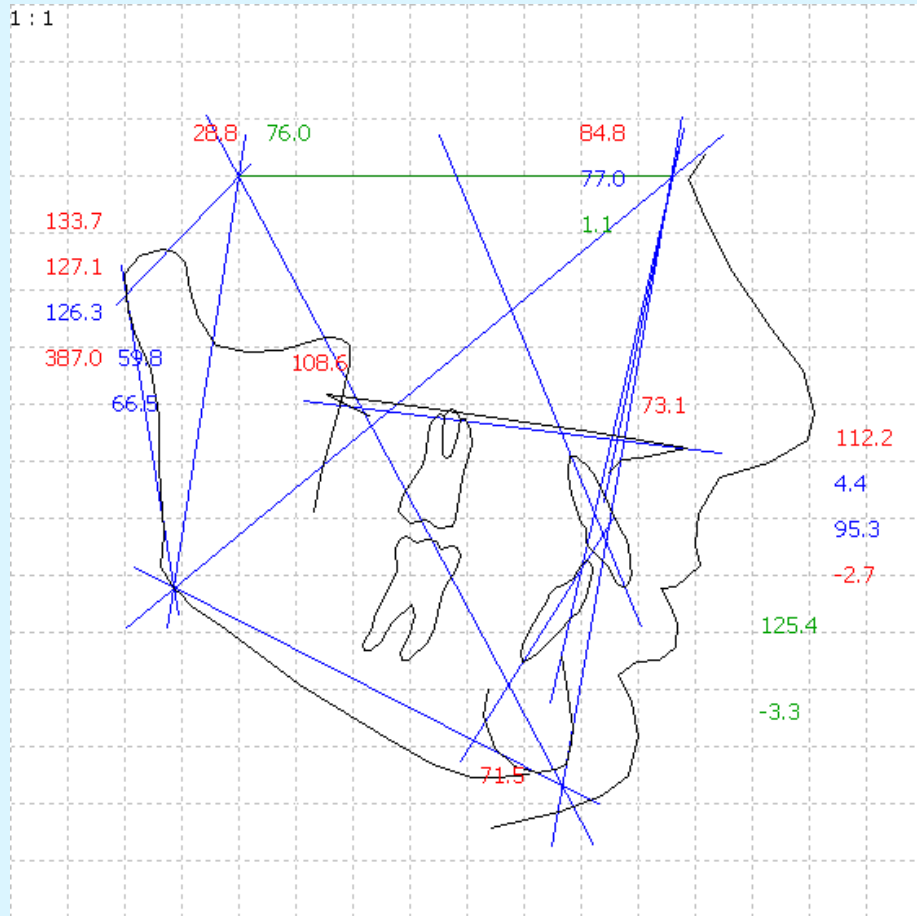


2013-04 before KFO

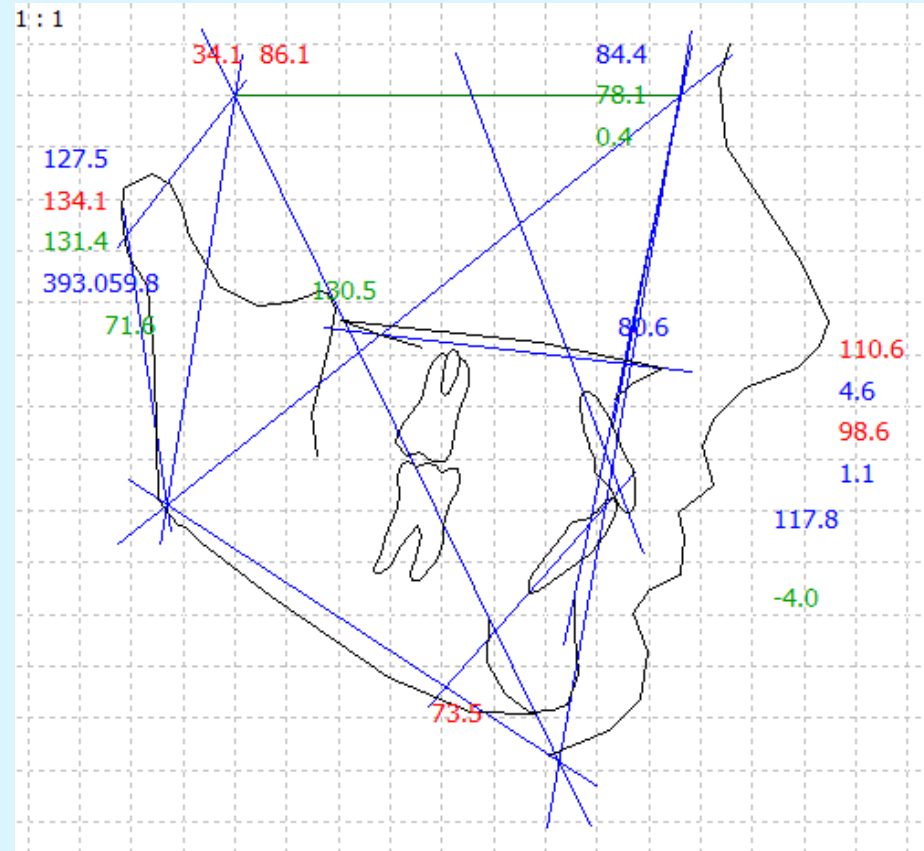


2015-02 after KFO

Jarabak Durchzeichnung



2013-04 before KFO



2015-02 after KFO