

# Diagnosis

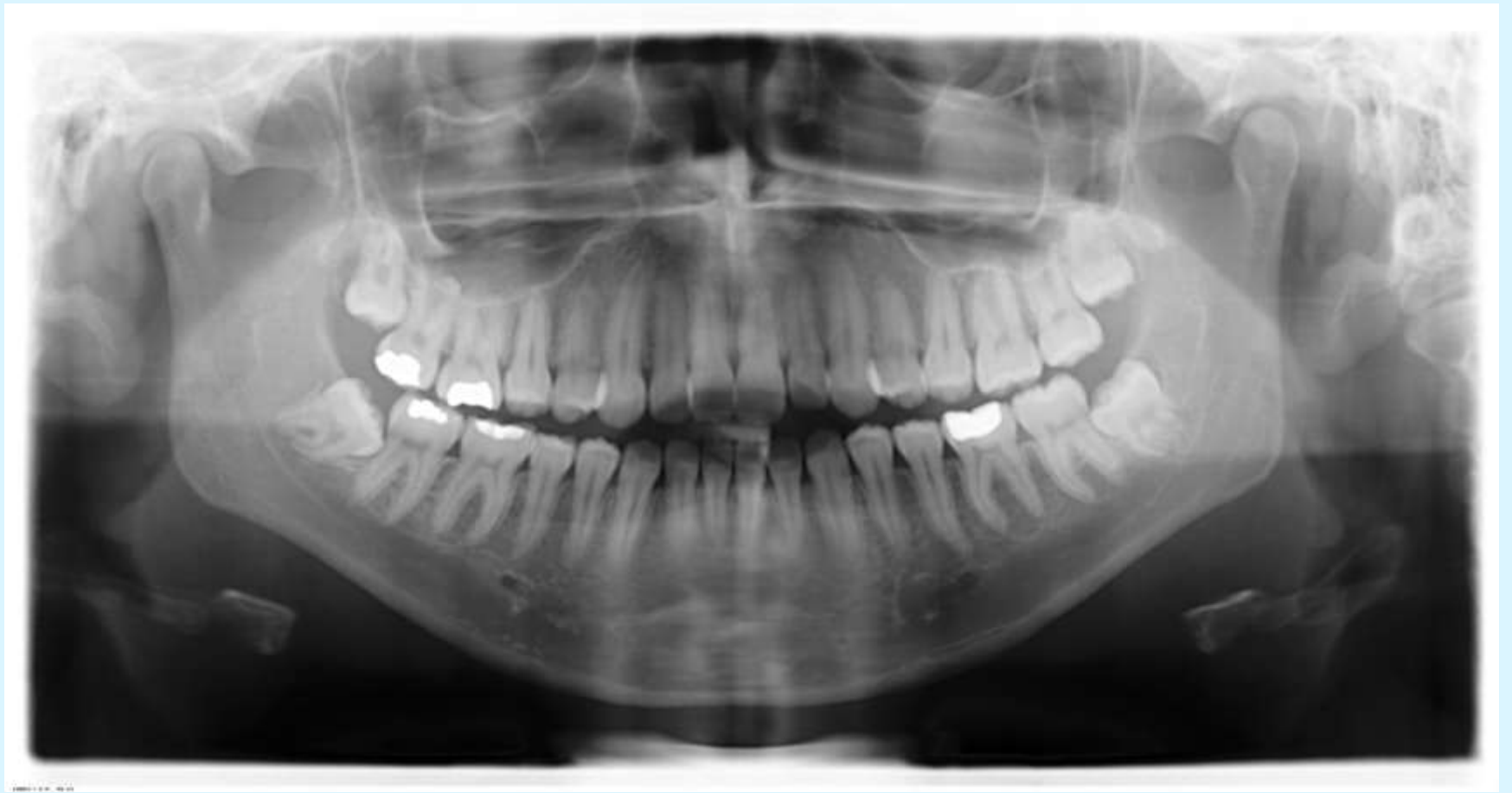- Skel. CLII(max. Prognathie and mand. Retrognathie)
- Skel. open bite (high angle CL II case!!)
- Dentoalv. ½ CL II/1
- Protrusion of upper front!!
- Dentoalv. open bite from first premolar to first premolar→chron. mouthbreathing!!
- Lyraform of upper ant. arch!!
- Cross-bite in regio of both second premolars
- Crowding in LA & UA
- post.discrepancy and no ant. guidance with post. interferences!!!!!!!!!!!!!!!!!!!!!!
- Poor mastication
- TMJ-clicking re.→note axio data!!

# Treatment Plan

- Gernectomy of all wisdoms!!!!!!!!!!!!
- Enlargement of the narrow upper ant. arch
- Intrusion in regio of the first molars!!
- Closing fo the ant. open bite
- Correction of cross-bite re. & left
- Alignement of crowding
- CL I with nice ant. guidance and without post. interferencies!!!

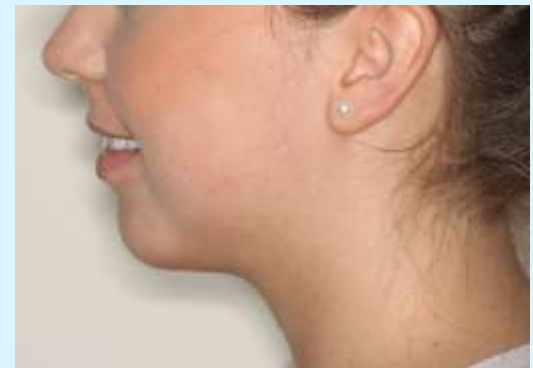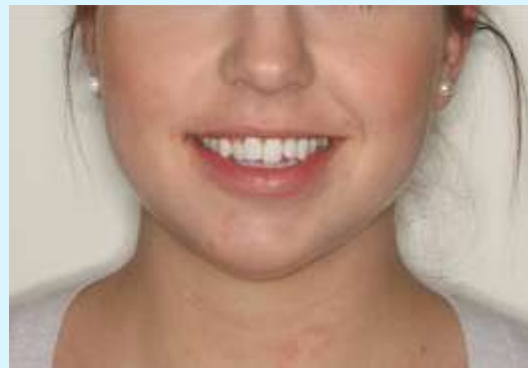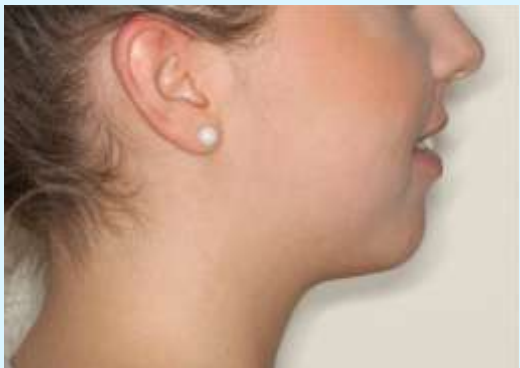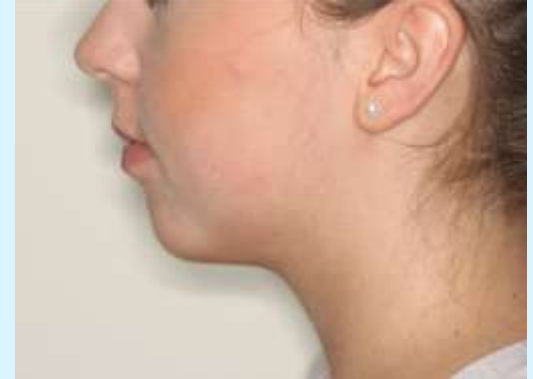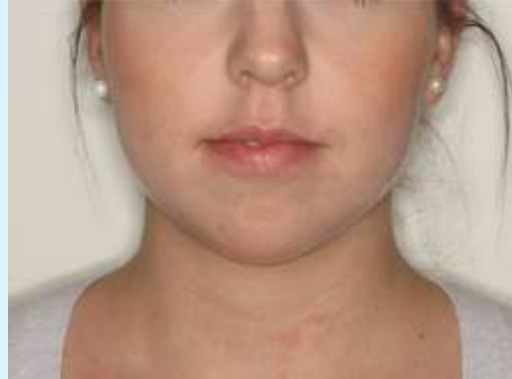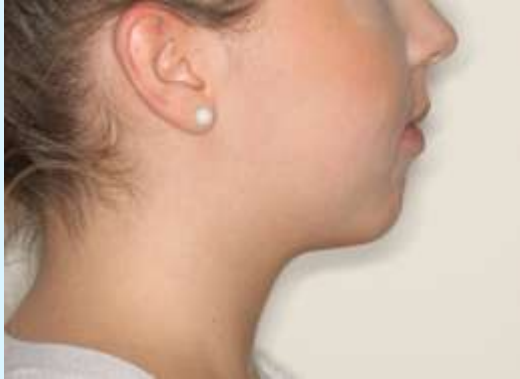# Treatment Objectives

- Stage of leveling: UA-016 Sentalloy, LA –at once MEAW with depression on first lower molars and step up on 34& 44 and ant. el. B.s.
- Stage of MEAW in UA with sl. TBB & ant. widening

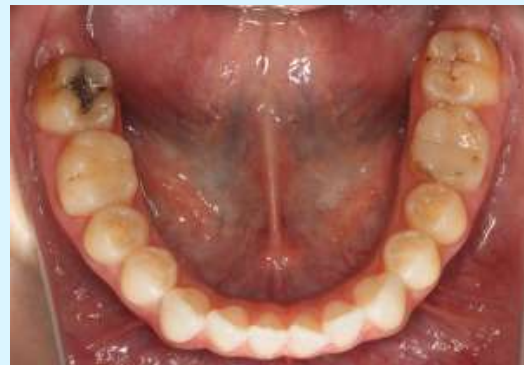
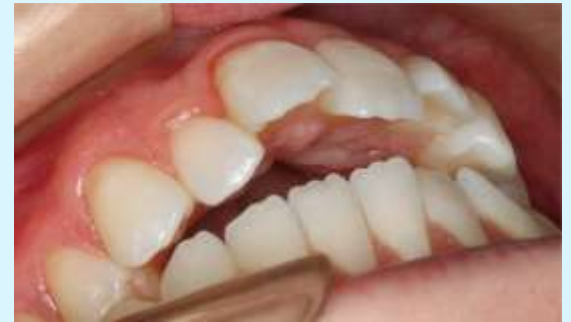
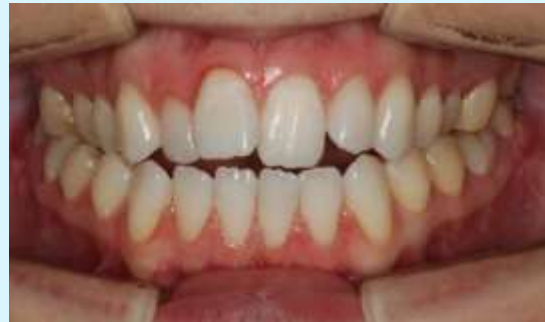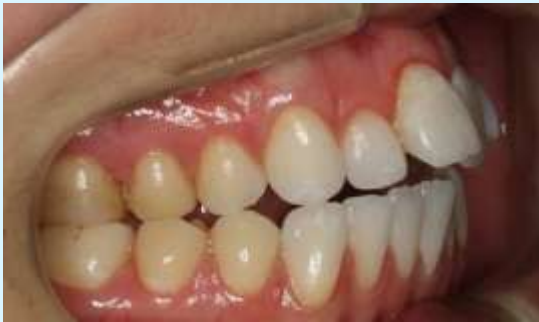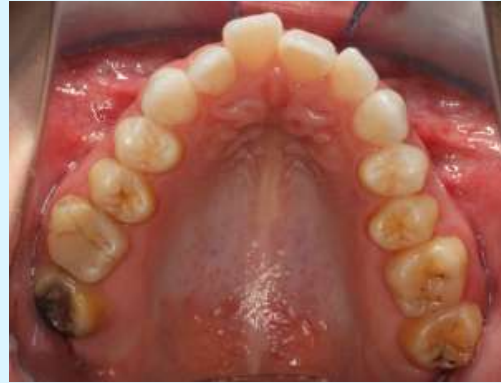2011-07-08

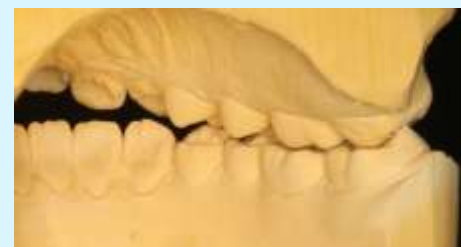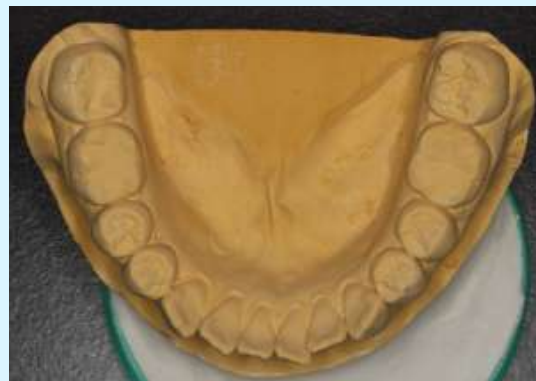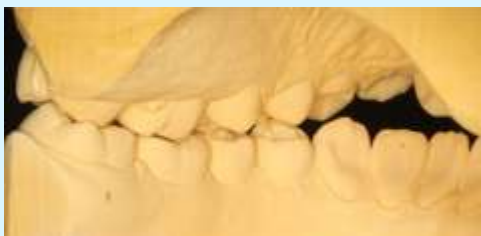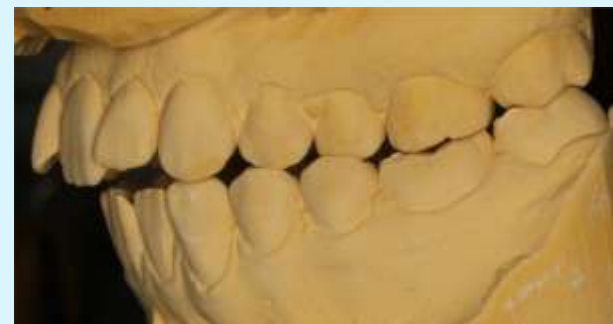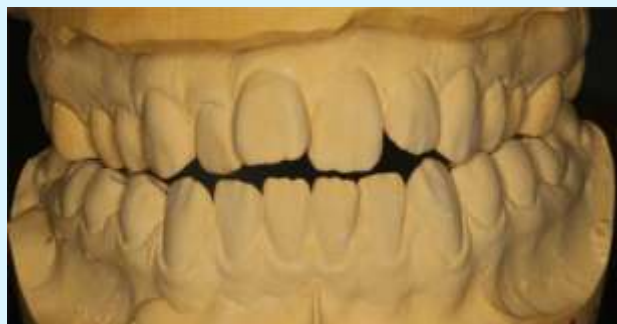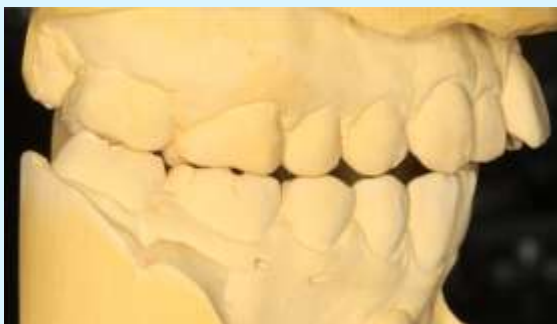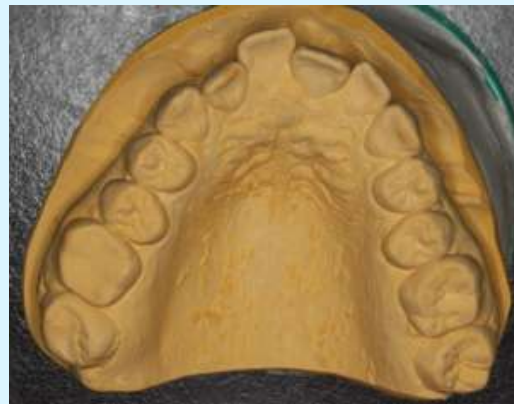2011-09 before KFO



2011-09 before KFO



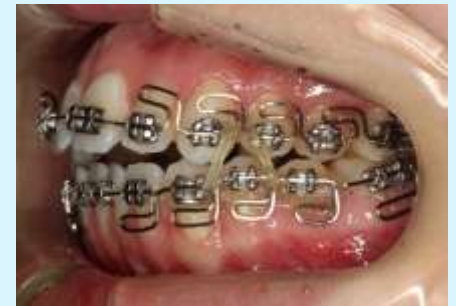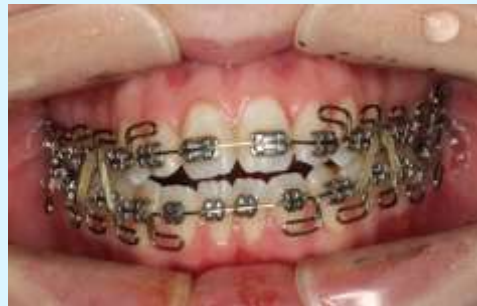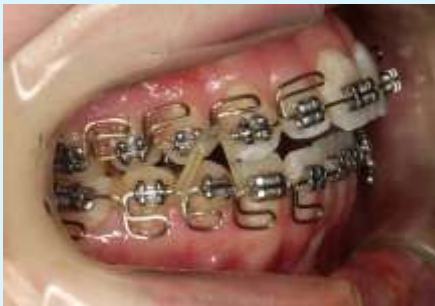2011-09 before KFO



## MEAW for the upper jaw



## MEAW and elastics

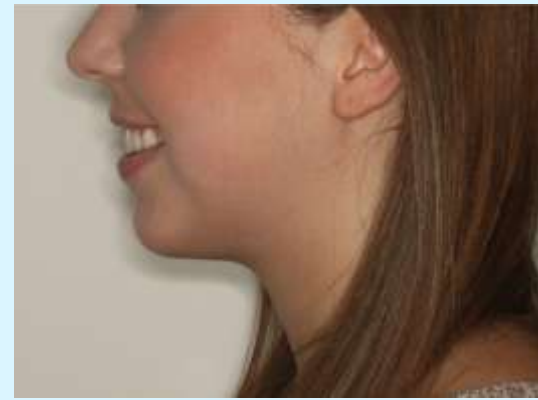
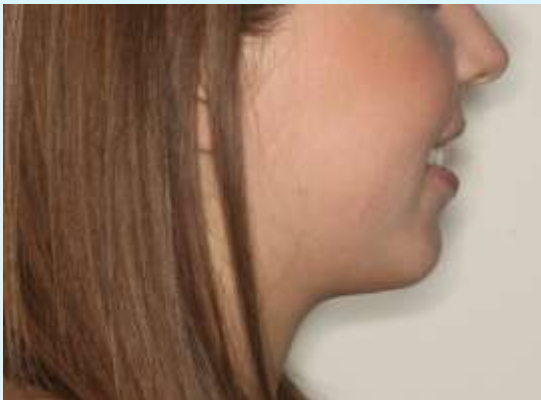
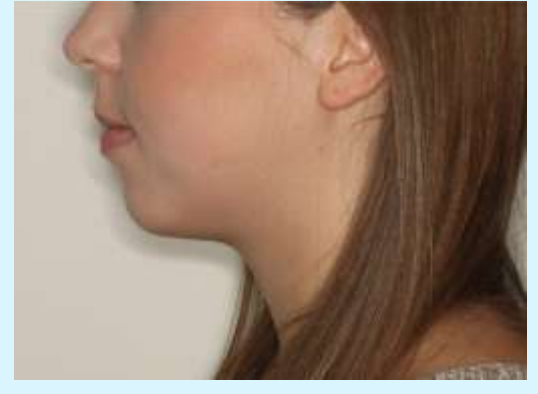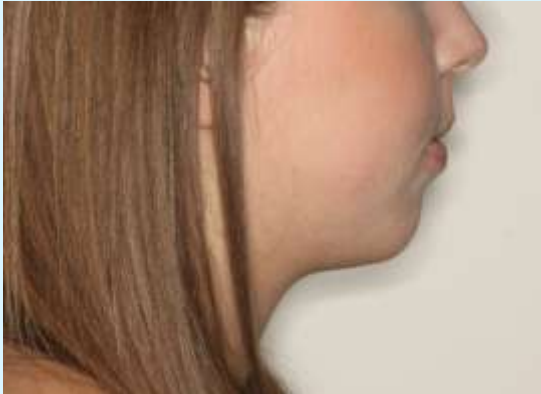## MEAW for the lower jaw

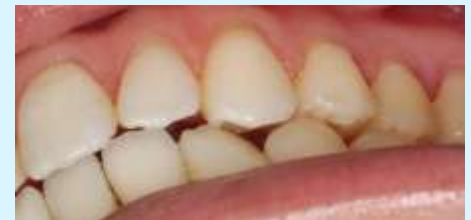
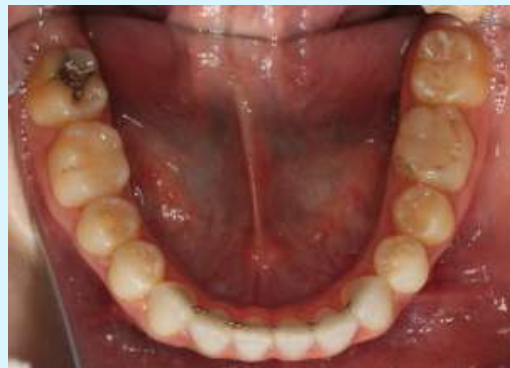
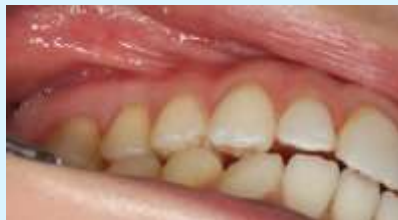
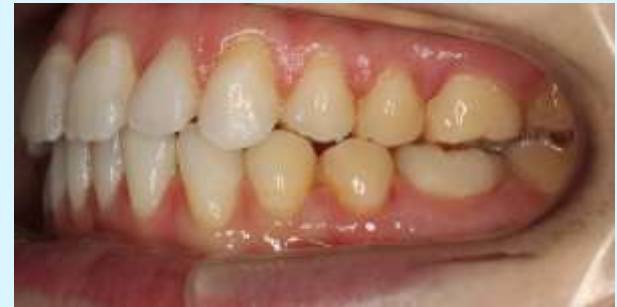
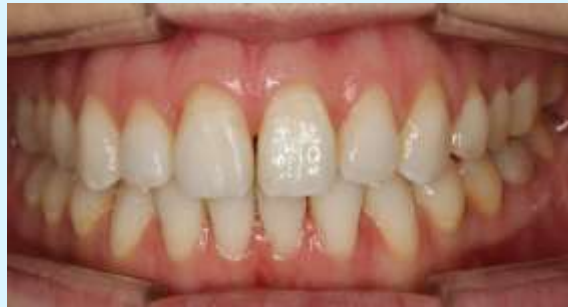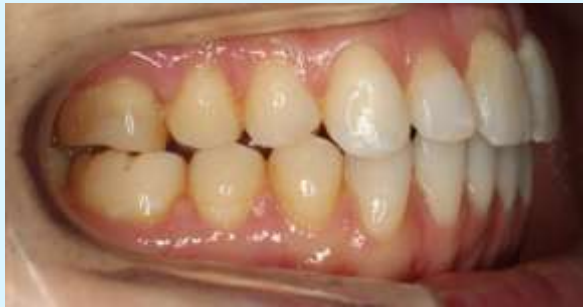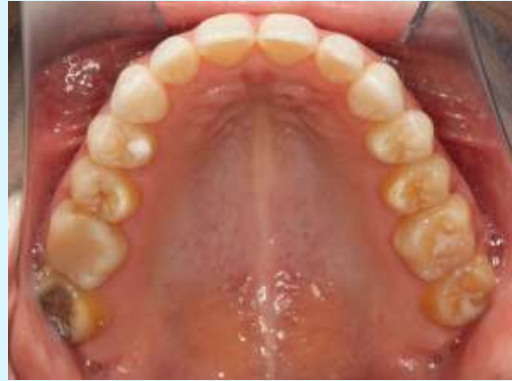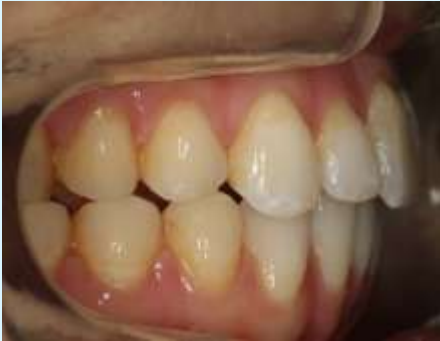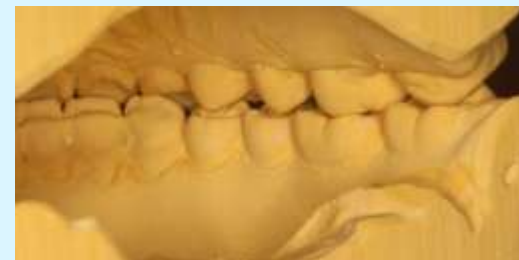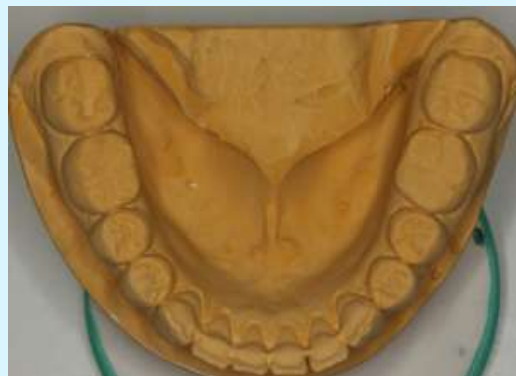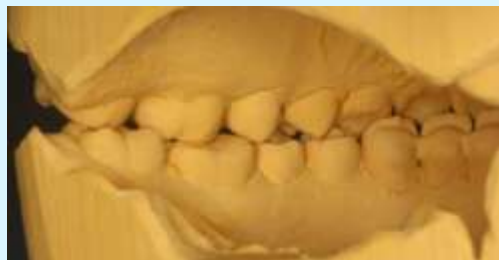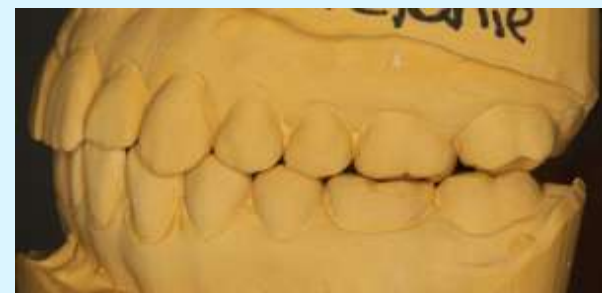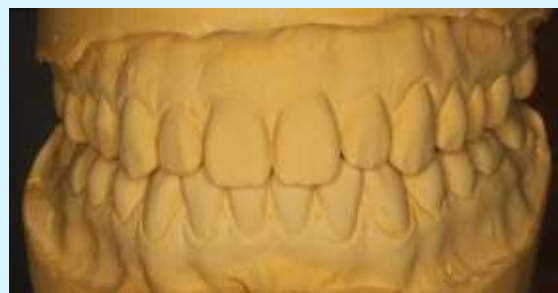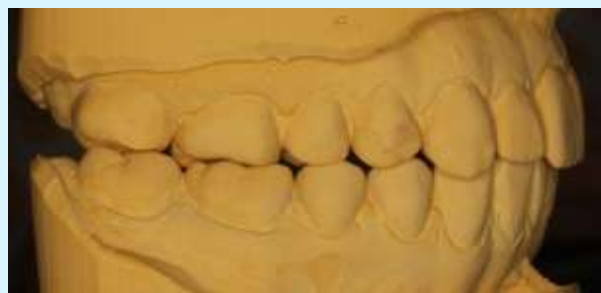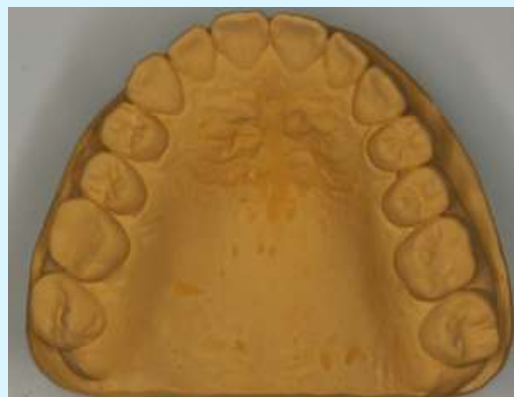2012-10 after KFO



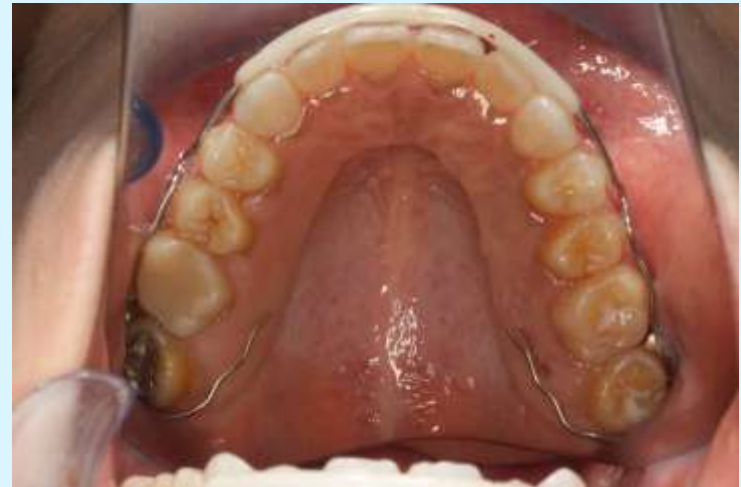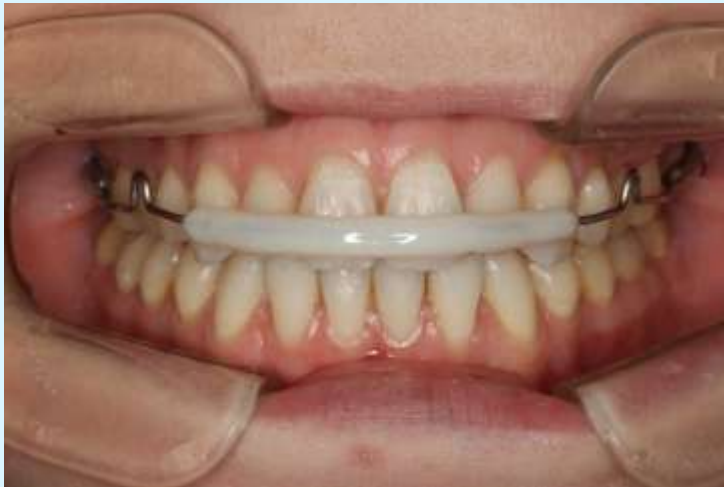2012-10 after KFO



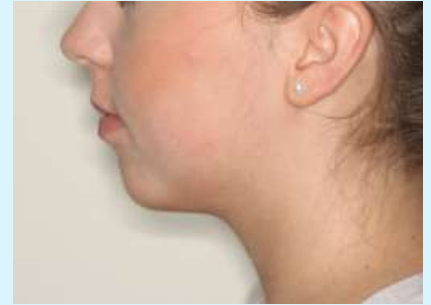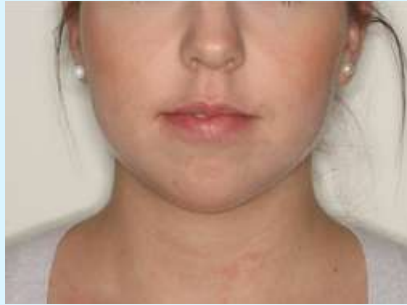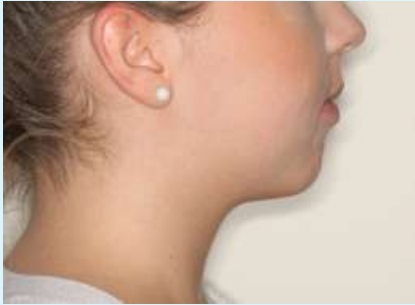2012-10 after KFO



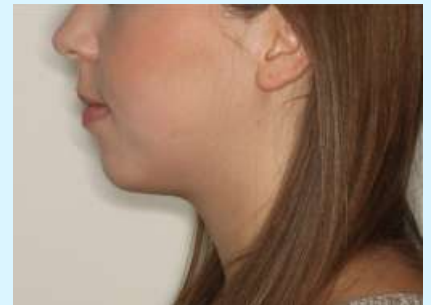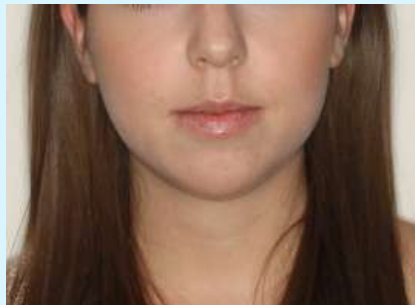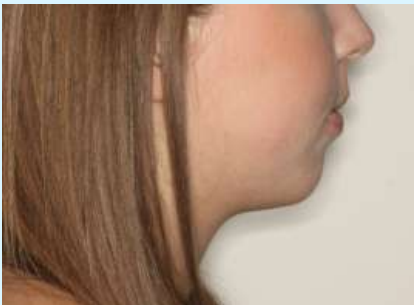# Satoretainer



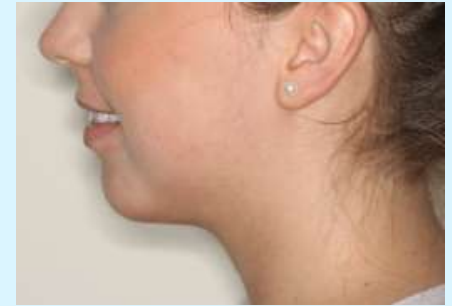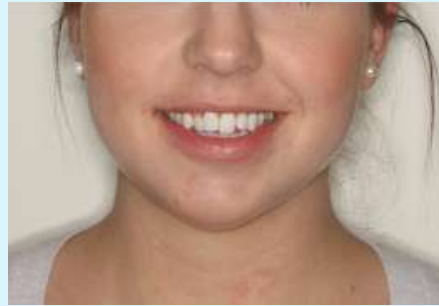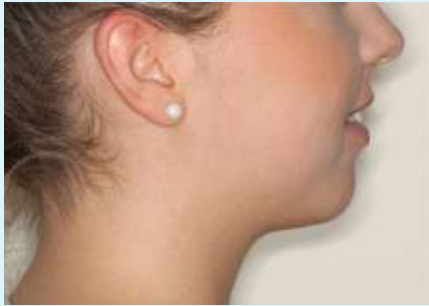2011-09 before KFO



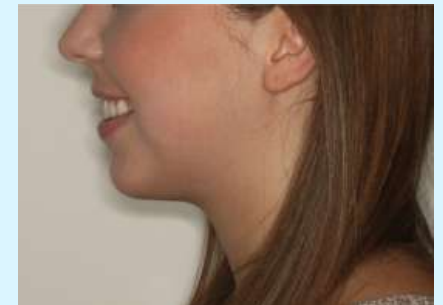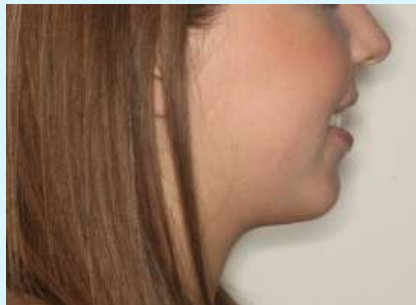2012-10 after KFO



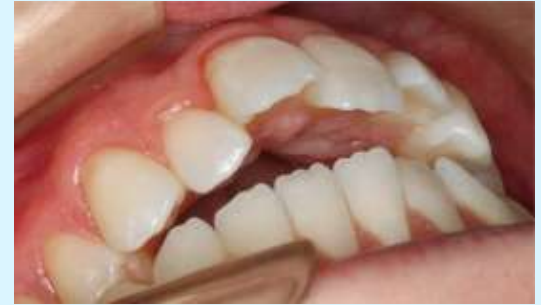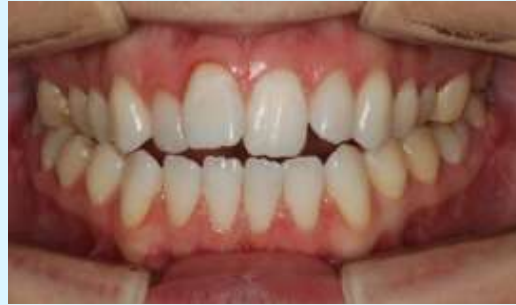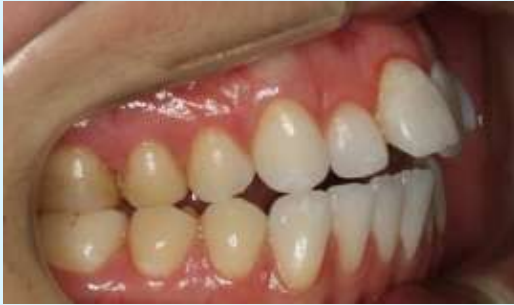2011-09 before KFO



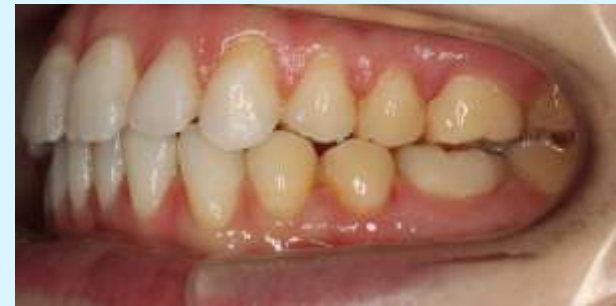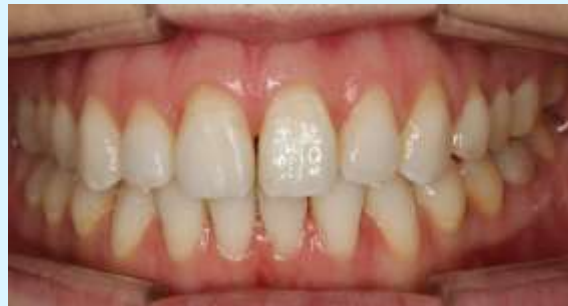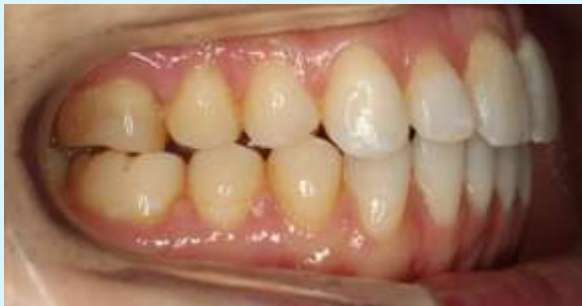2012-10 after KFO



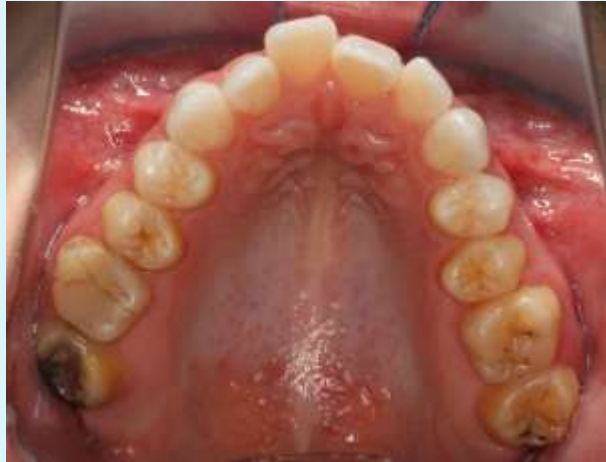2011-09 before KFO



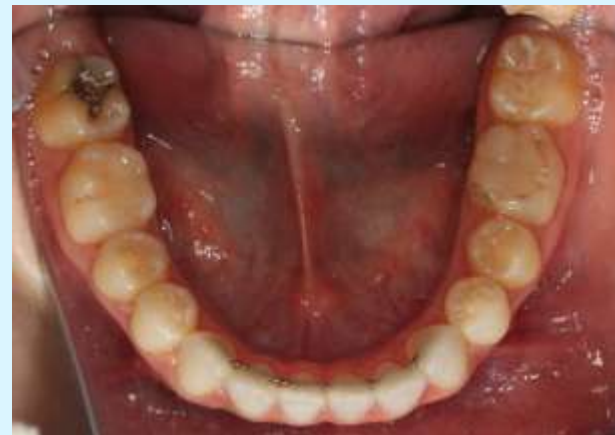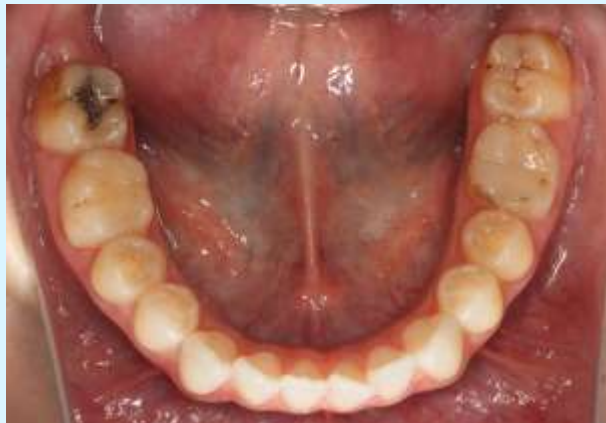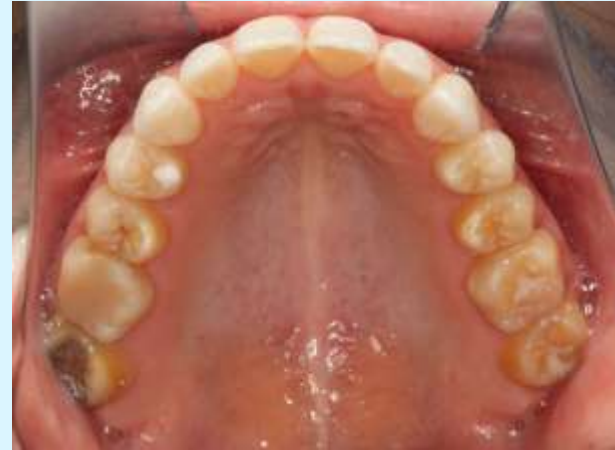2012-10 after KFO



2011-09 before KFO



2012-10 after KFO

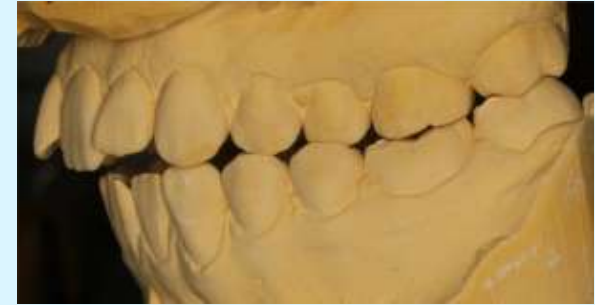
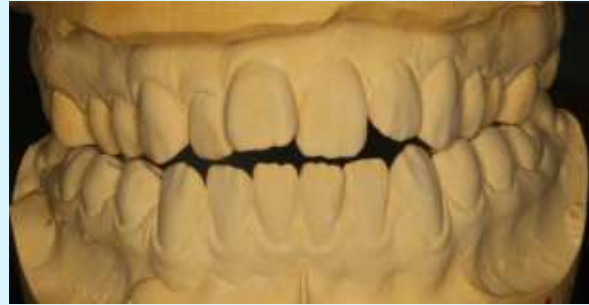
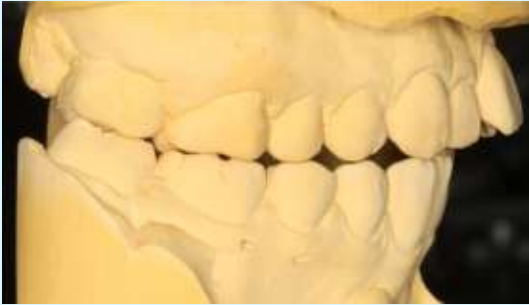16

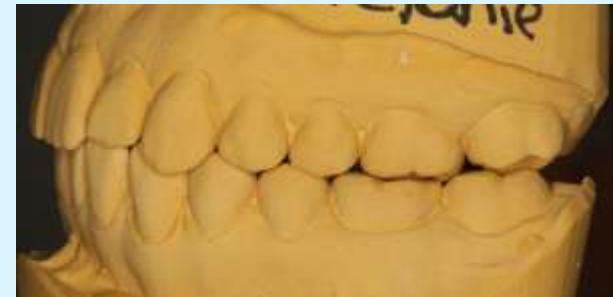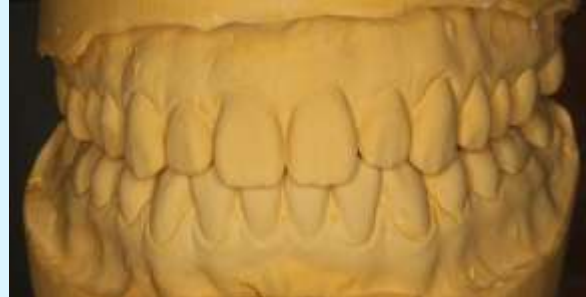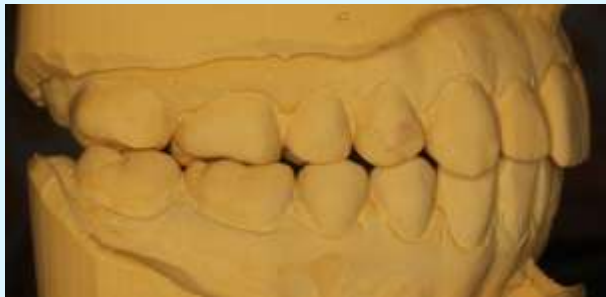16



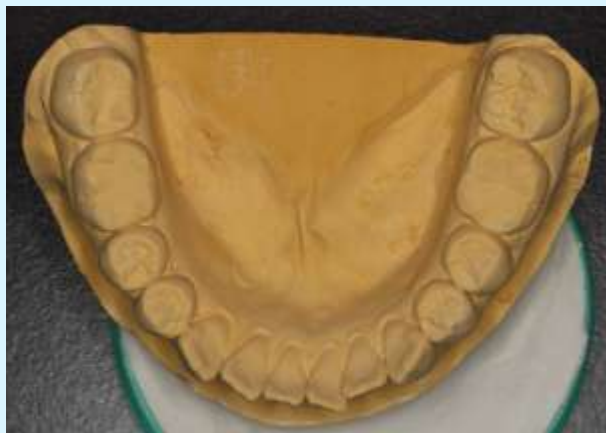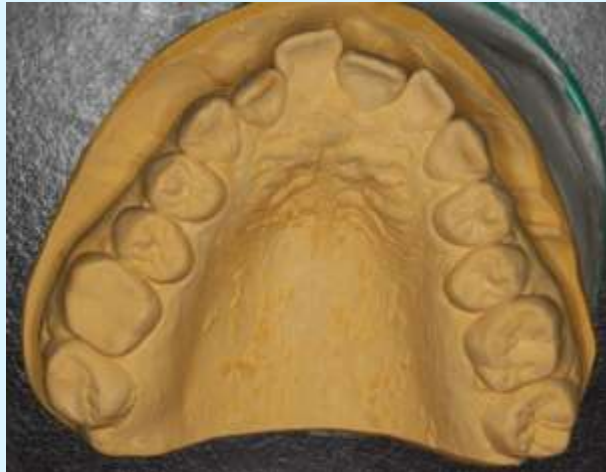
2011-09 before KFO



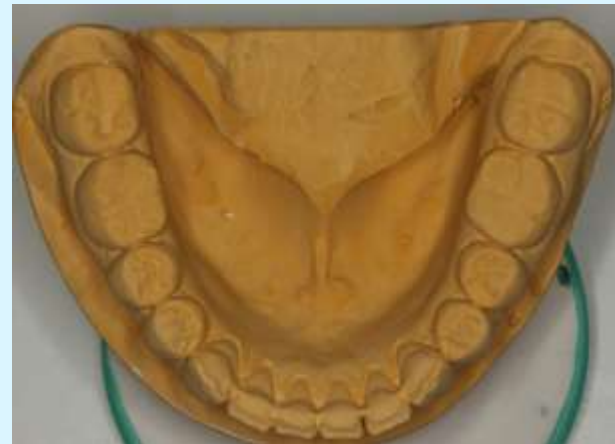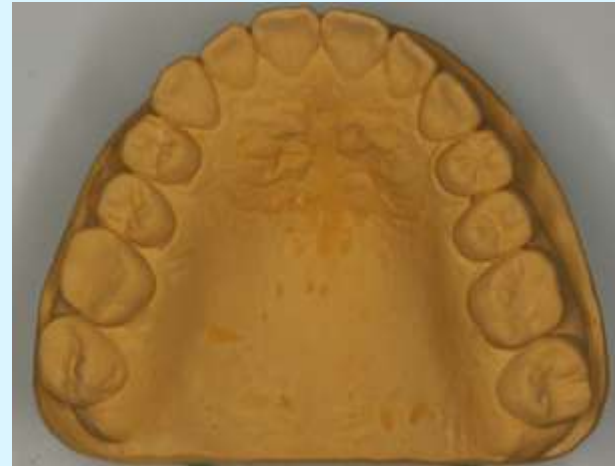2012-10 after KFO



2011-09 before KFO

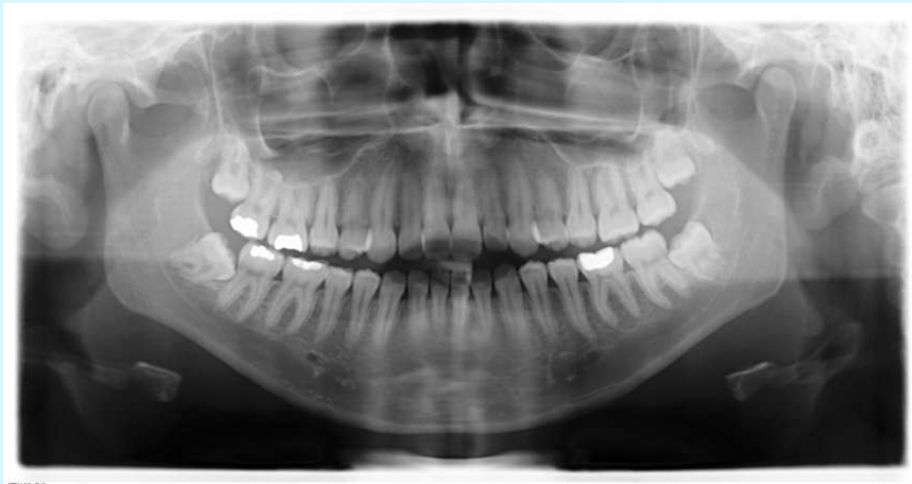


2012-10 after KFO

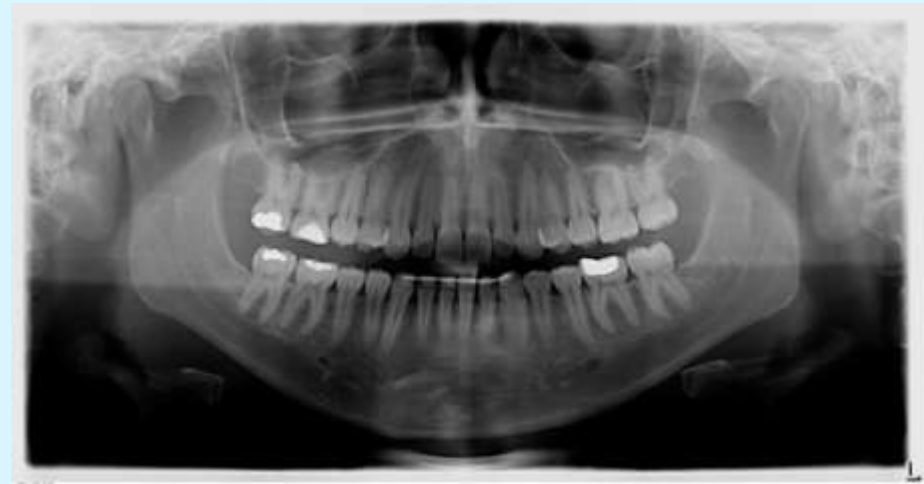

18

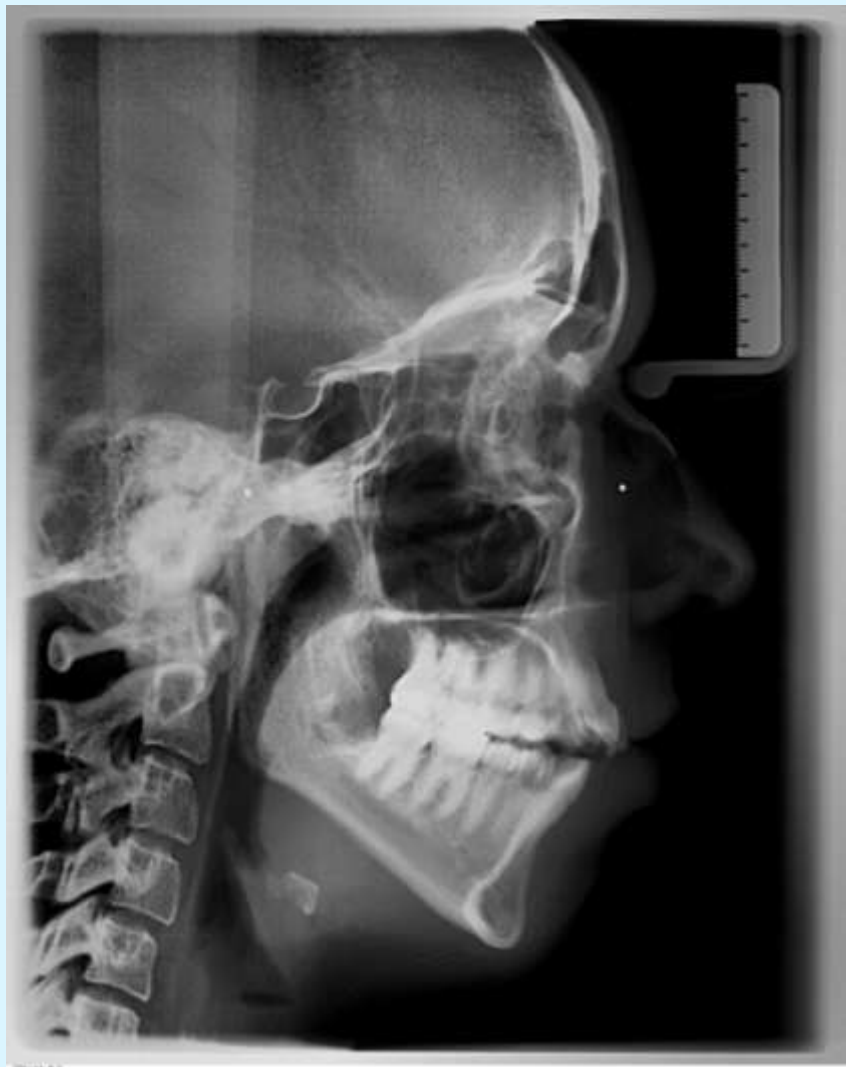18



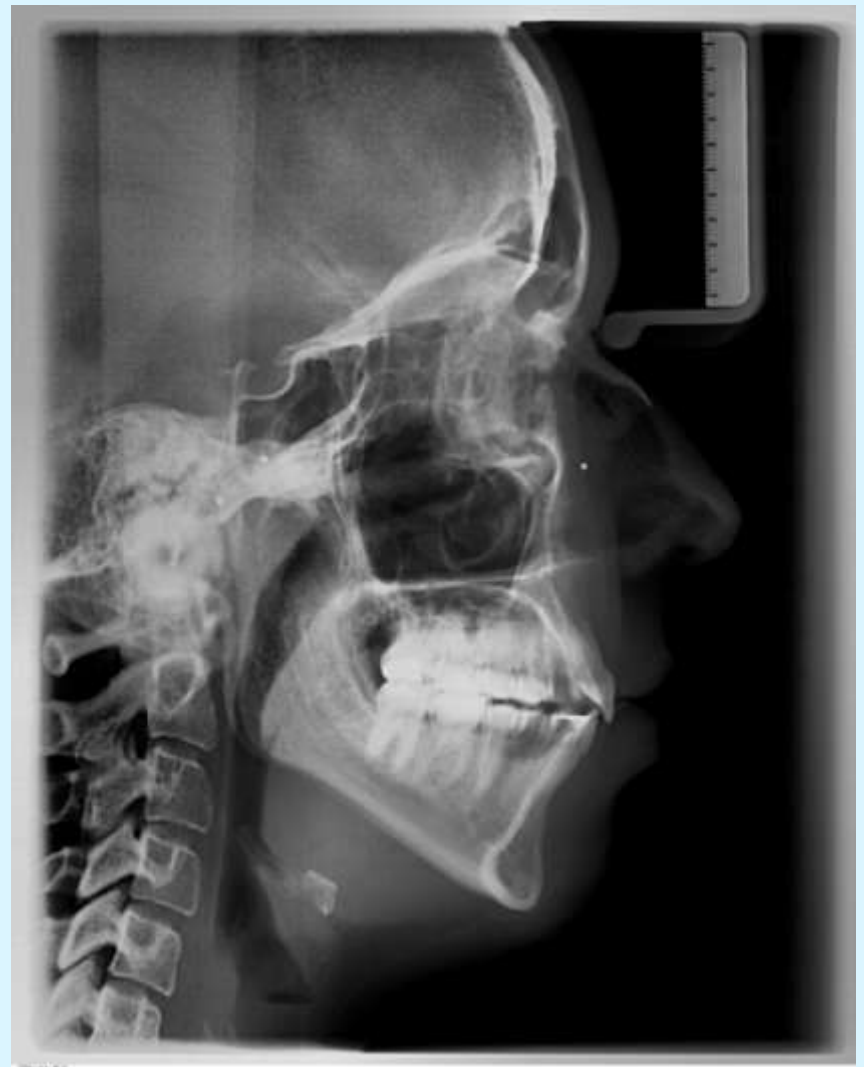2011-07 before KFO



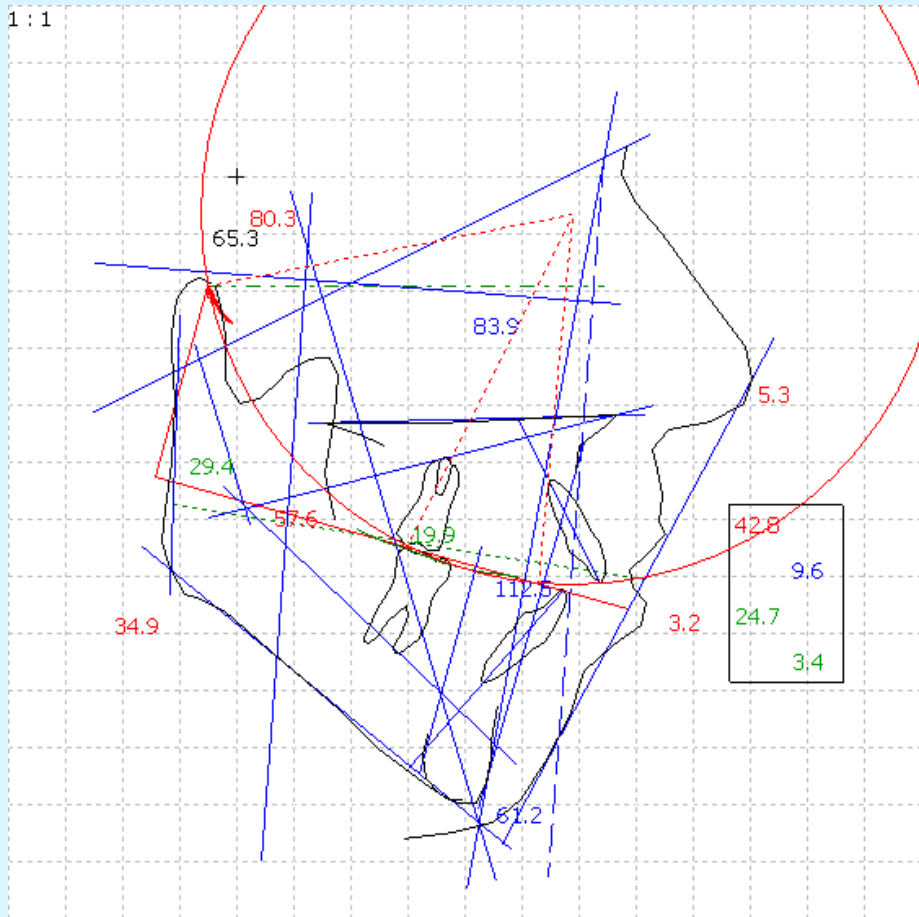
2014-02 after KFO



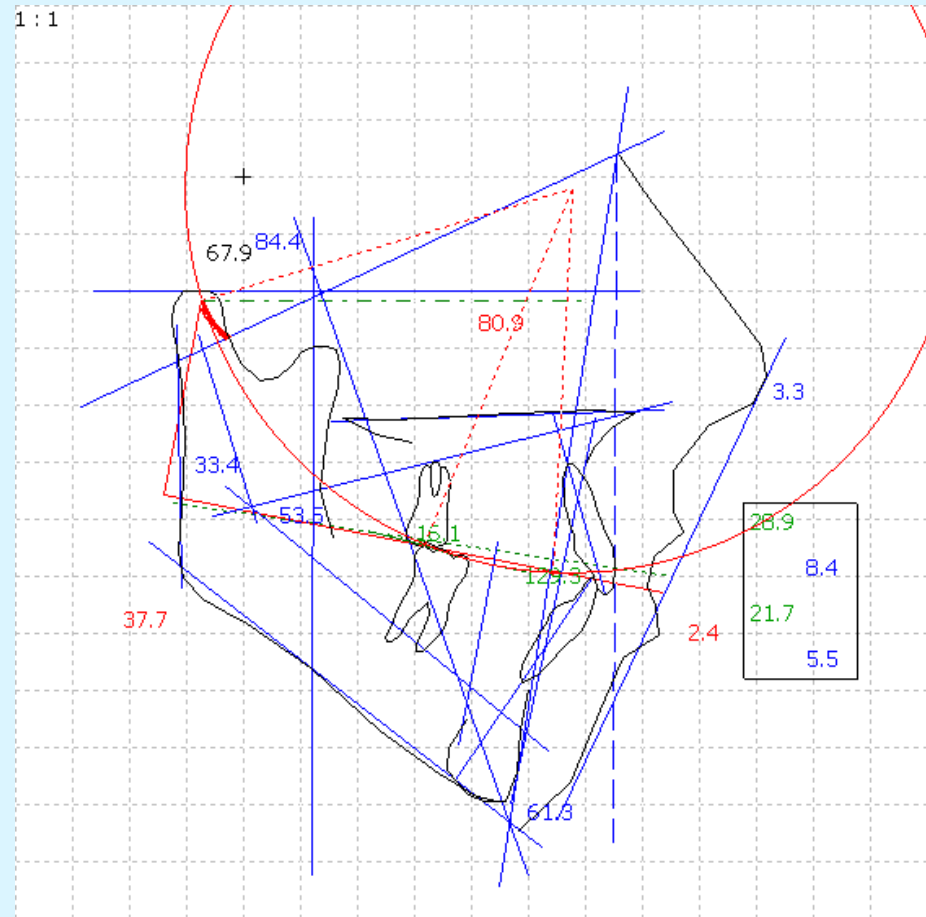
2011-09 before KFO



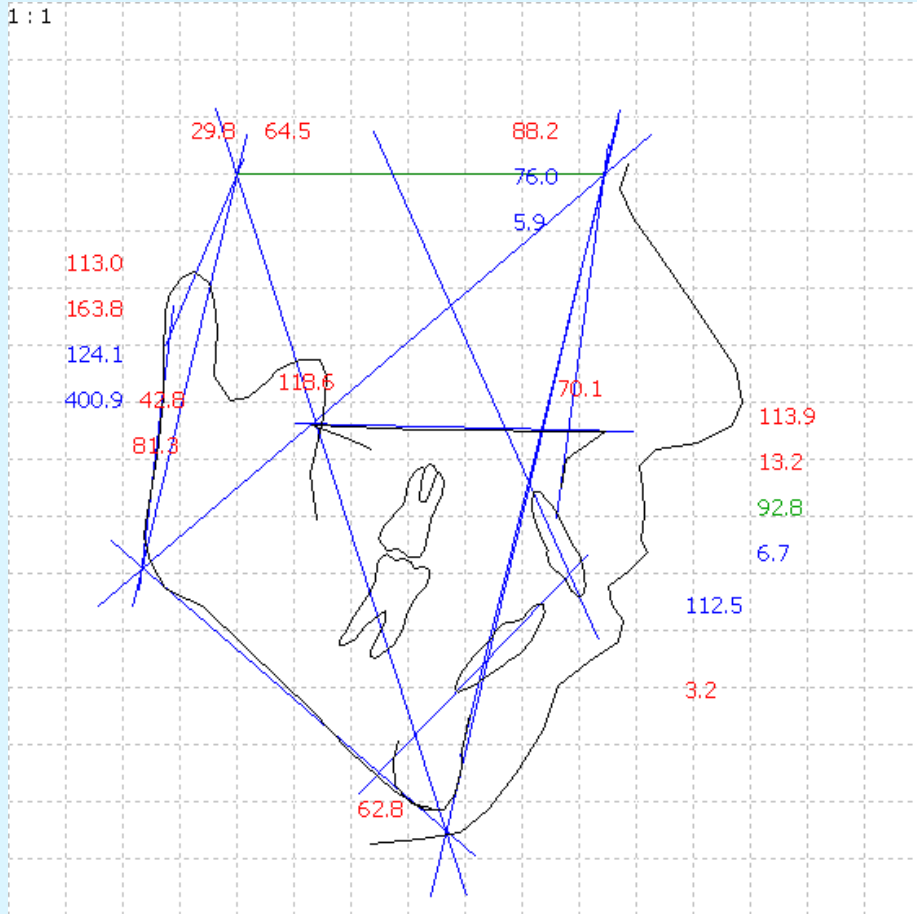
2013-02 after KFO



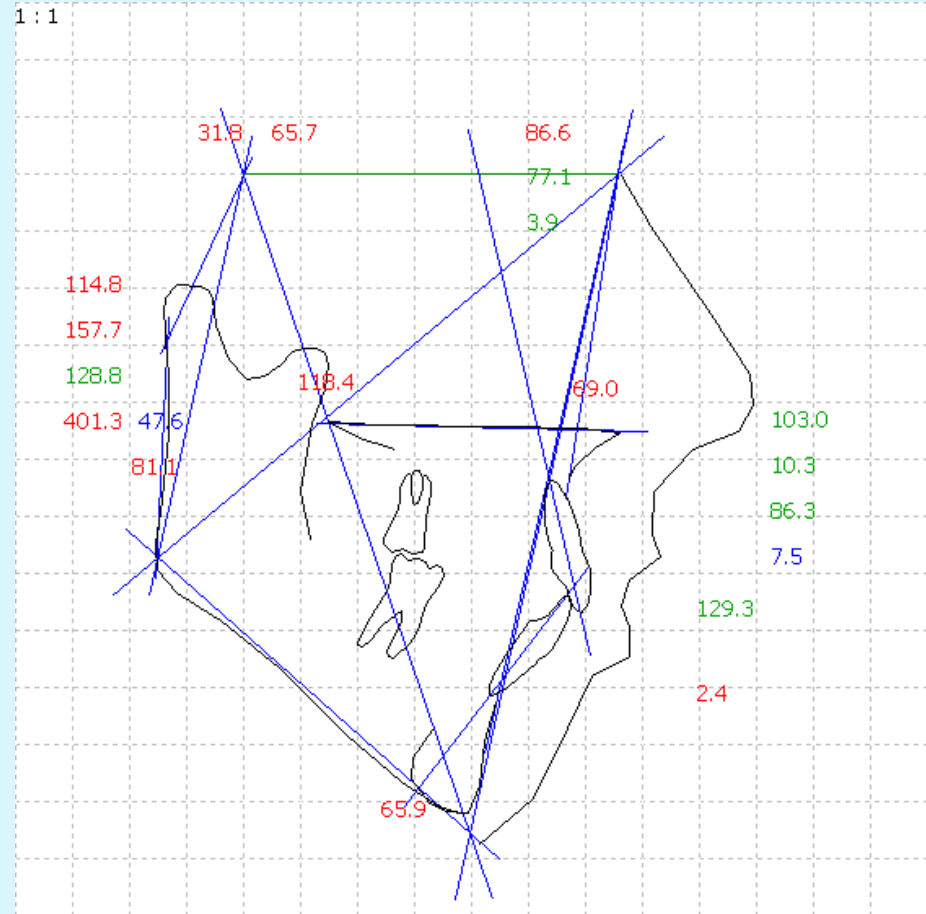
2011-09 before KFO



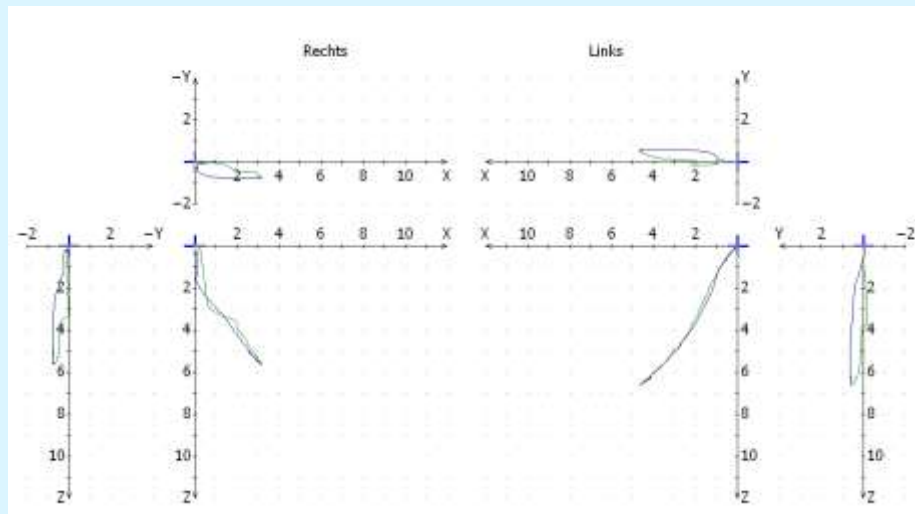
2013-02 after KFO



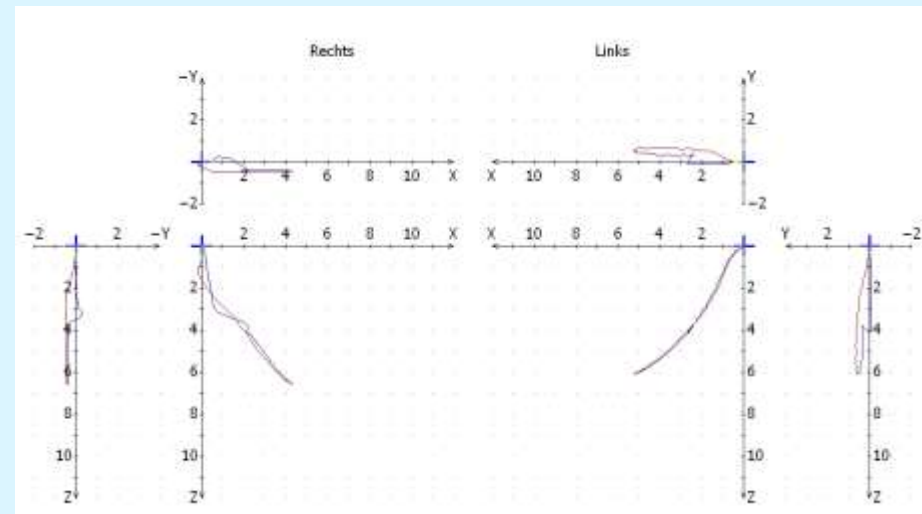
2011-09 before KFO



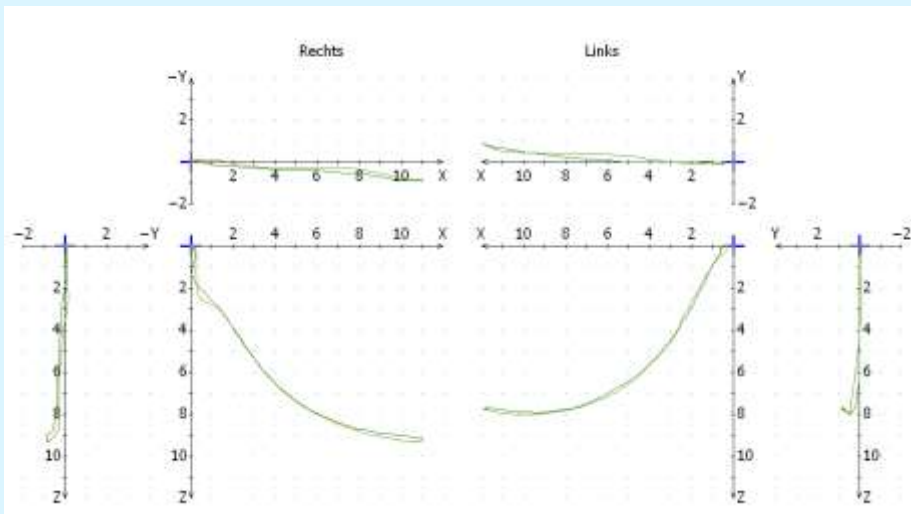
2013-02 after KFO



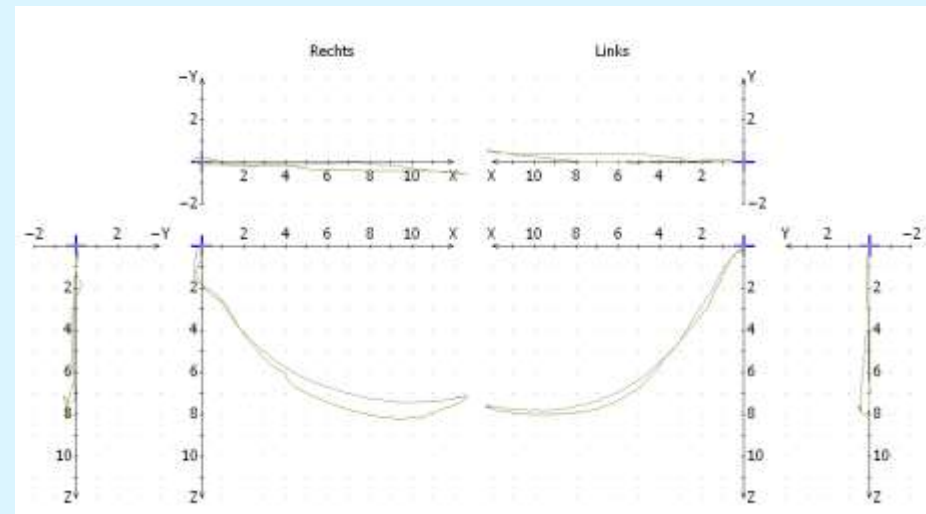
2011-09 before KFO-  
pro/retro



2013-02 after KFO –  
po/retr.-Click re.!



2011-09-before KFO –  
open/close



2013-02 after KFO-  
open/close-Click re.



# Curriculum

- Mastication much better now!!
- Still sl.TMJ-clicking re.-note axio-data before and after KFO
- 2011-09→begin of fixed KFO
- 2012-10→end of KFO(debracketing)
- Bracketing-time 1a 1mo!
- Retention w. Satoretainer in UA and clearfolie and fixed retainer from 33 to 43