

Nr. 3435 16 Jahre weibl.

KL II/2

Diagnosis

- Wisdoms are still ex→2a ago by Dr. Grabher L.
- Dentoalv.full CL II/2
- Very steep 11/21
- Overbite on 11/21→2mm
- Steep occl. Plane on lower second molars
- Lyraform of upper arch
- Crowding in upper front

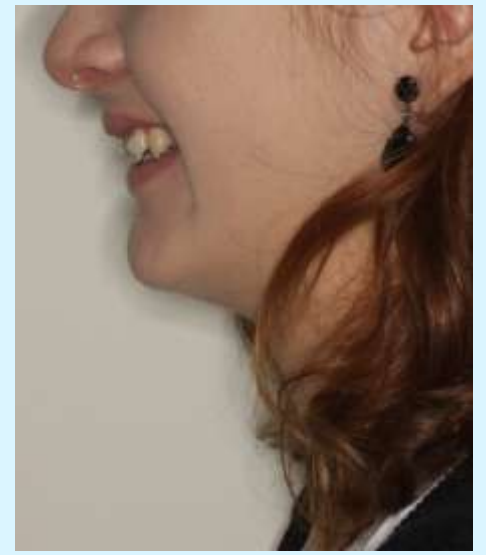
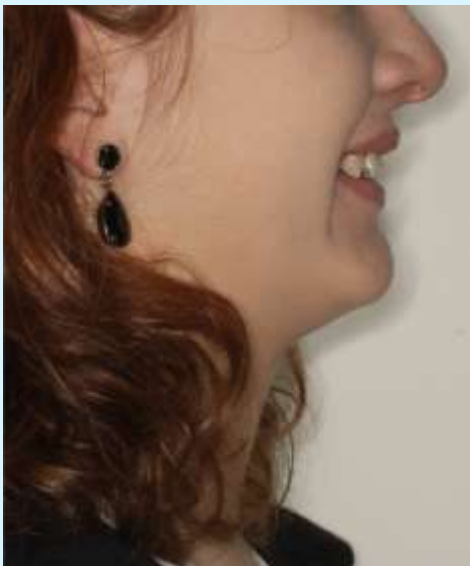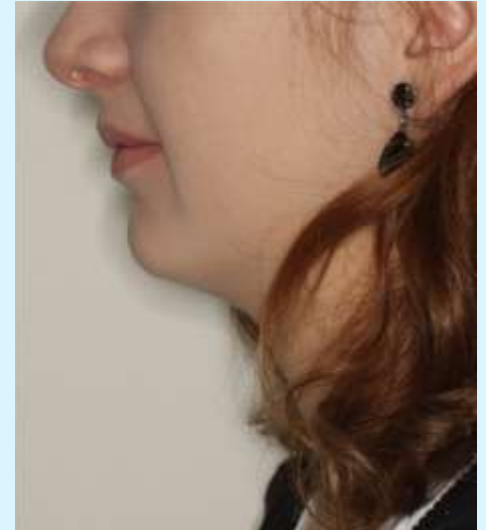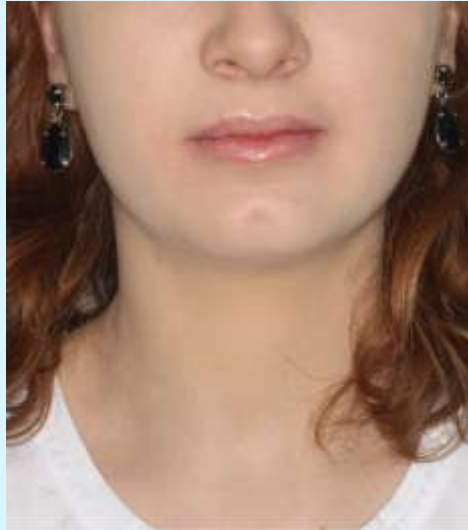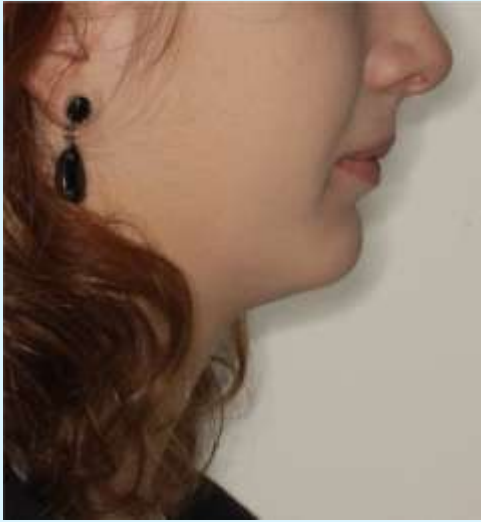Treatment Plan

- Enlargement of upper ant. arch
- Protrusion of 11/22
- Correction of CL II/2 → reconstruction of the post. occl.,. plane
- Verticalisation

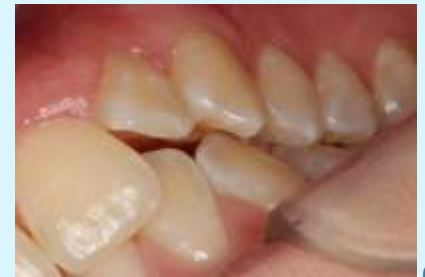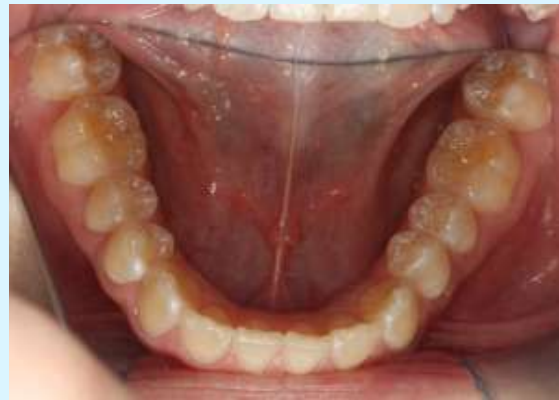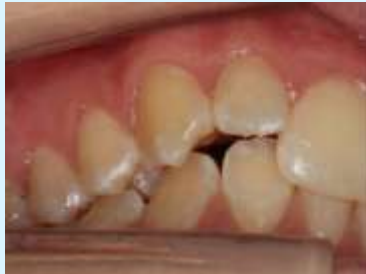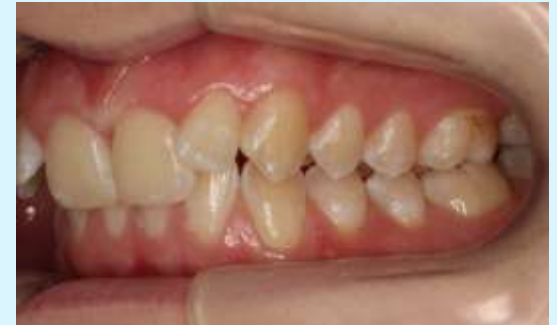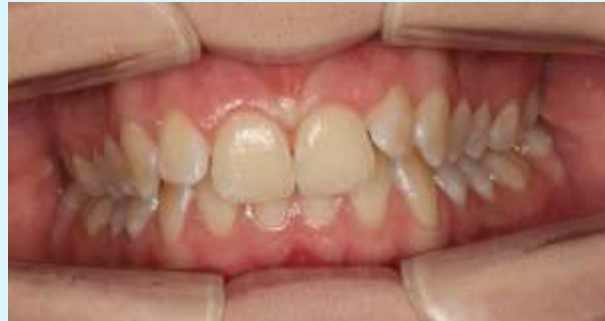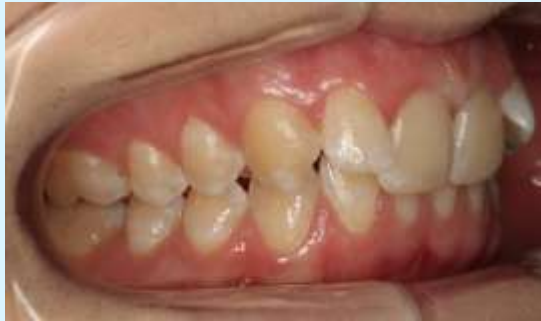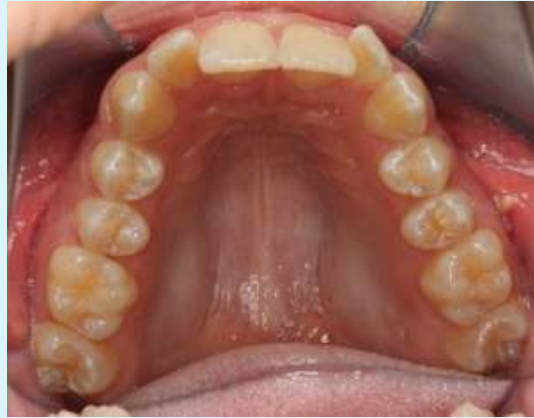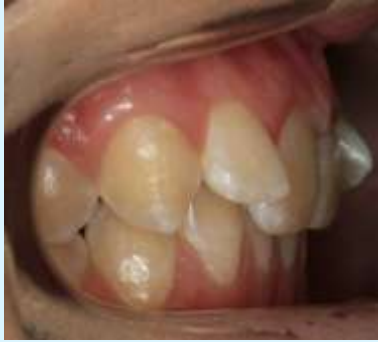Chief Complaint

- Aesthetically → Upper front only!!

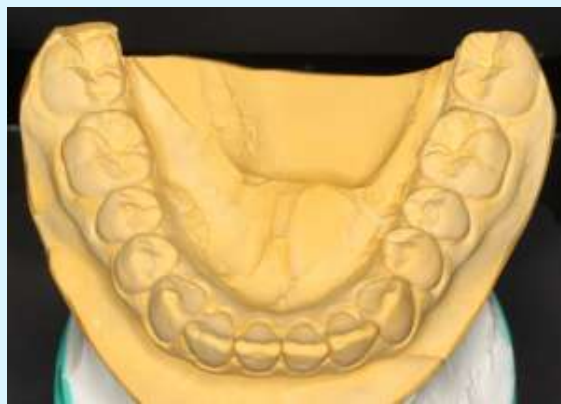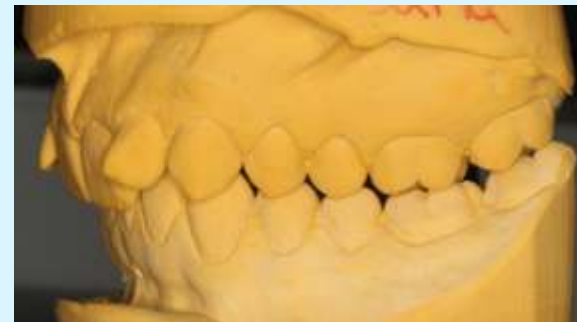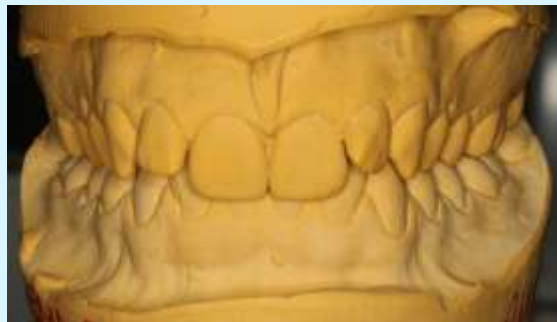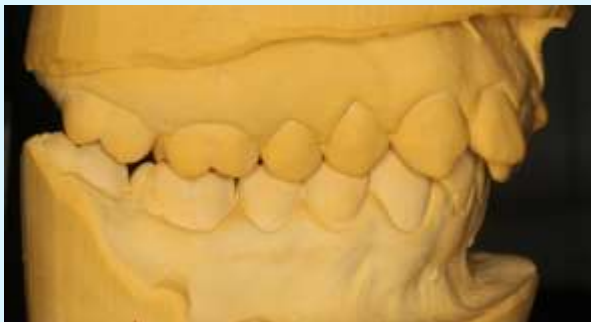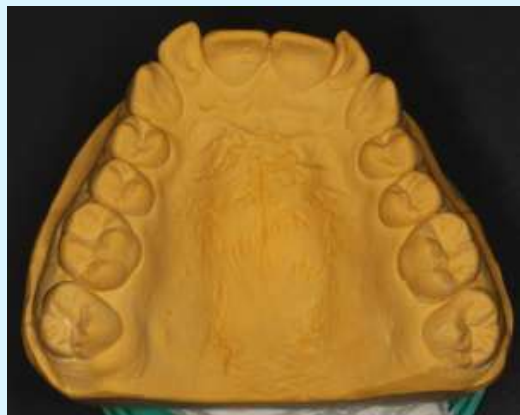Before KFO 2012-03-01 → only aesthetic problem with the front!!



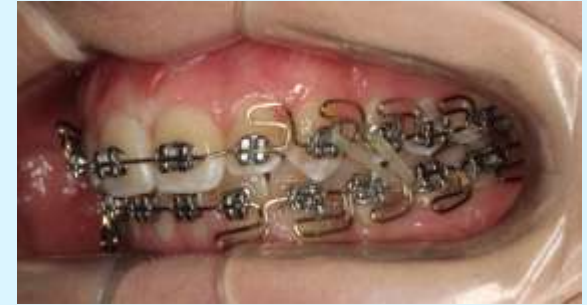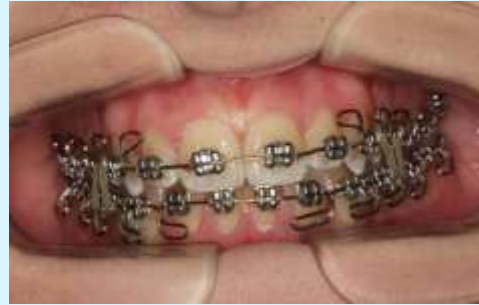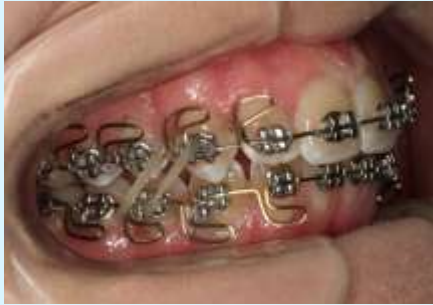before KFO 2012-03-01



Before KFO 2012-03-01



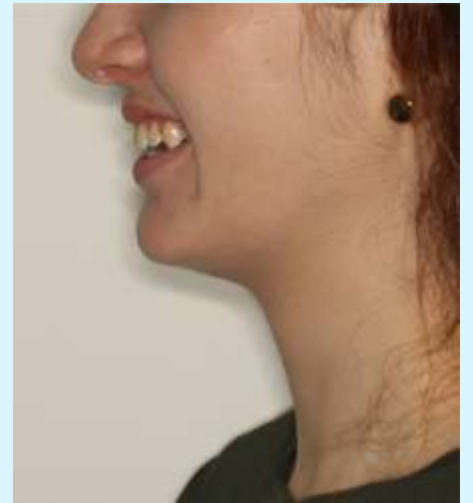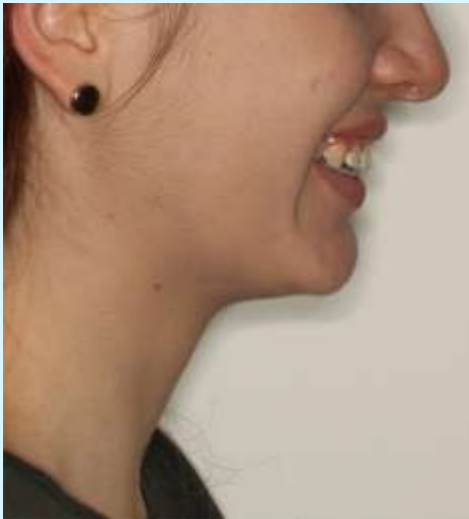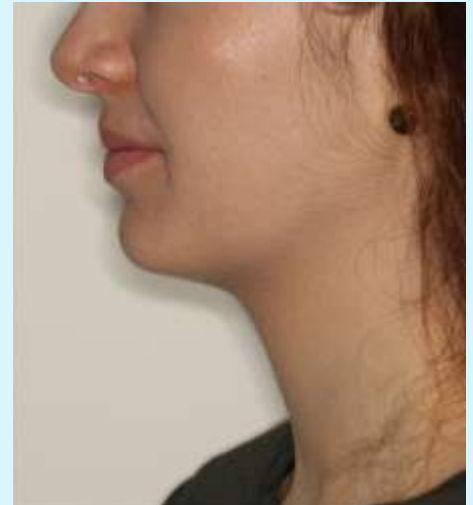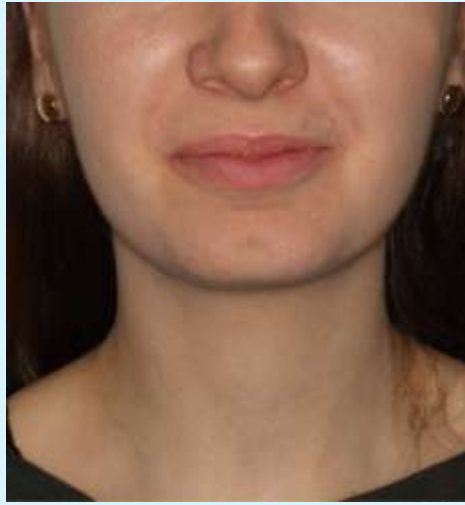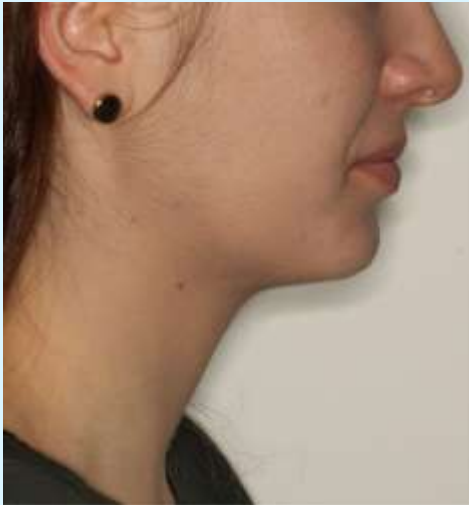During the treatment- 2012-06-26



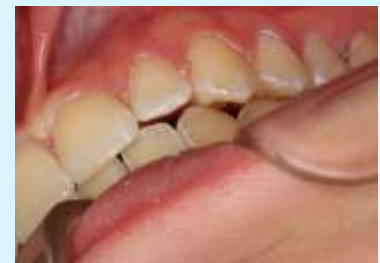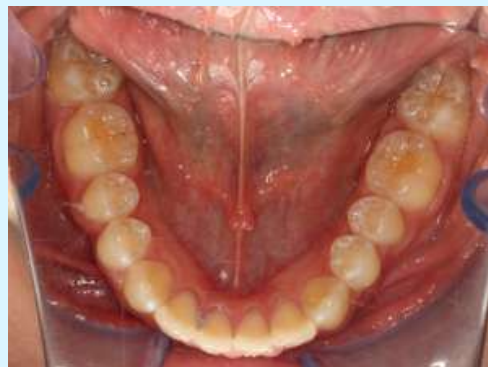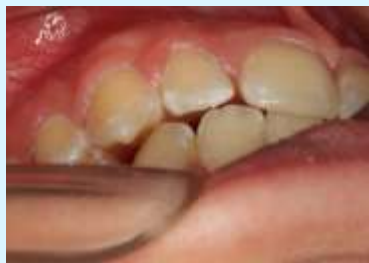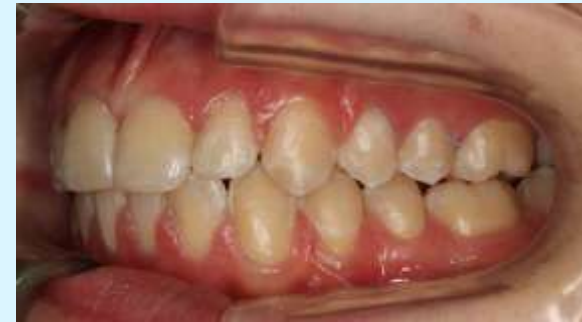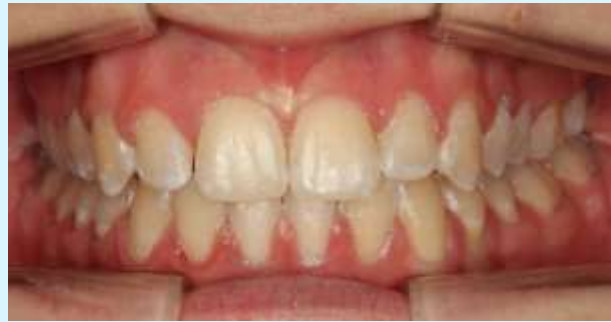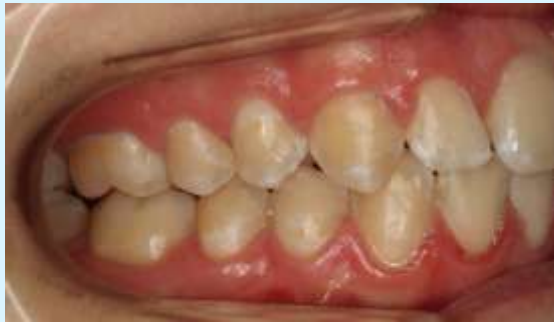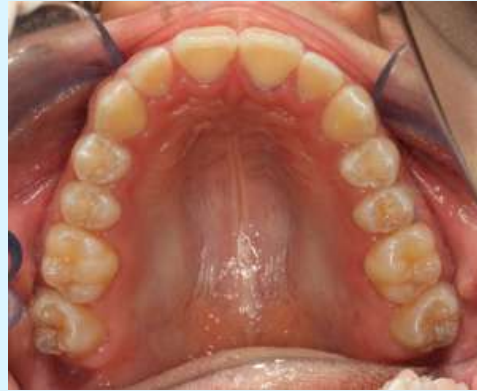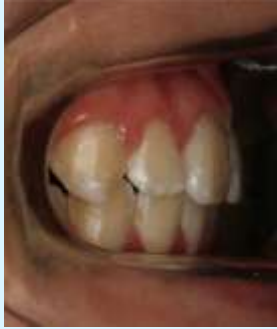MEAW Bogen



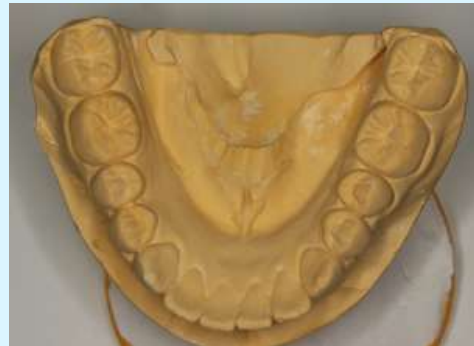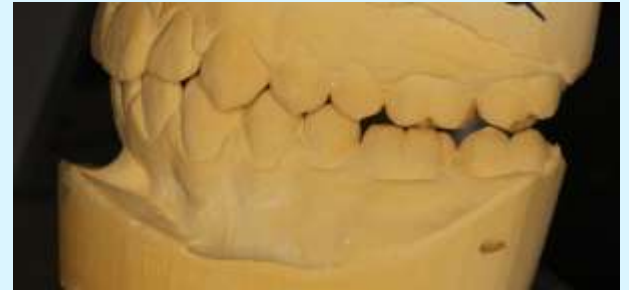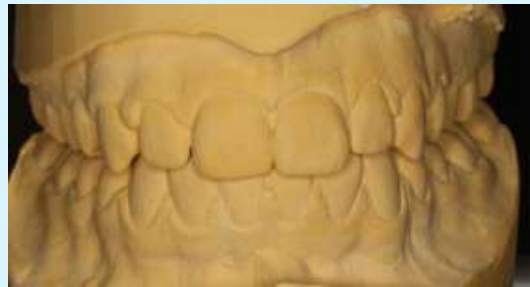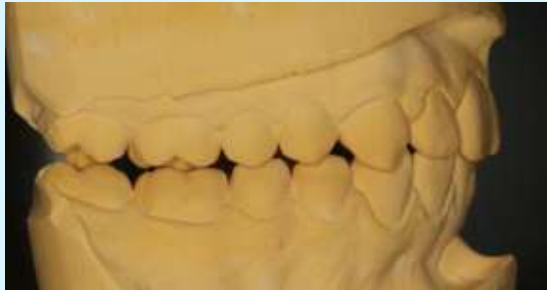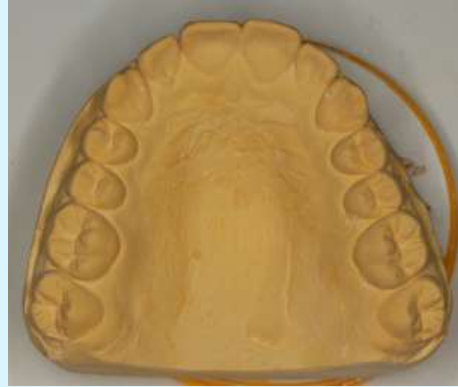Nach KFO 2013-10-10



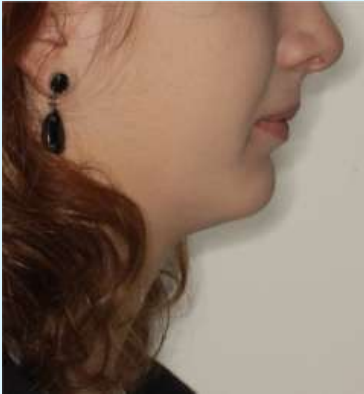After KFO 2013-10-10



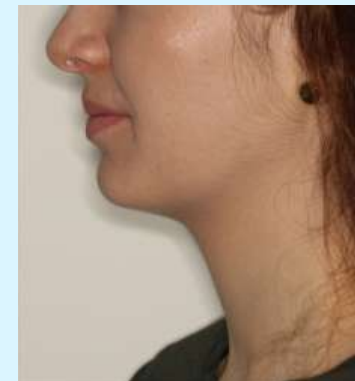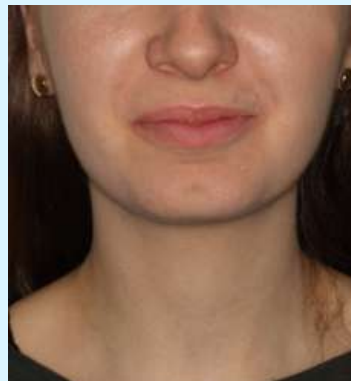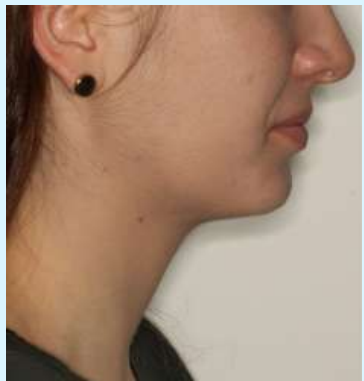After KFO 2013-10-10



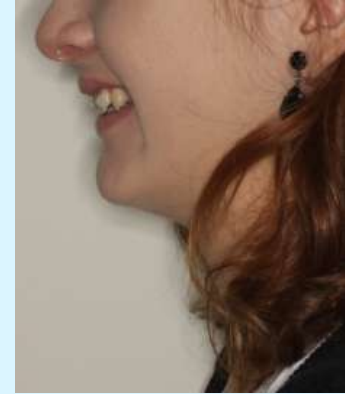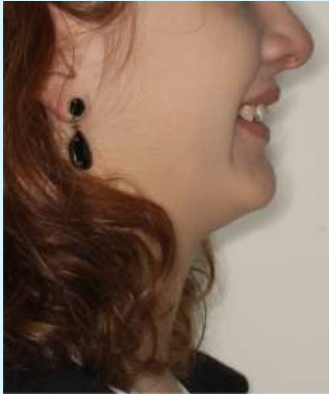Before KFO 2012-03-01 → note the advancement of the mandible!!! and the verticalisation



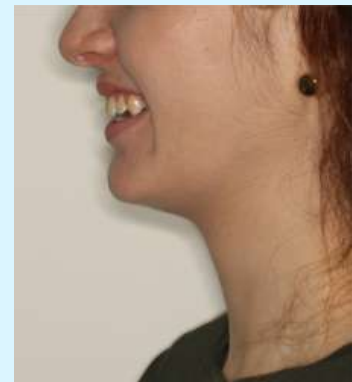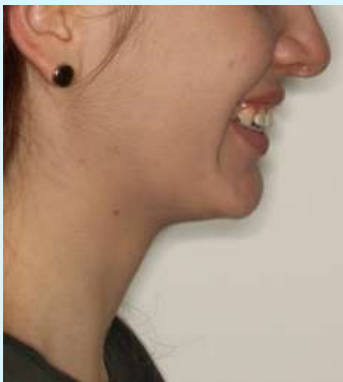After KFO 2013-10-10



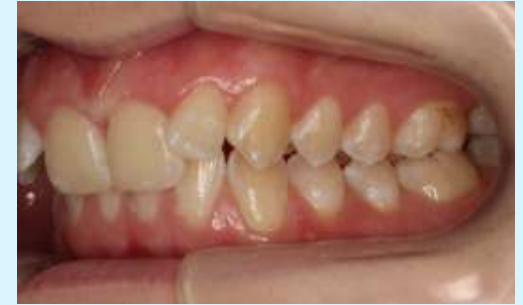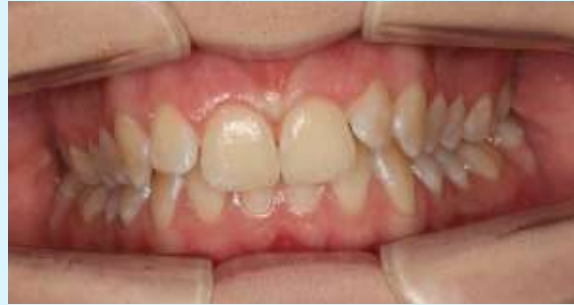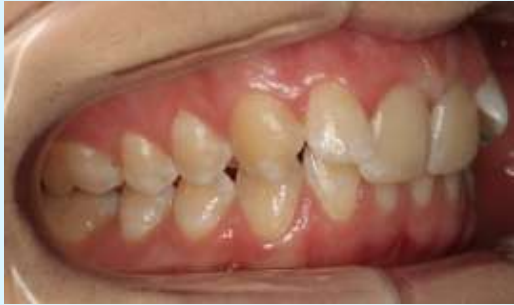Before- KFO 2012-03-01



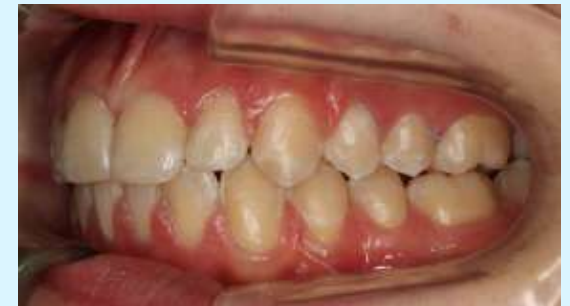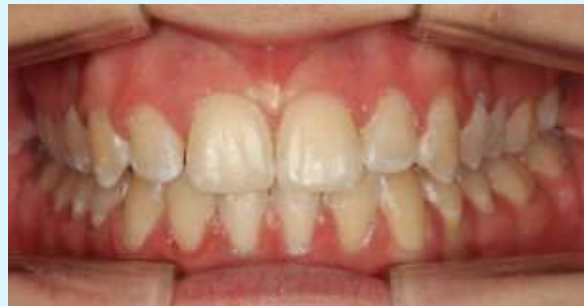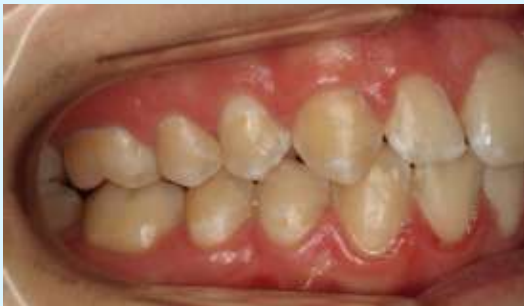After- KFO 2013-10-10



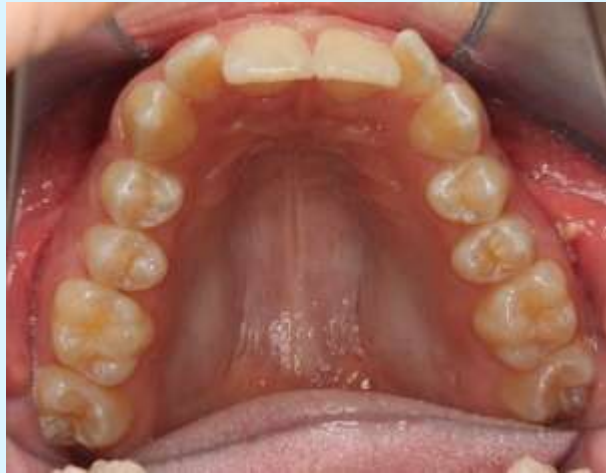Before- KFO 2012-03-01



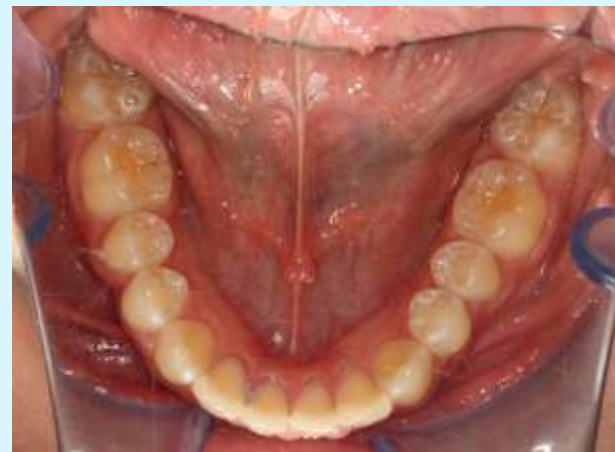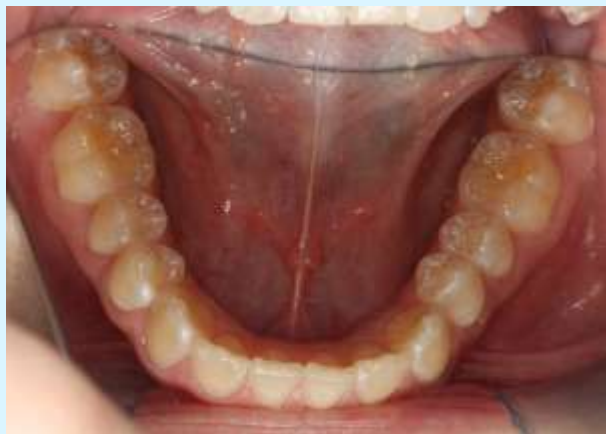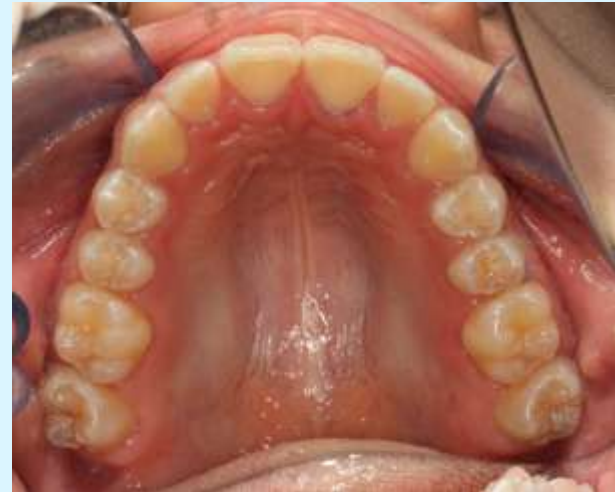After- KFO 2013-10-10



Before- KFO 2012-03-01



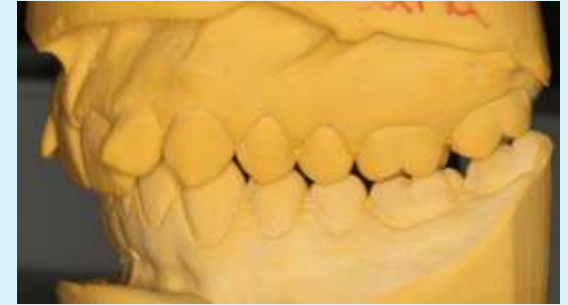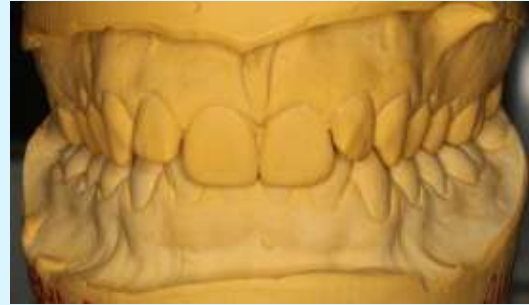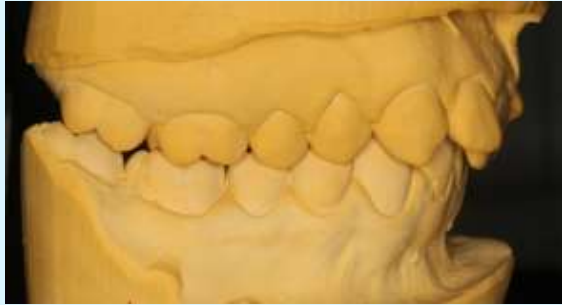After- KFO 2013-10-10



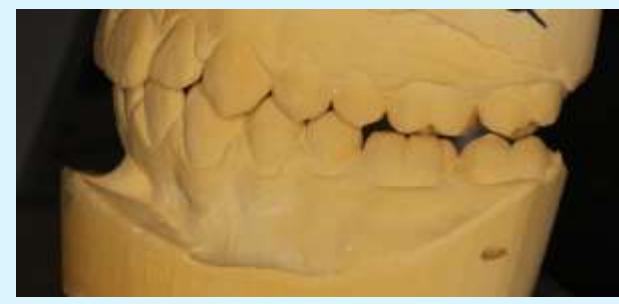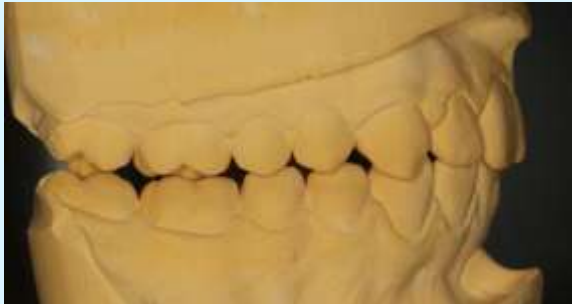15

15

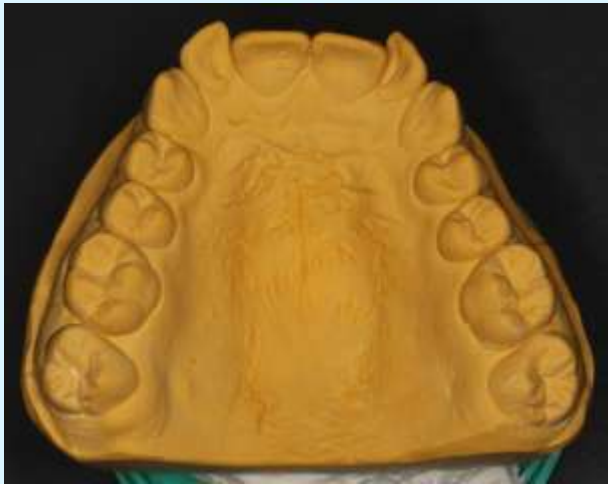
Before- KFO 2012-03-01



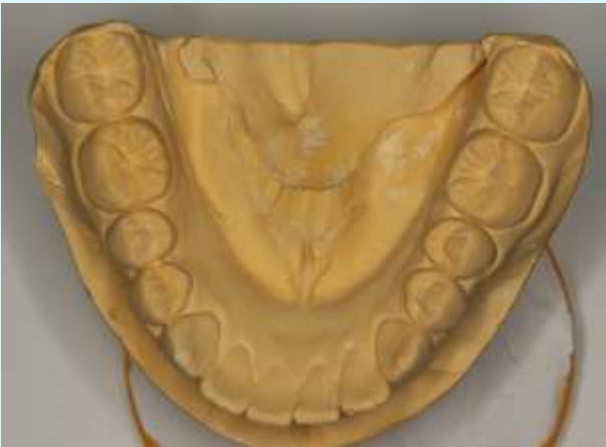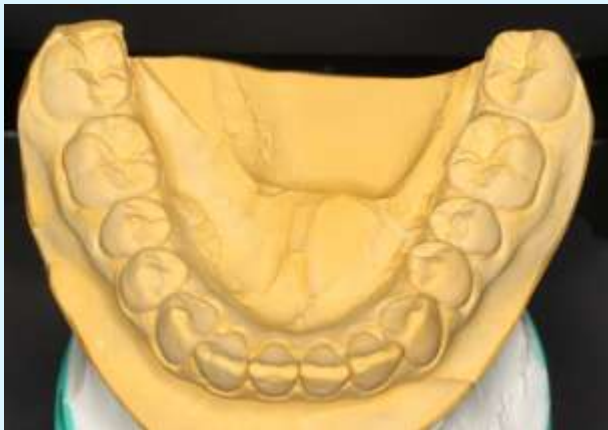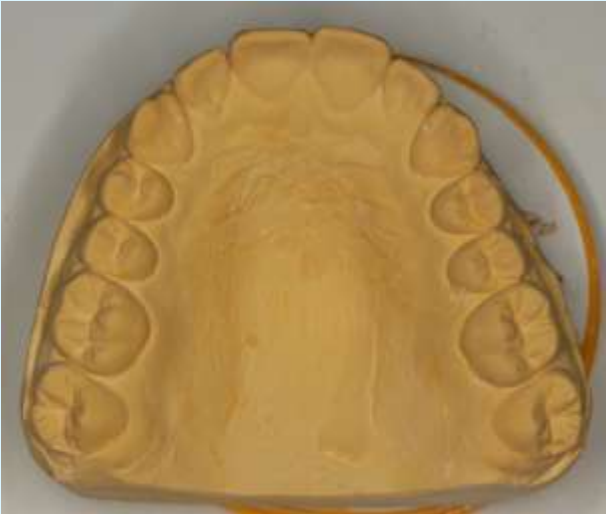After- KFO 2013-10-10



Before- KFO 2012-03-01



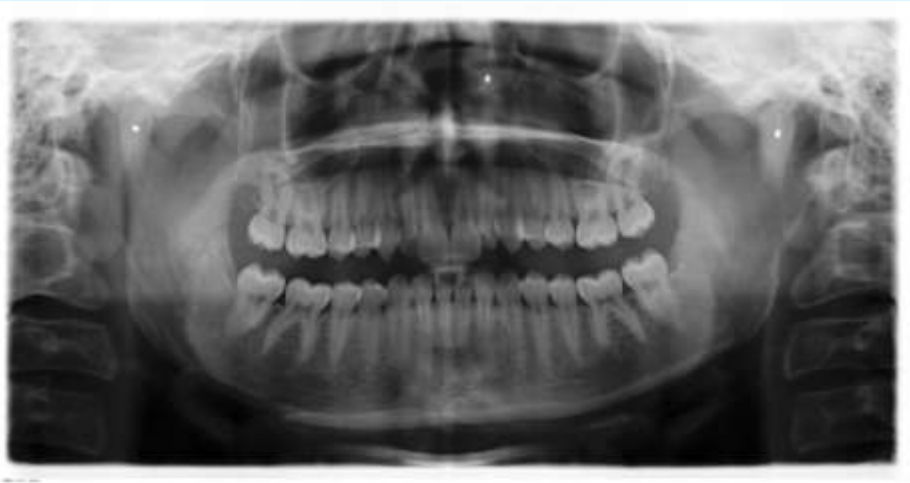After- KFO 2013-10-10



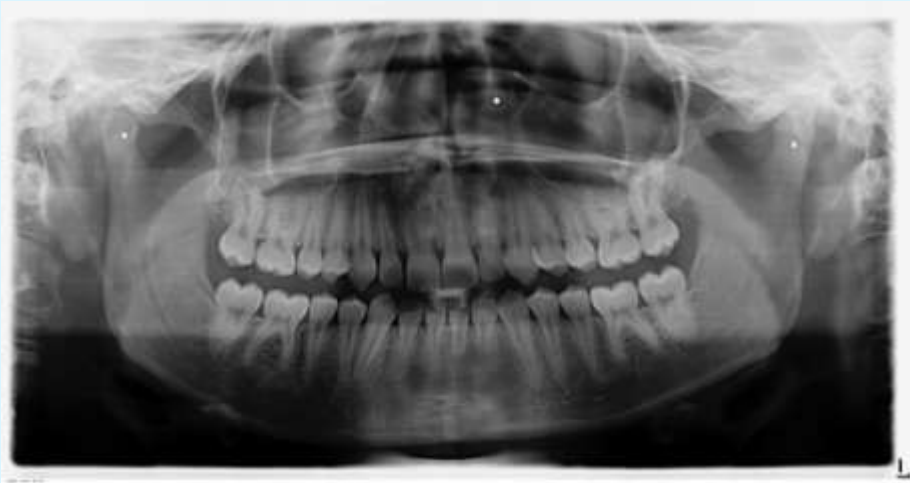17

17

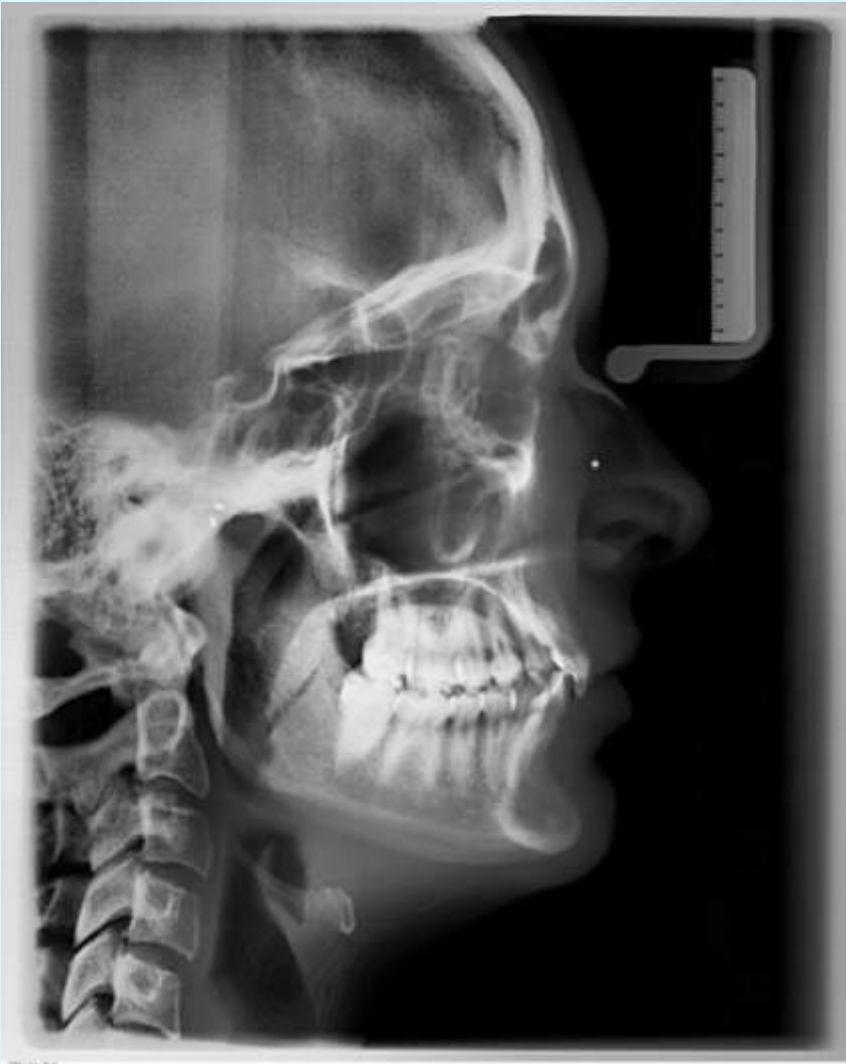Before- KFO 2012-03-01



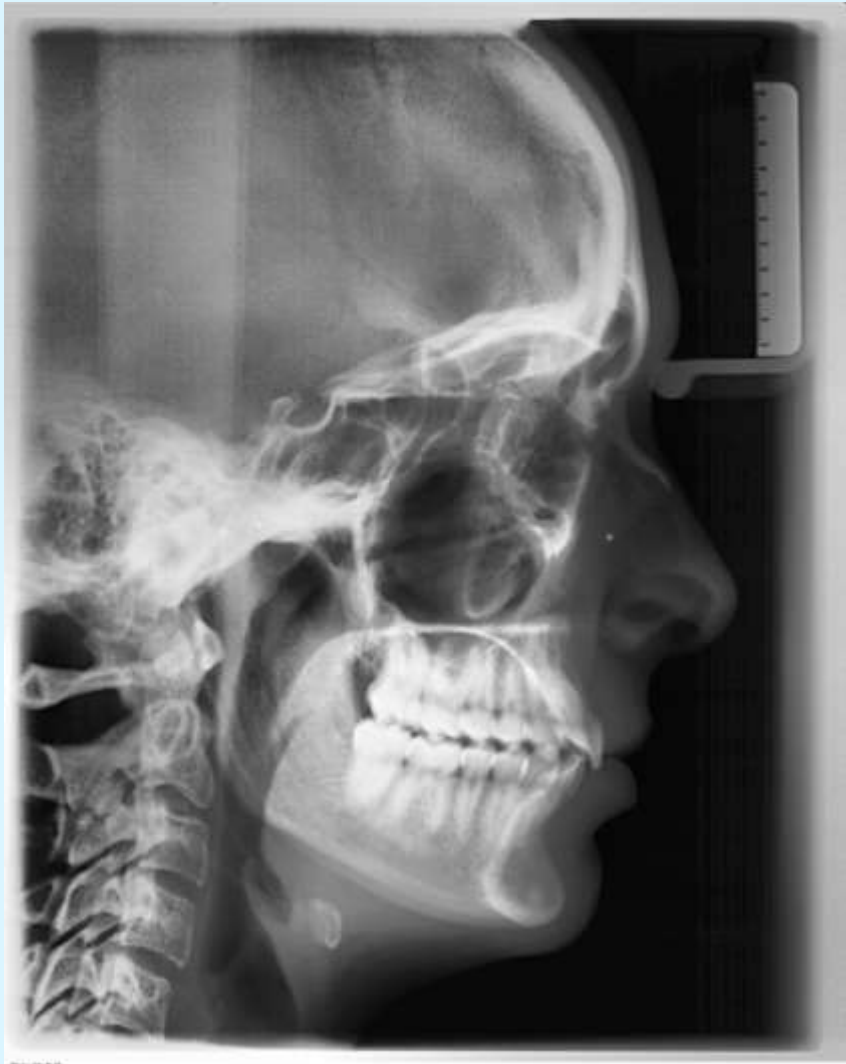After- KFO 2013-10-10



Before- KFO 2012-03-01

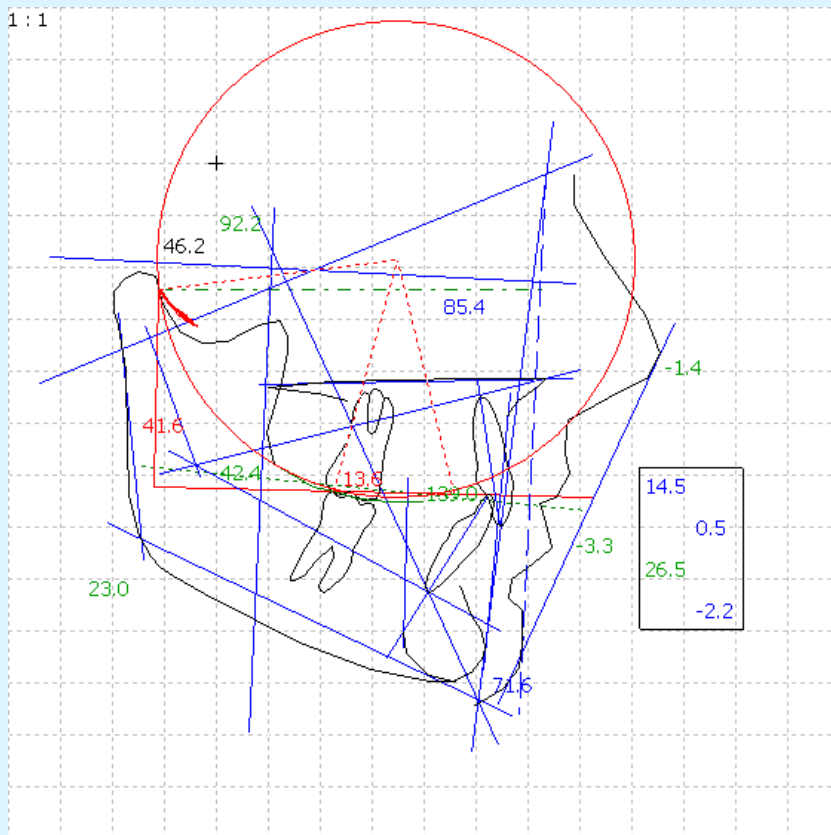


After- KFO 2013-10-10

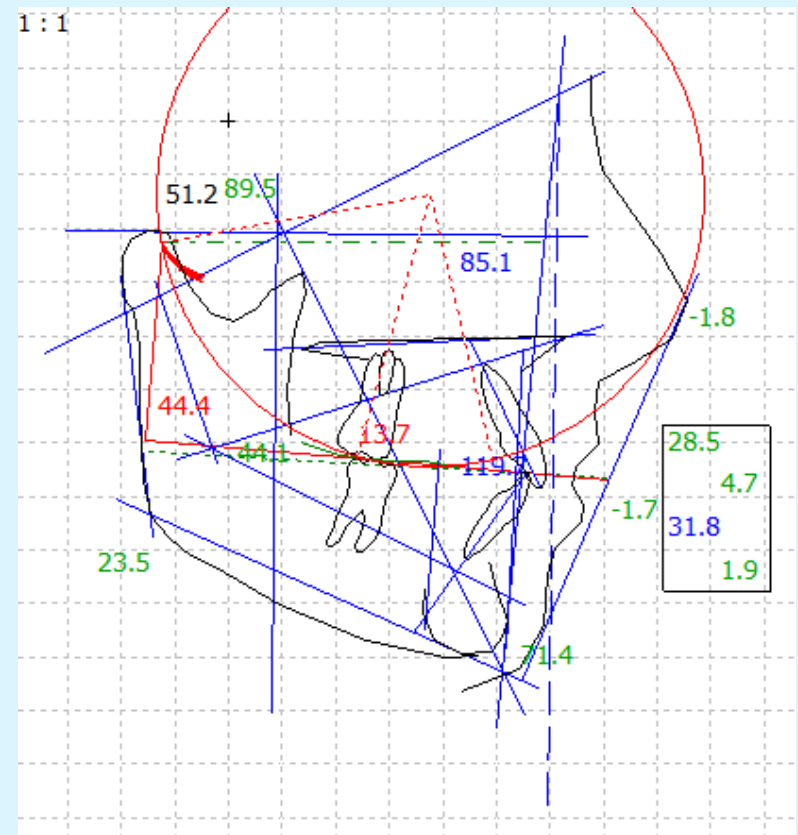


Slavicek trace → note the protrusion of upper front, verticalisation & advancement of the mandible!!

Before- KFO 2012-03-01

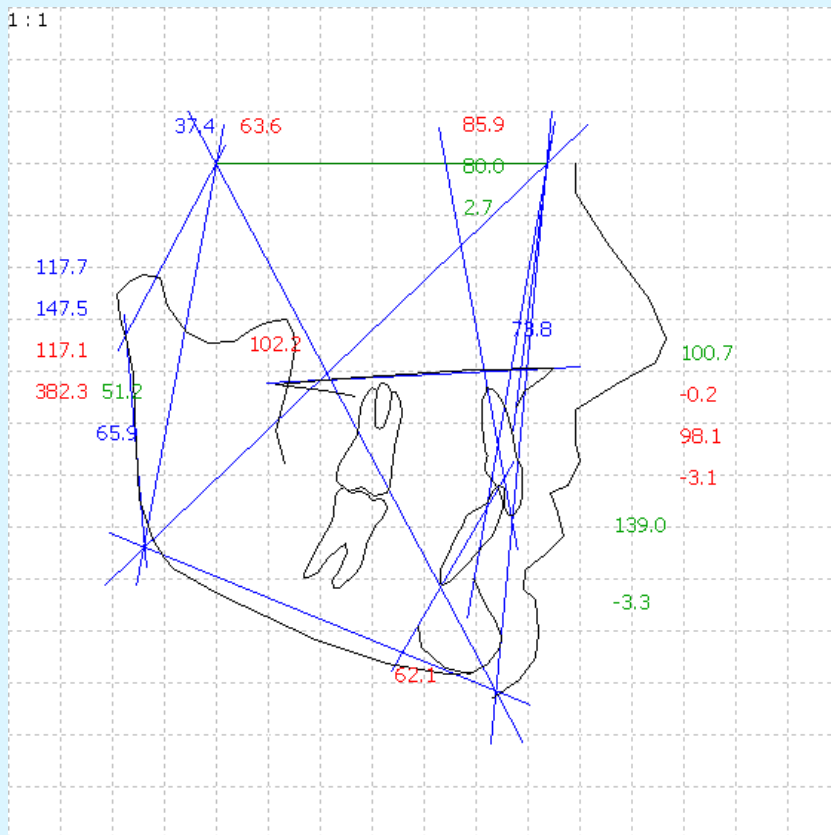


After- KFO 2013-10-10

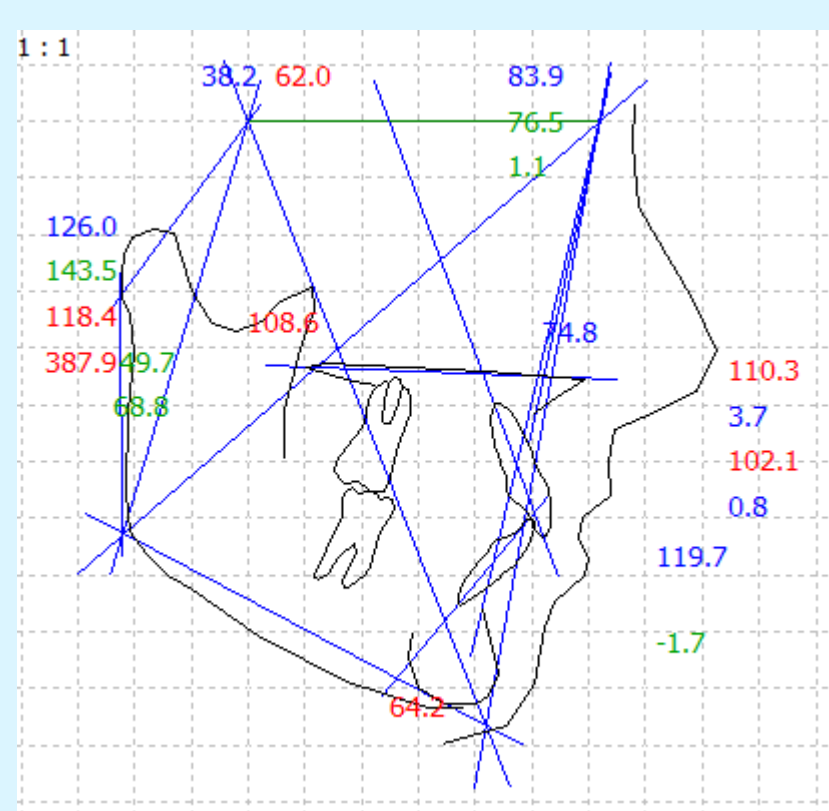


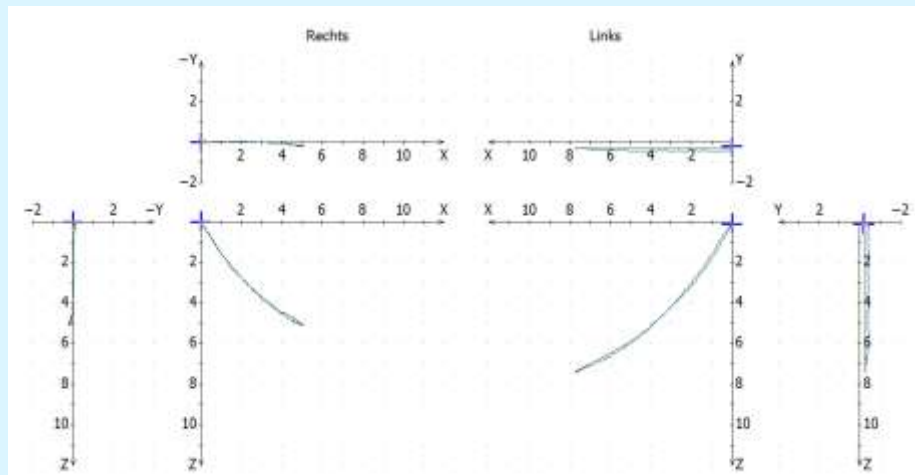
Jarabak Durchzeichnung

Vor KFO 2012-03-01

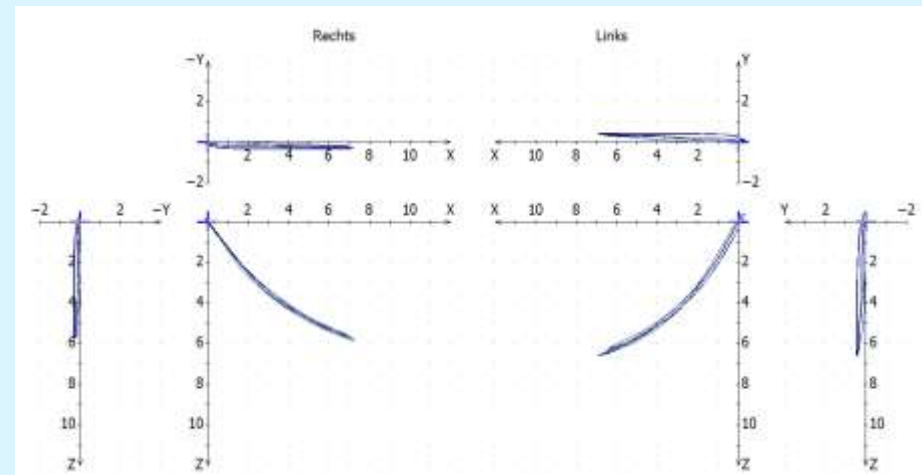


Nach KFO 2013-10-10

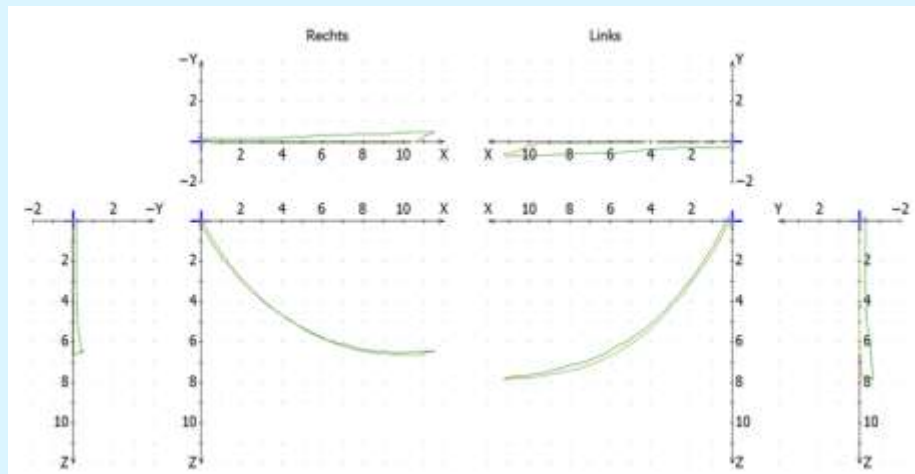




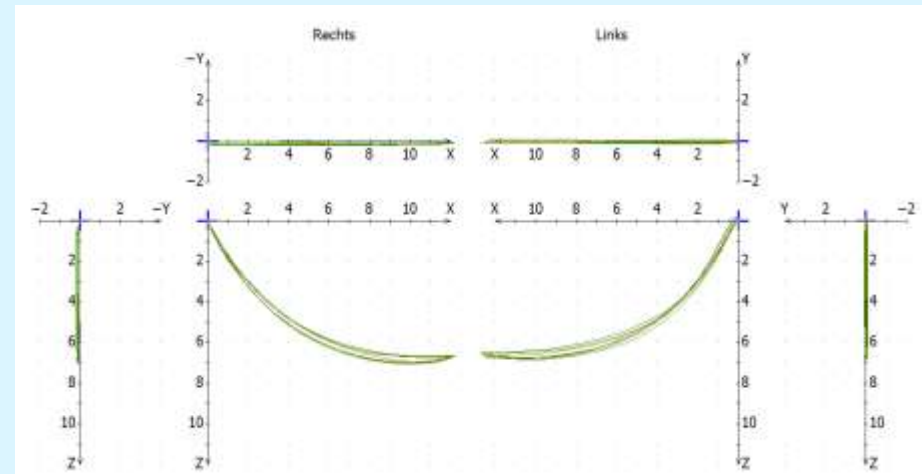
2012-03 pro/retr.- before
KFO-note light left shift




2013-10 after KFO-
ret.stability pro/retr.-
note → more symmetry



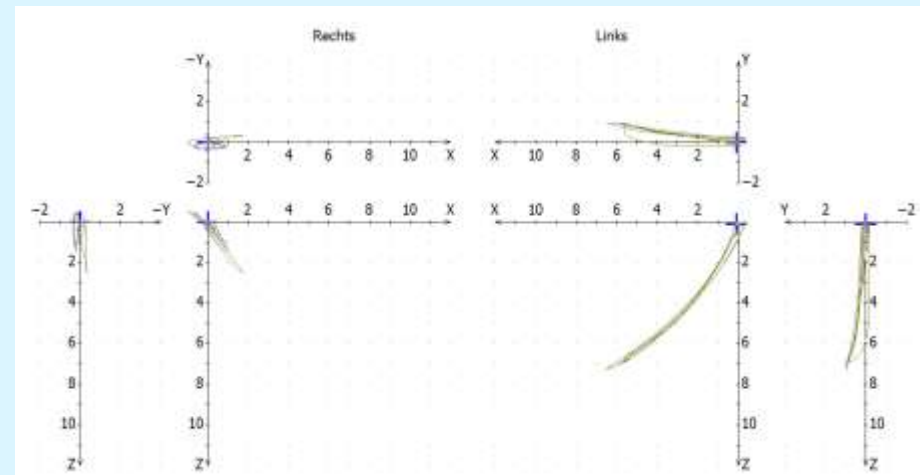
2012-03 before KFO –
 open/close → note
 → asym. and left-shift



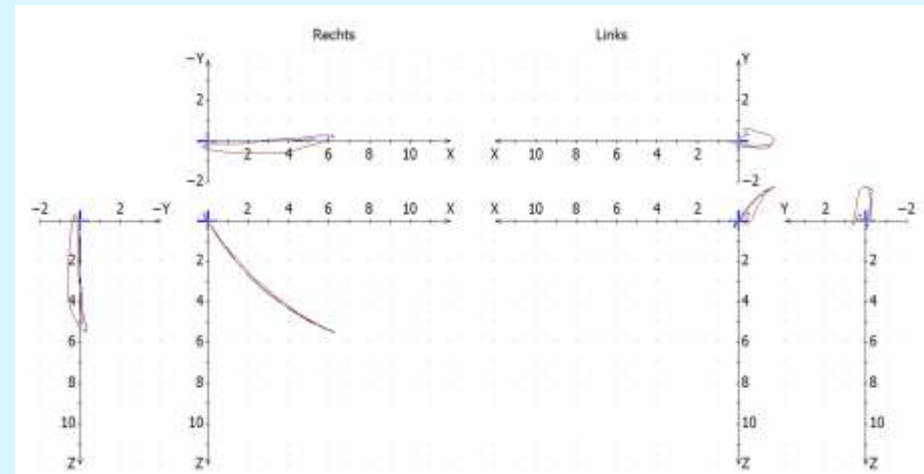
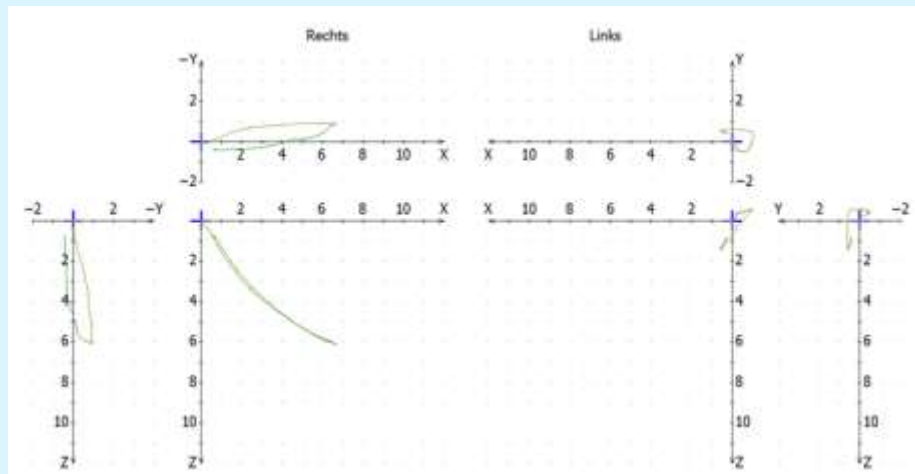
2013-10-ret.stability after
 KFO-note → more
 symmetry and no
 Bennet




2012-03 –medio left
before KFO

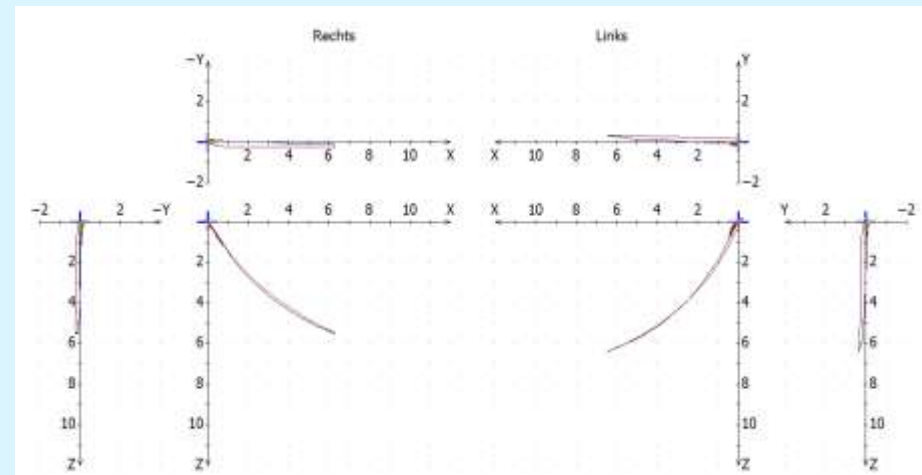


2013-10 –after KFO-
ret.stab.medio left →note
more convexity!







2012-03 before KFO
bruxing-not-left condyle
goes more distal & up



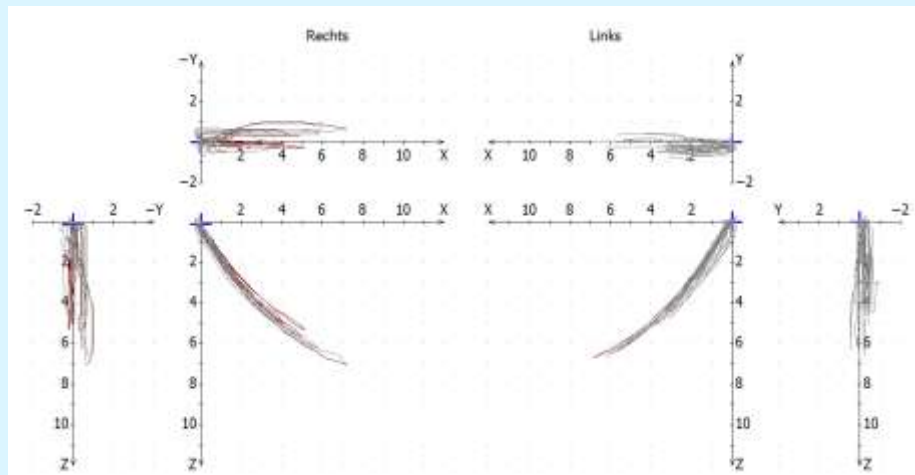
2013-10 after KFO-
bruxing → also symmetry



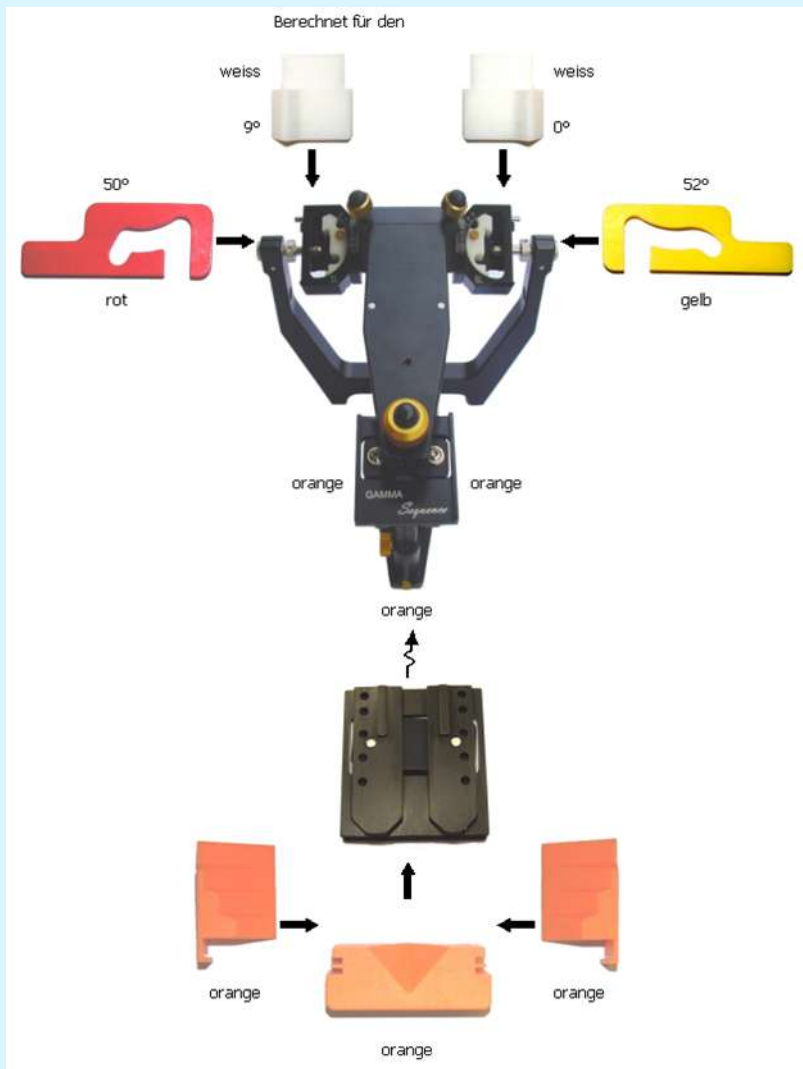
2012-03 before KFO-
 →CPM-note-RP-ICP-
 difference



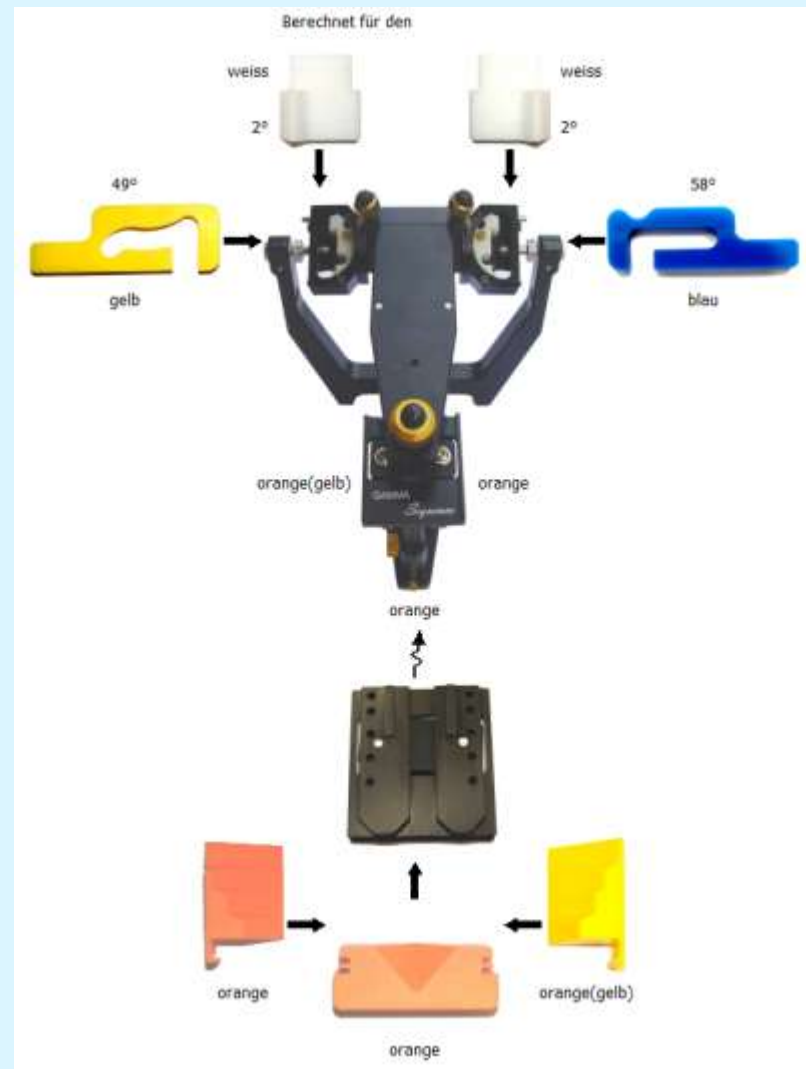
2013-10 after KFO-RP-
 ICP-note →no
 difference any more
 due to advancement of
 the mandibel!!



2012-03 before KFO-
mastication



2012-03 before KFO



2014-03 after KFO → note the equilibration of Bennet etc.

Curriculum

- 2012-03→begin of fixed KFO
- 2013-10→end of KFO(debracketing)
- -BRACKETING-TIME 1 a 7mo
- Retention with remov. upper and lower foils (0.65 Duran plus)