

Nr. 1587 9,5 Jahre weibl.

Asym. KL II/2 → MLD re.

Nur mit abn. FKO

Ausgangssituation

2001-01

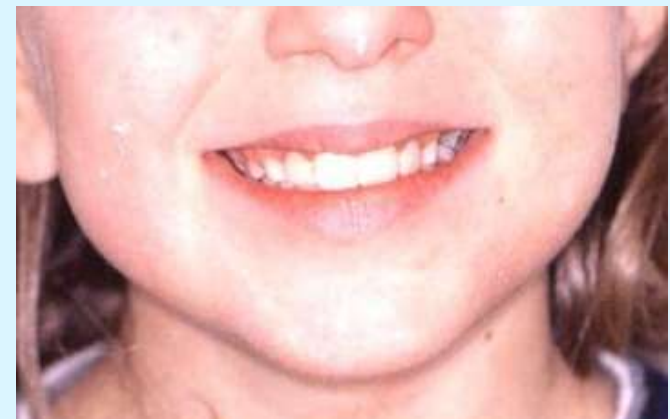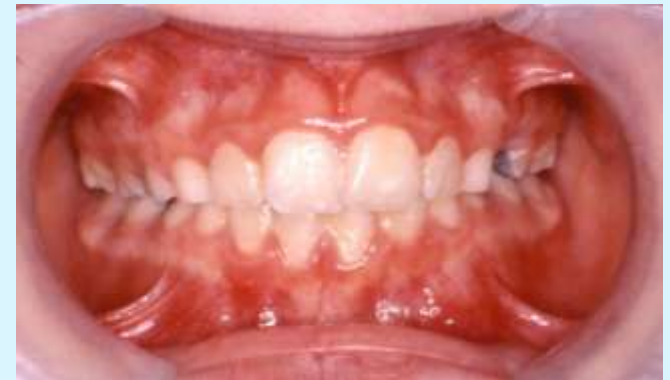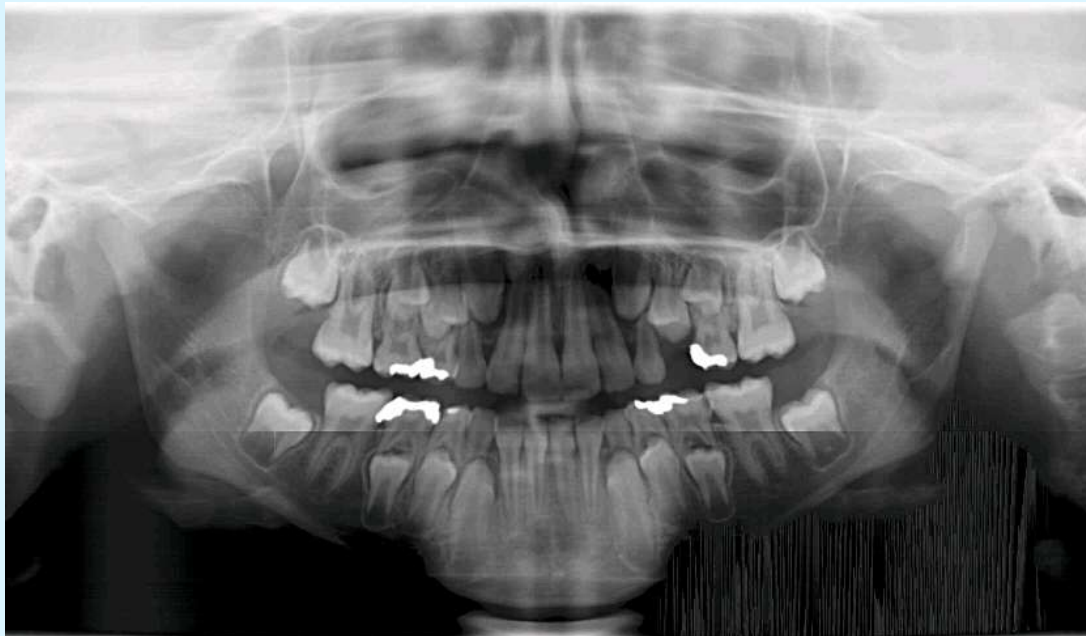Diagnose:

asym. dentoalv. KL.II/2 (rechts 3mm , links 1mm)

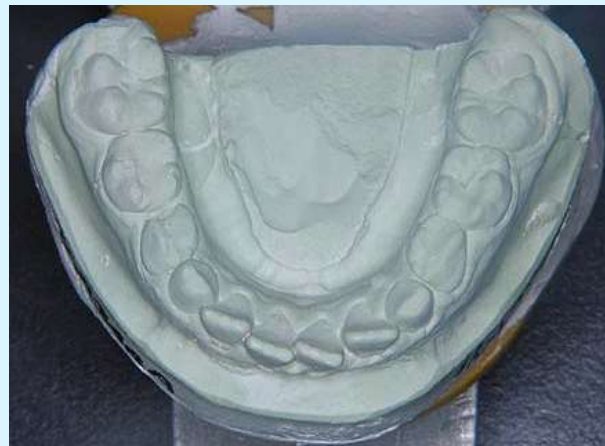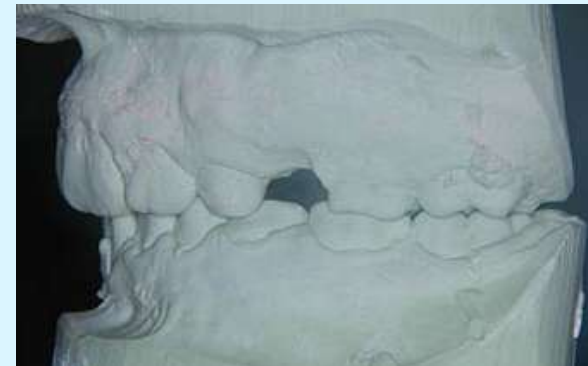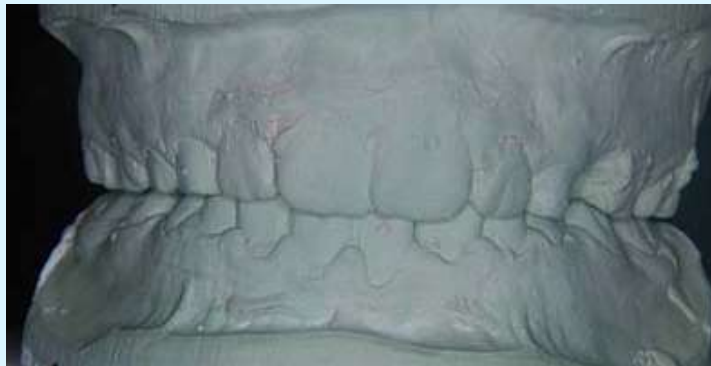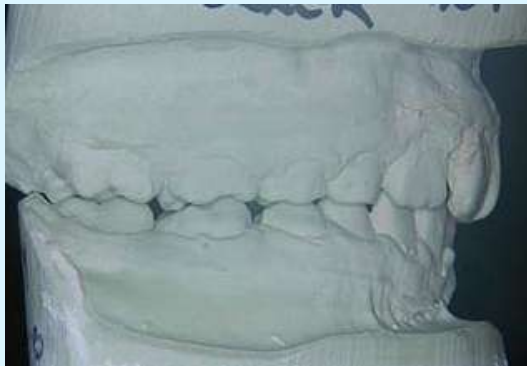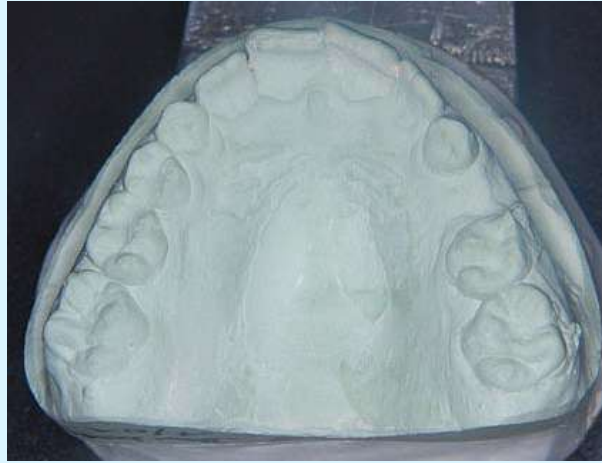MLD-re.

Raummangel im Ober – und Unterkiefer

- Steilstand der OK-Front
- UK-Front retrudiert und crowded

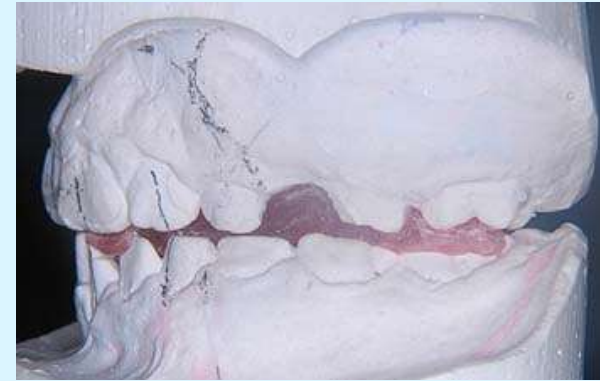
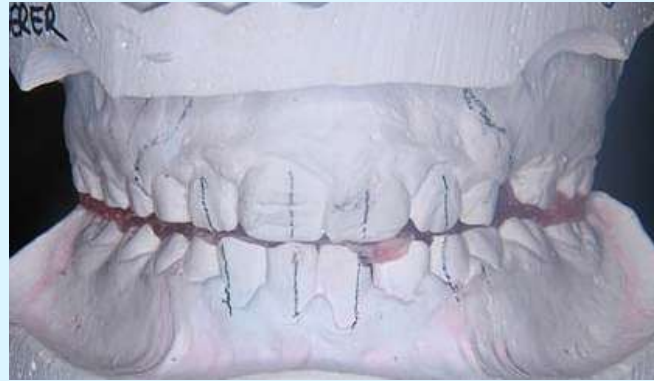
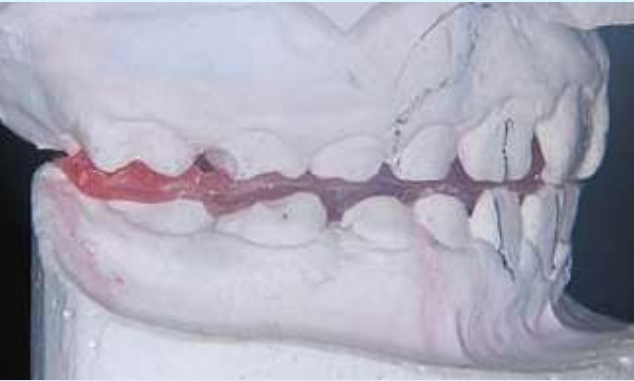
Ausgangssituation 2001-01

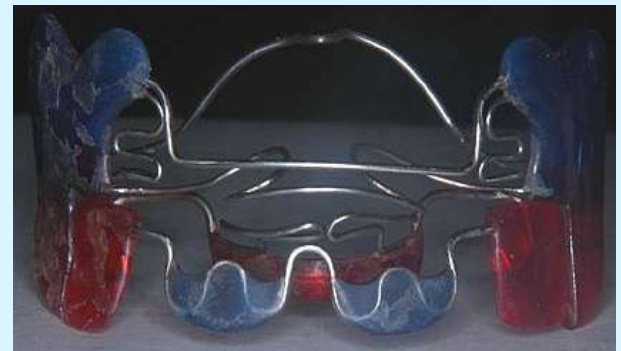

2001-01

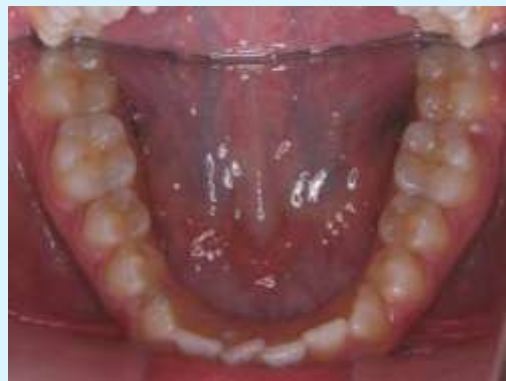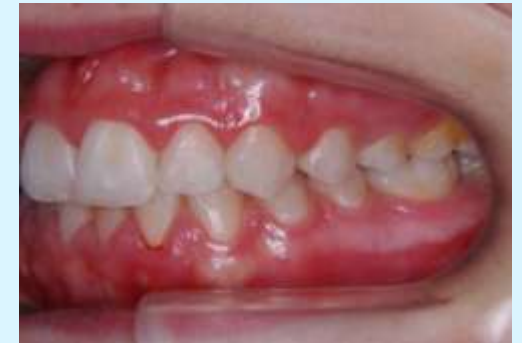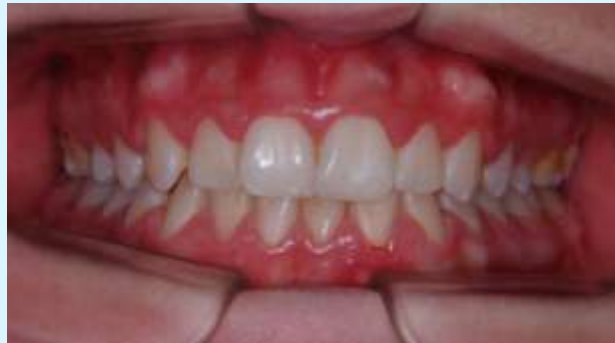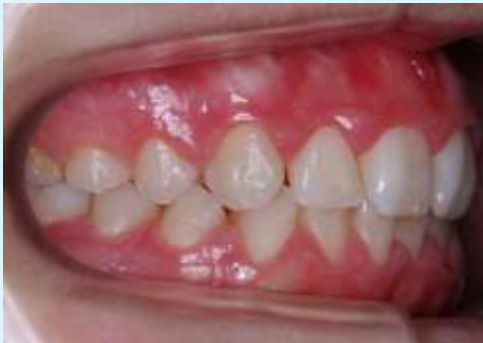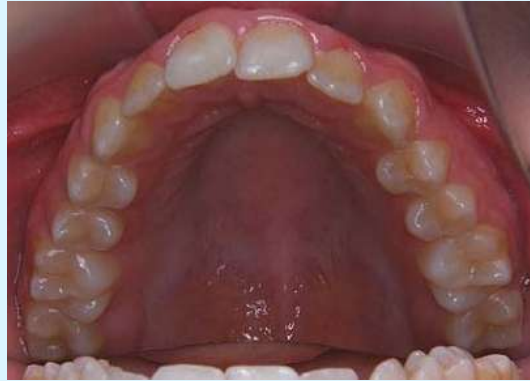Konstruktionsbiss und Fränkel II-Gerät



(KB) UK ev. nalli, komplett + Halbleitung
Fränkel II (sym)
OK-Lob. Bogen 2mm vor 21/12
OK-Vorderbogen direkt an 21/12
Rillen nachliaphil einpassen
Re. Ziele
① UK nach l. komple asym Ke II/2 (re 3 l. 1/2)

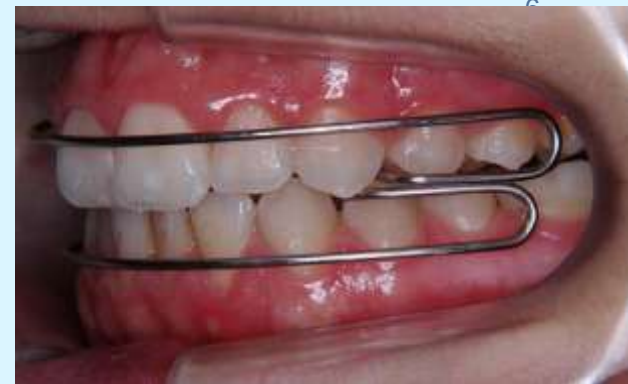
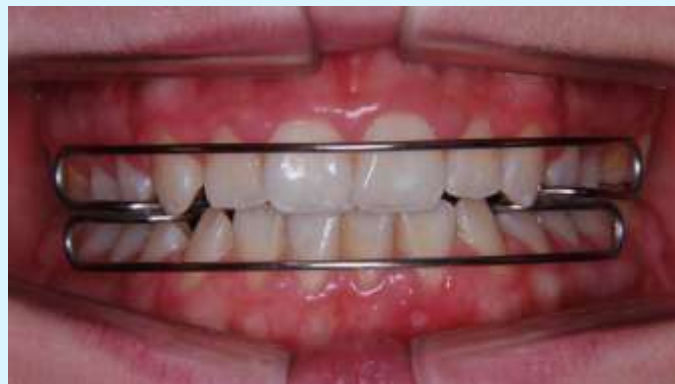
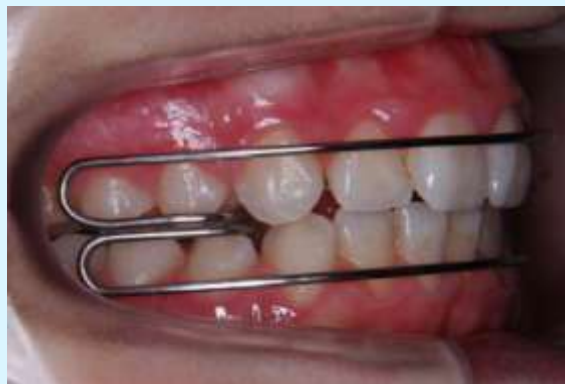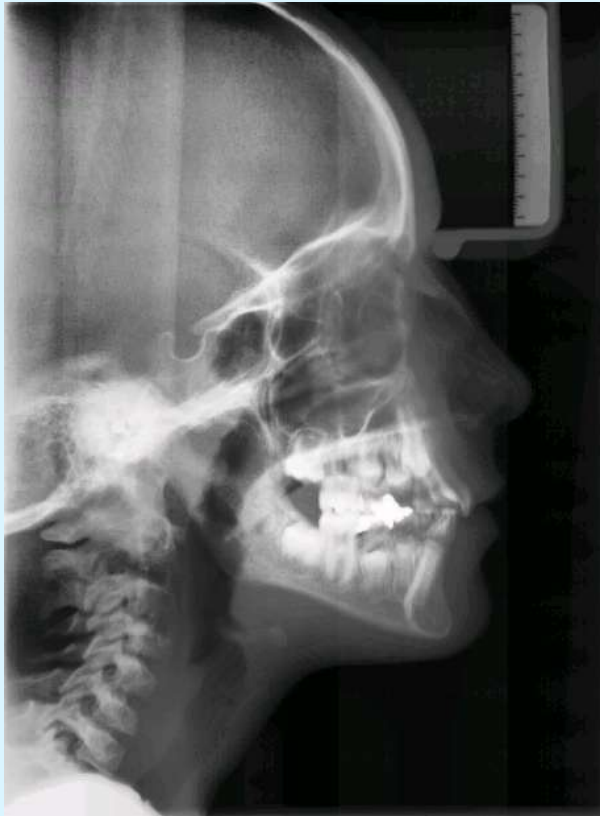After FKO 2005-08



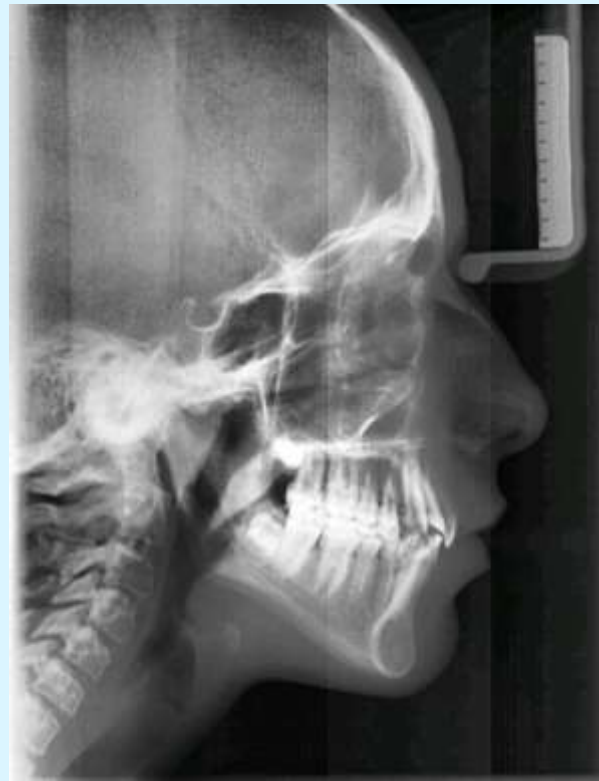2005-10

EOA (Elastisch offener Aktivator)

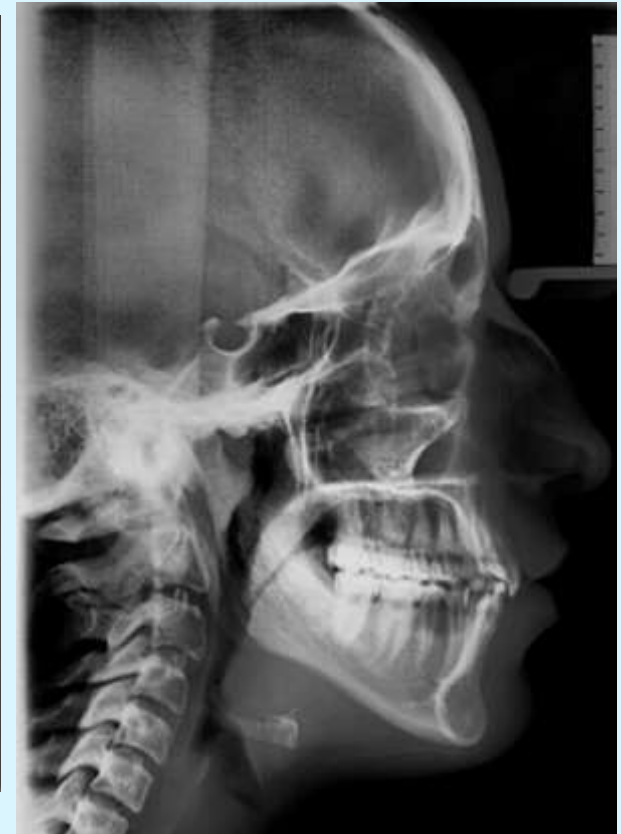



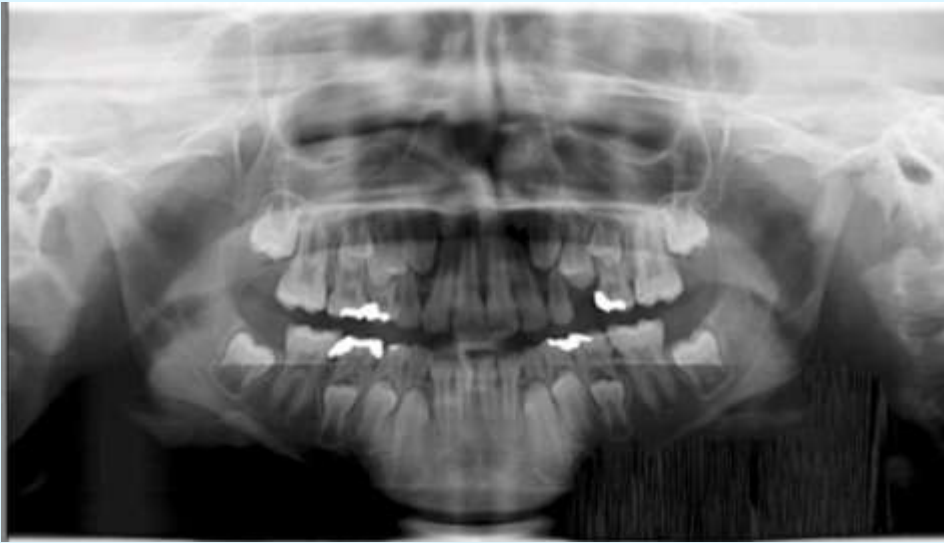2001-01 before FKO



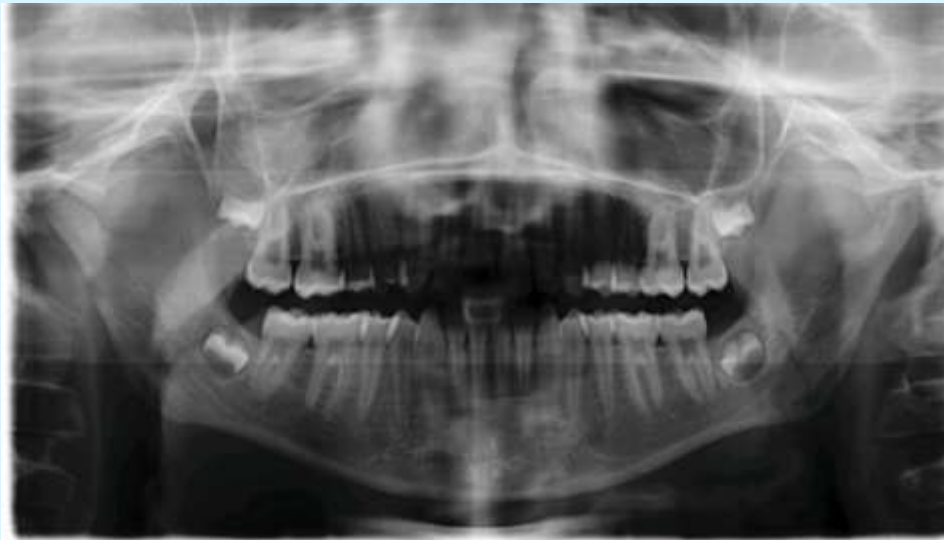2005-08 after FKO



2009-10 after Extraction
of all wisdoms
note the ant. closing Rotation
of the mandibel →
the old FKO-Appliance (EOA)
is still working, only at night

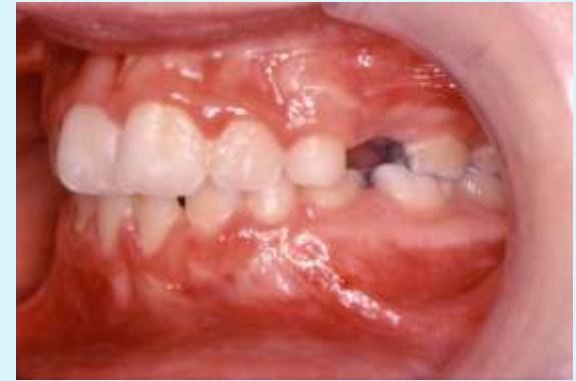
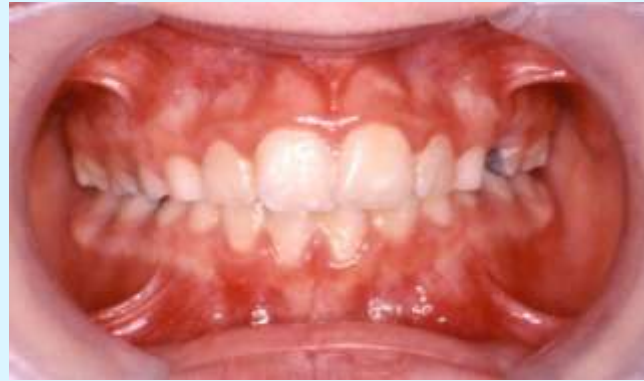
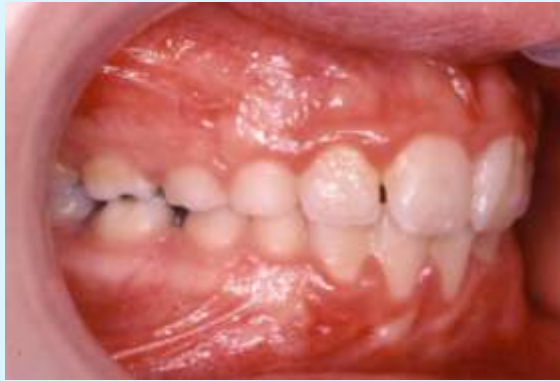2001-01 → before FKO

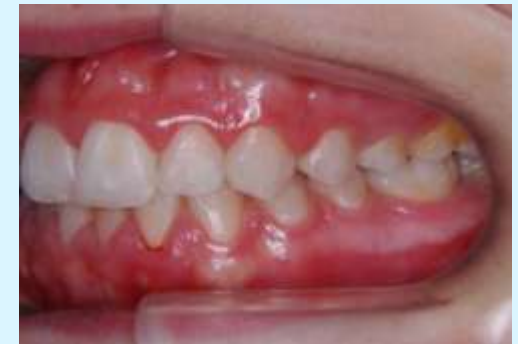
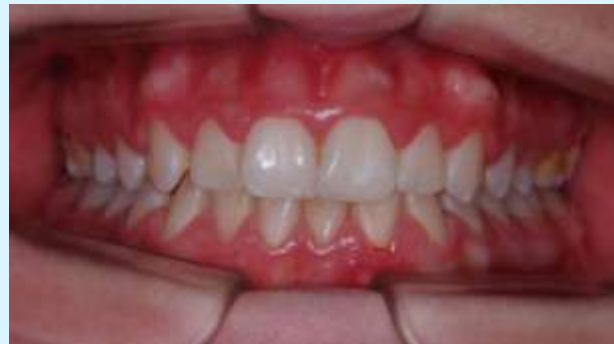
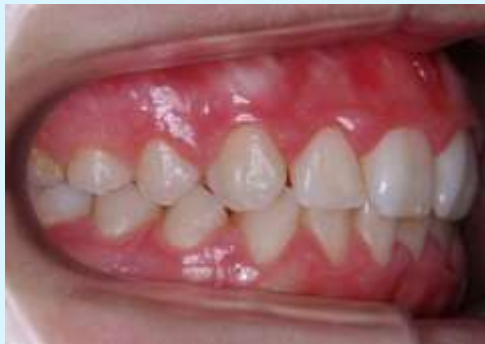2005-08 after FKO & before Extraction
of all wisdoms

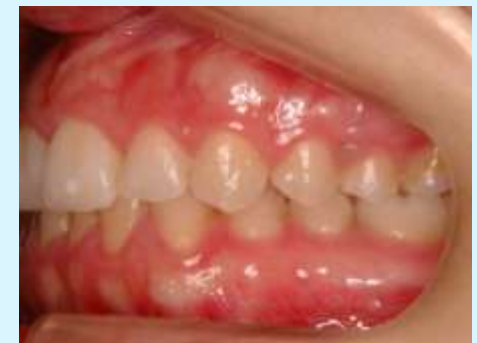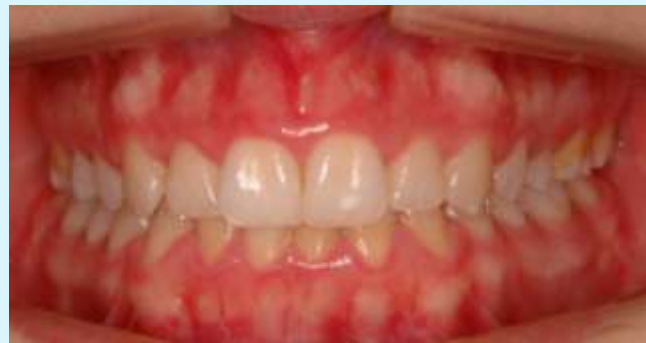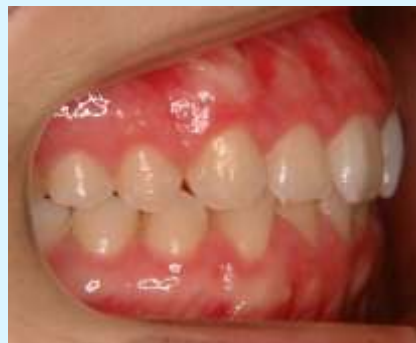Before FKO 2001-01



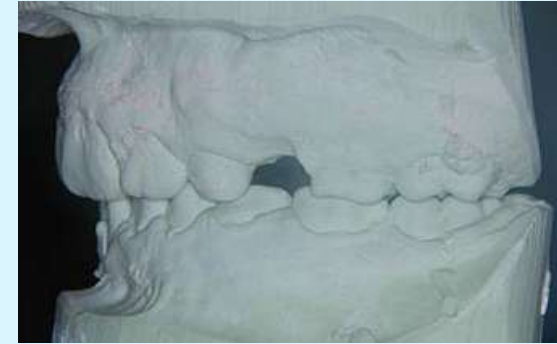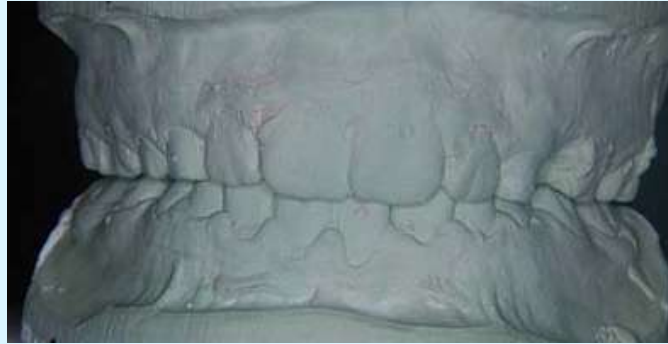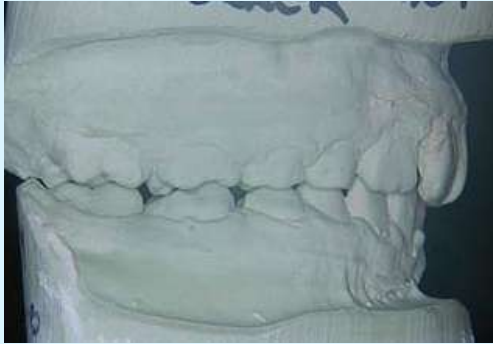After FKO 2005-08



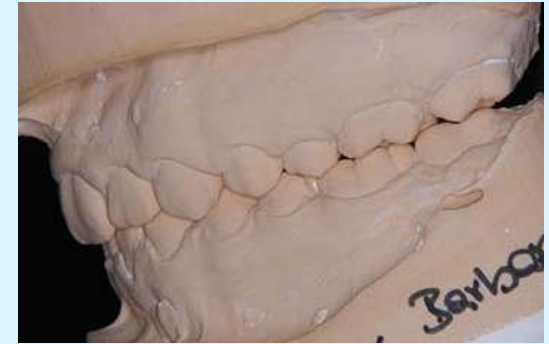
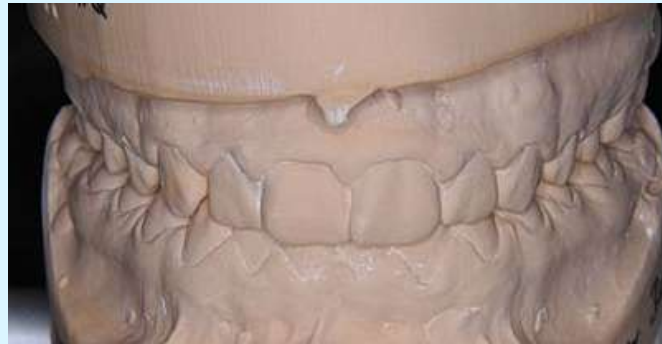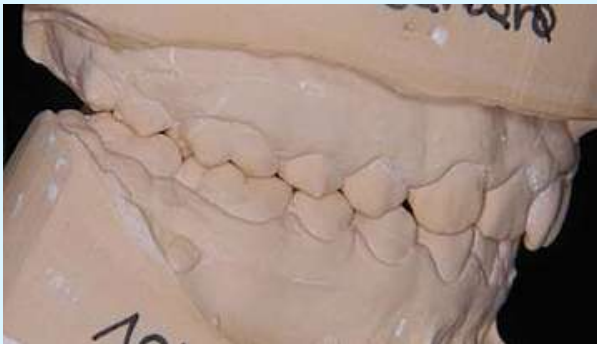After FKO 2009-10



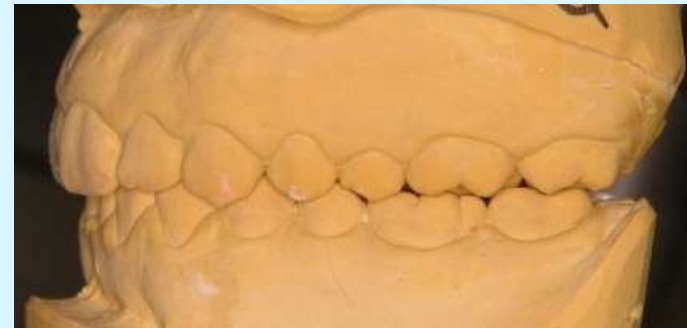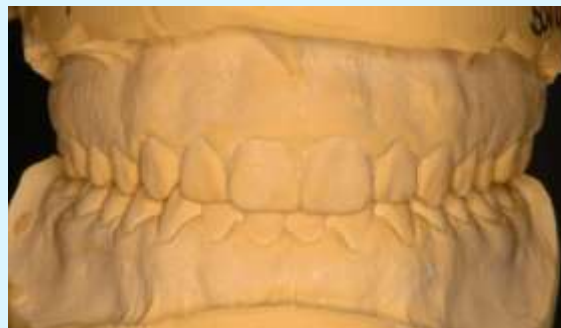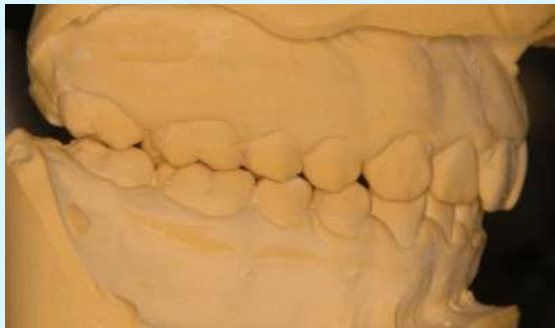Before FKO 2001-01



After FKO 2005-08



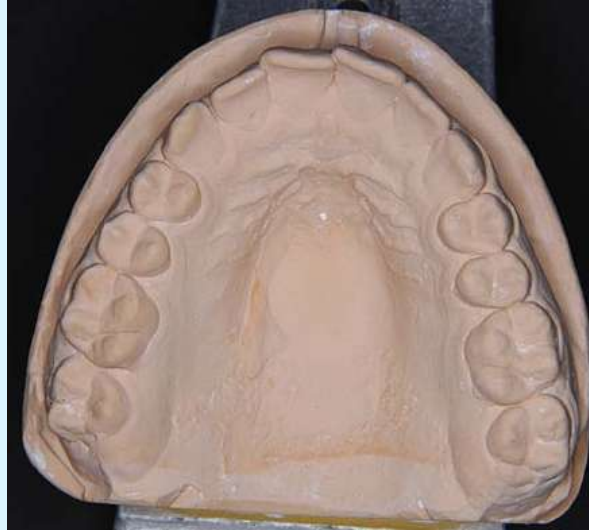After FKO 2009-10



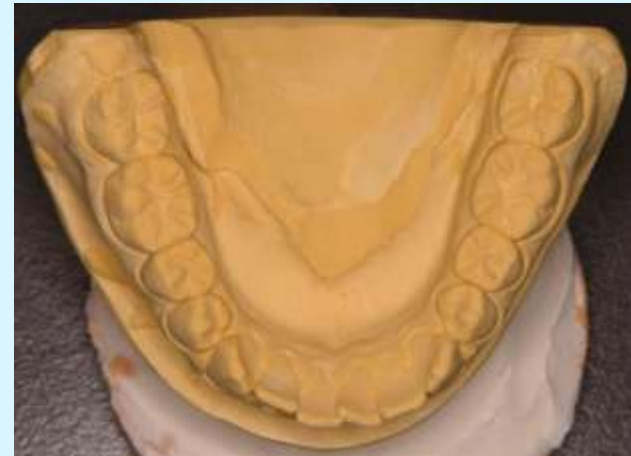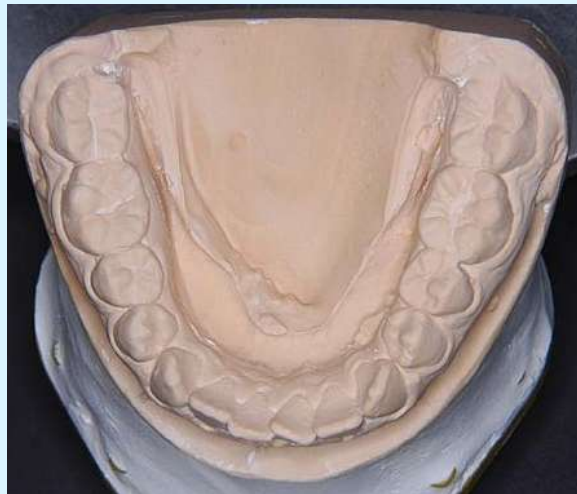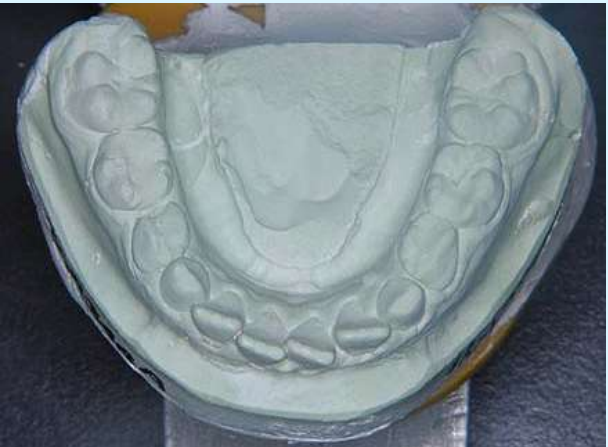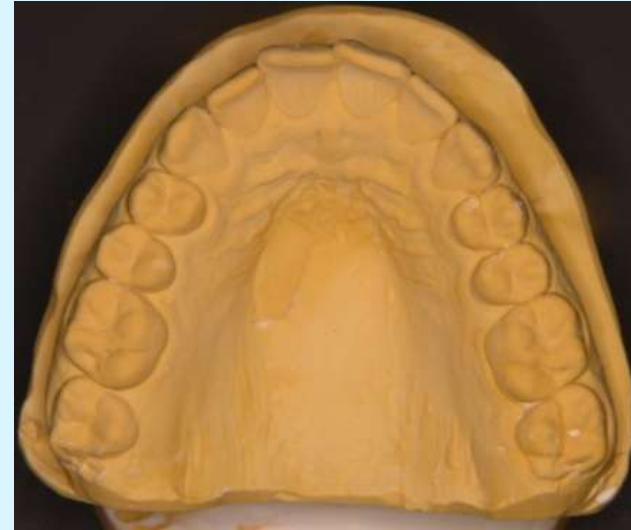Before FKO
2001-01



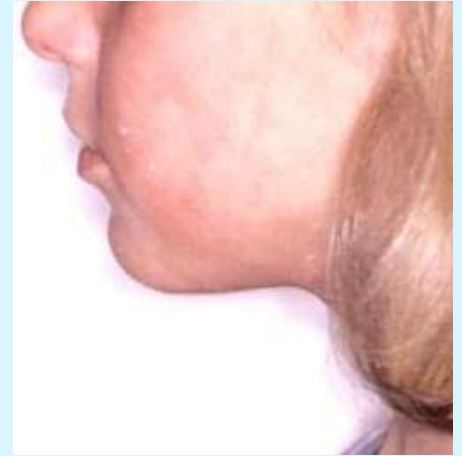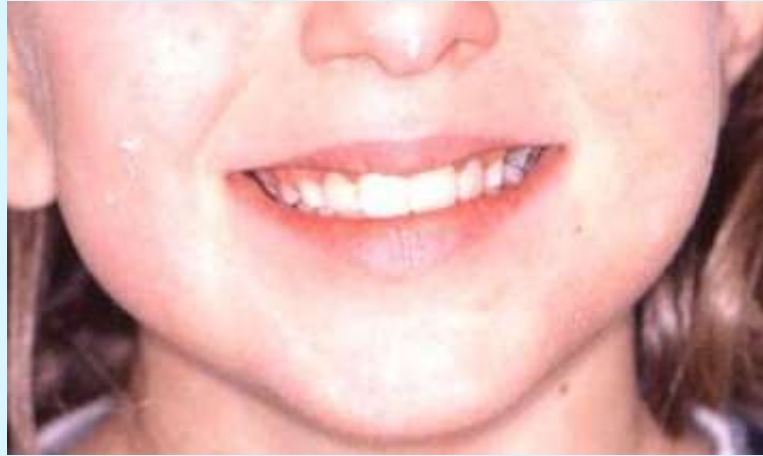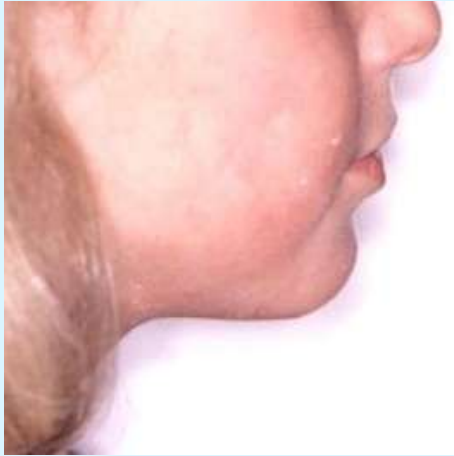After FKO
2005-08



After FKO
2009-10



Before FKO
2001-01



After FKO
2009-10

