

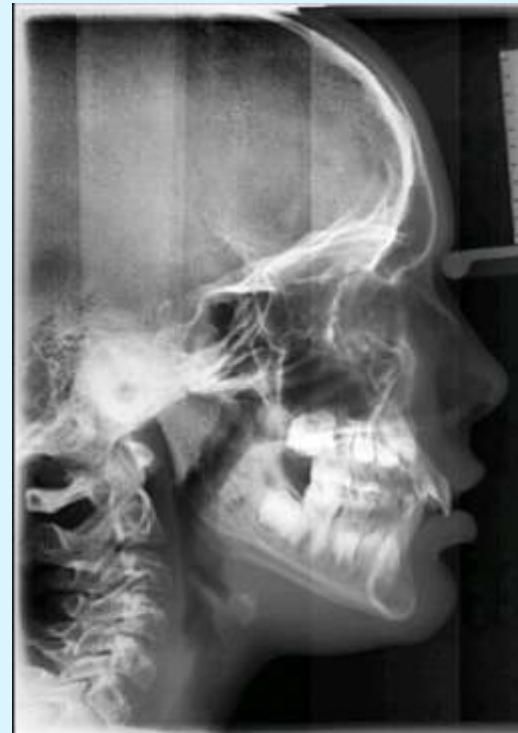Nr. 2318 8,5 Jahre weibl.

KL II/1

Große Frontzahnstufe, Überbiss

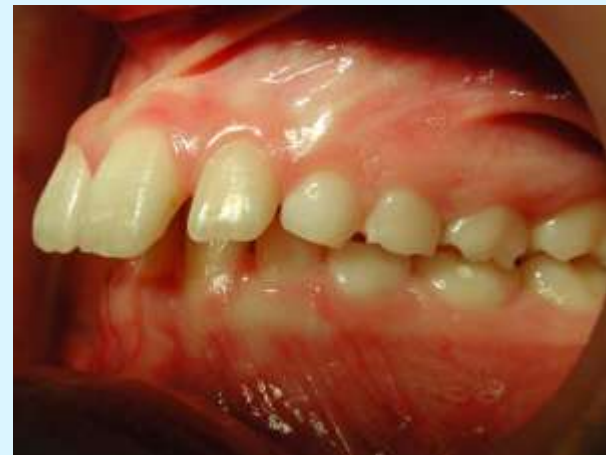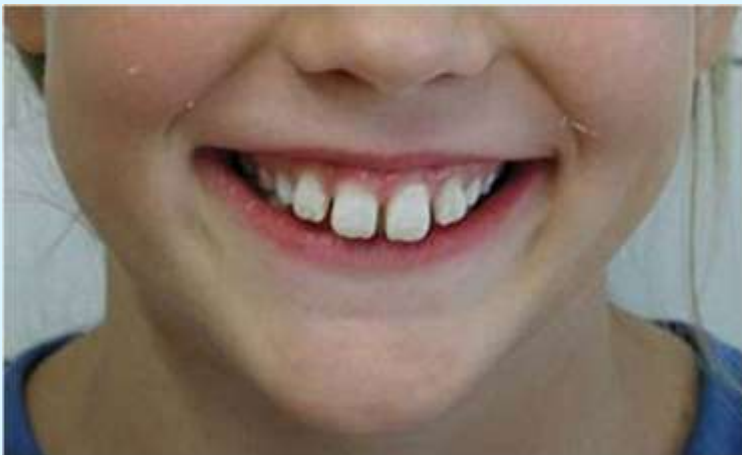Diagnosis

- Skel. CL II (mand. Retrognathie)
- Dentoalv. full CL II/1
- Overjet → 10mm
- Overbite → 3mm
- Upper frontflaring with gummy smile

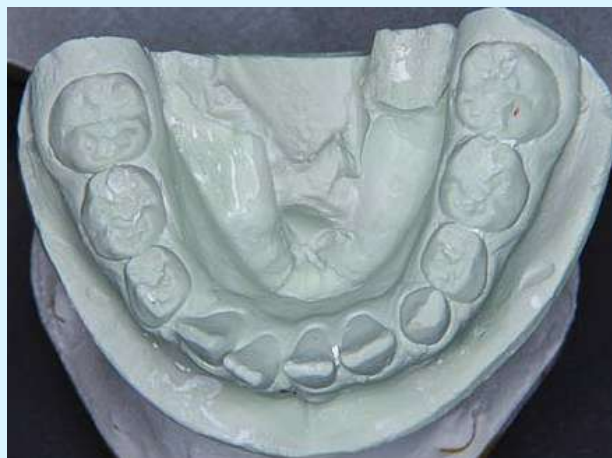
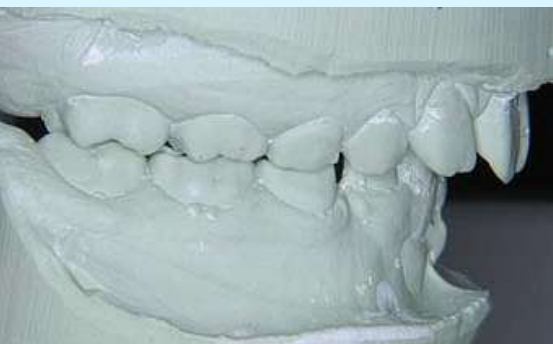
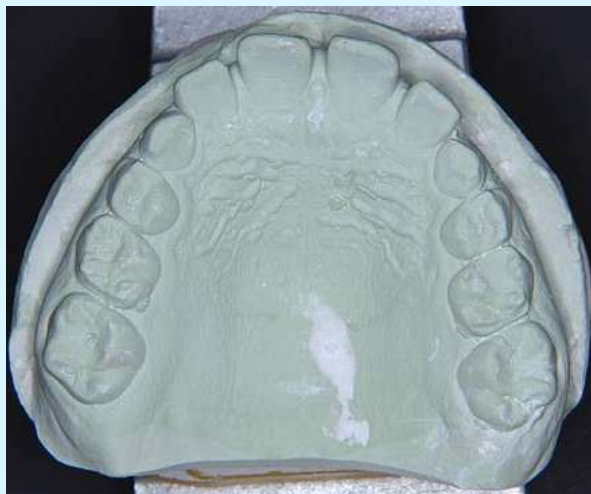Initial Situation:

2004-08



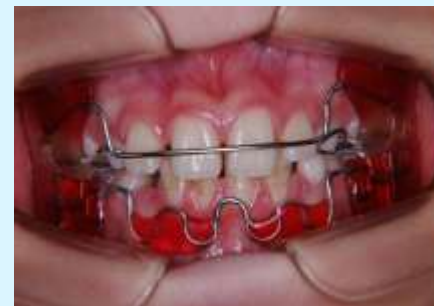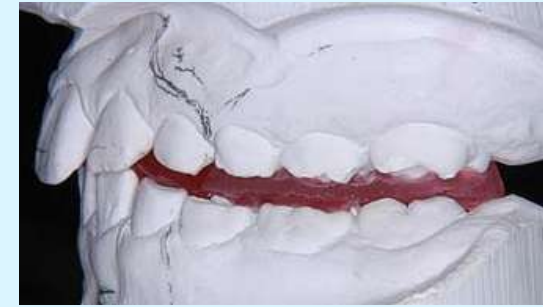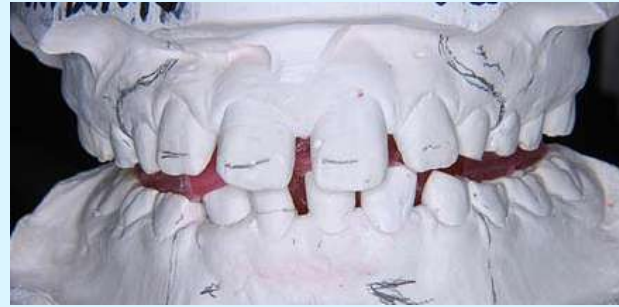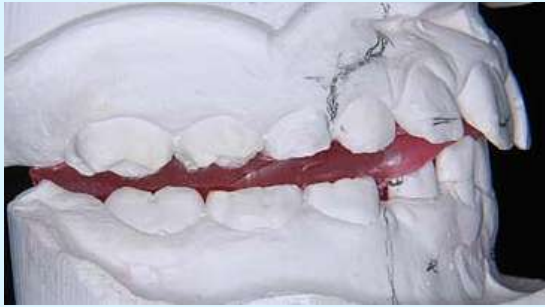Initial Situation:

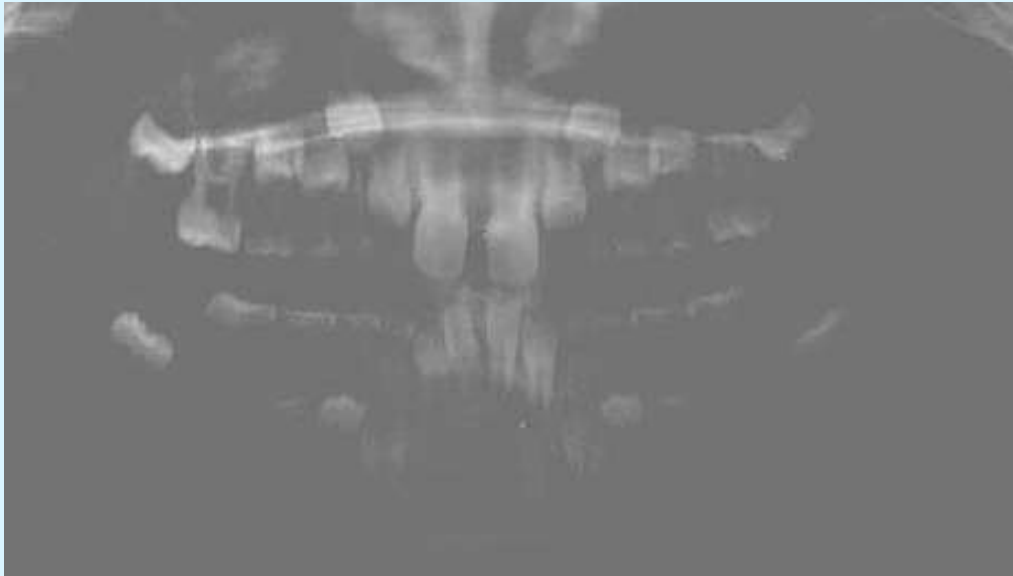

Treatment Plan

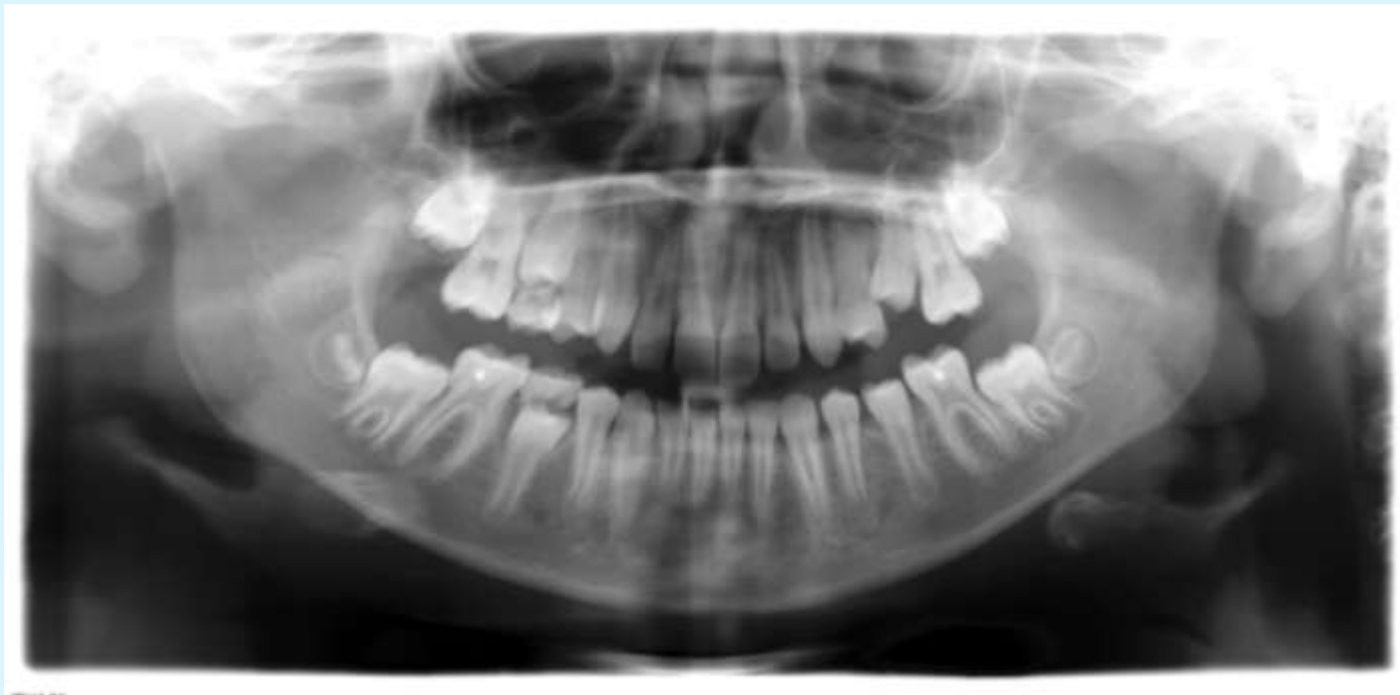- At first FKO with remov. FKO-appliance (Fränkel-1c)
- Goals:
 - 1) Ant. displacement of the mandibel step by step to CL I relation
 - 2) Bite rising (Verticalisation)
 - 3) Retrusion of the protruded upper front

Konstruktionsbiss und Fränkel-Gerät



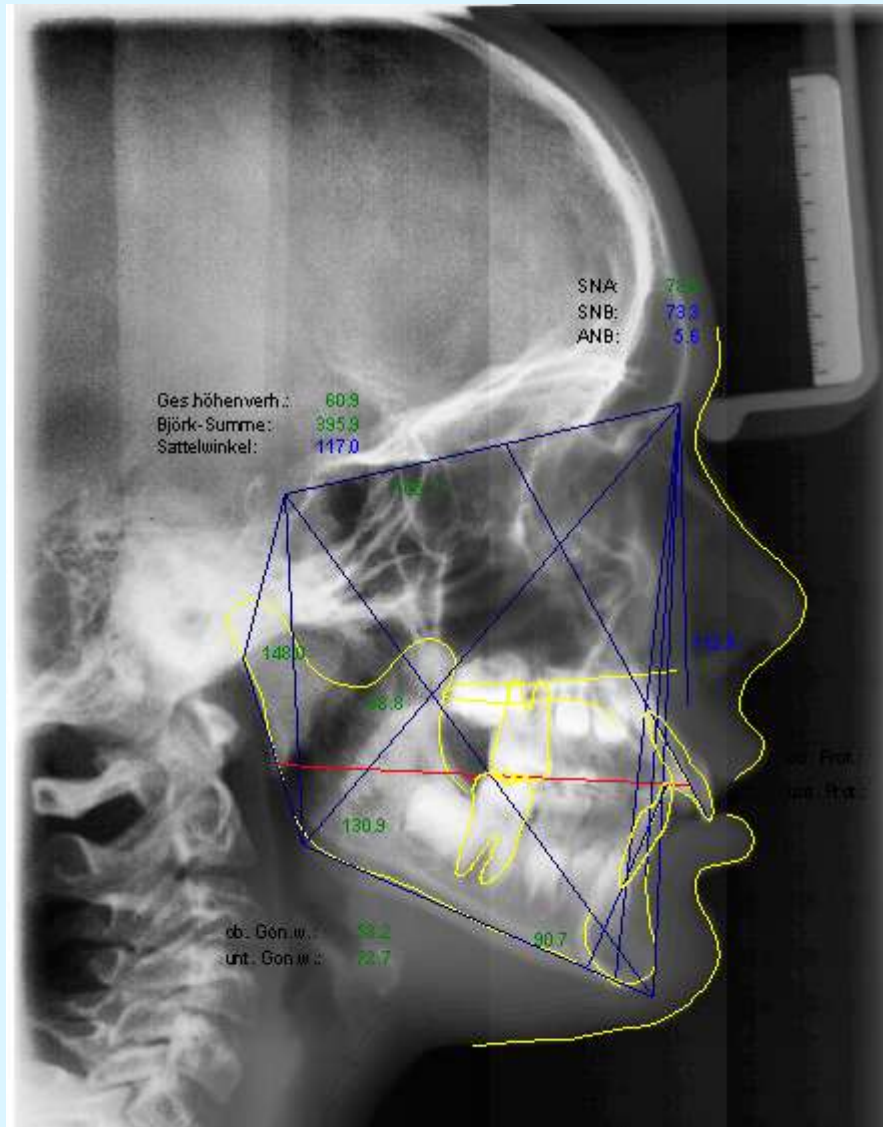


2003-01
before FKO

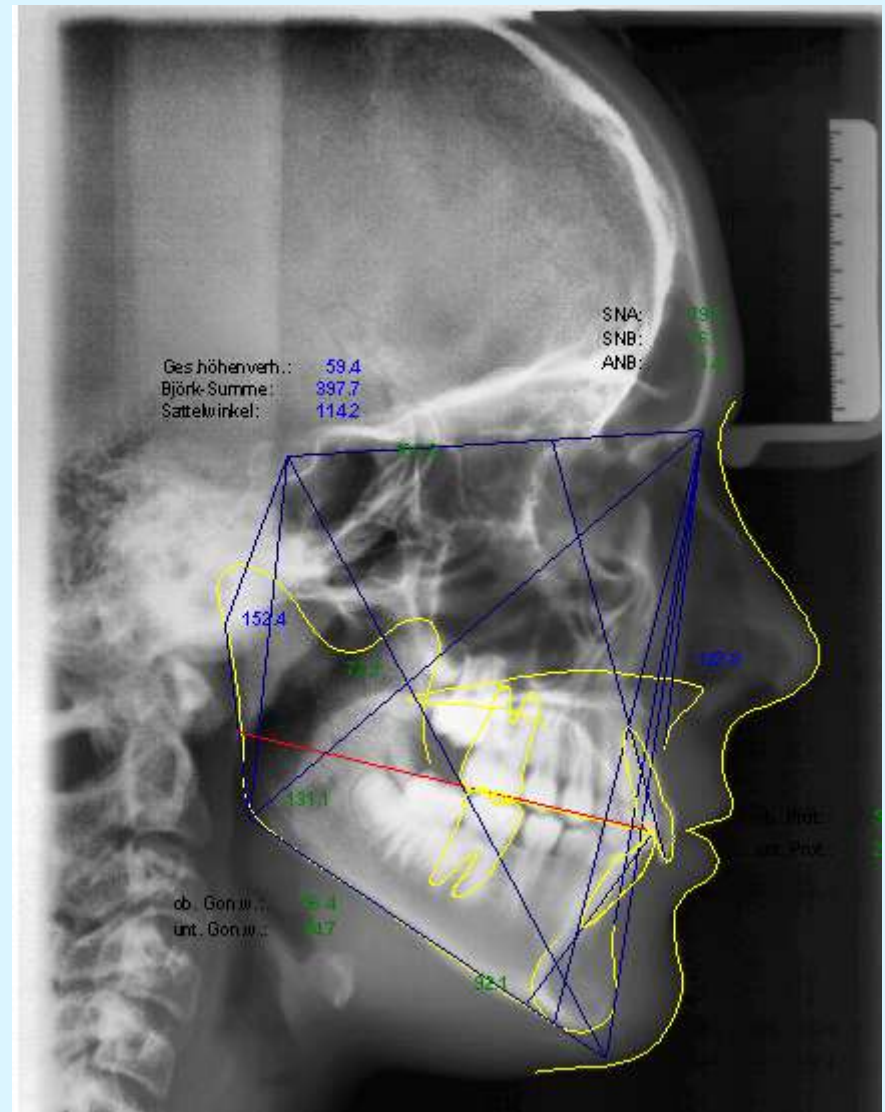


2006-11
during FKO

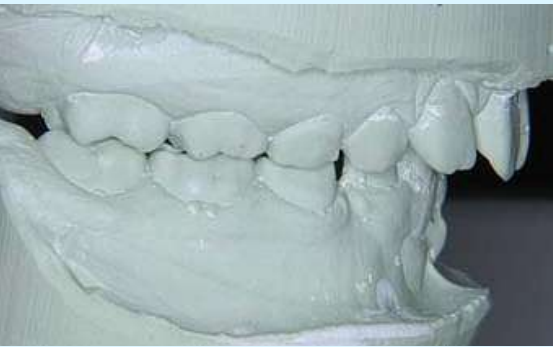2004-08 before FKO



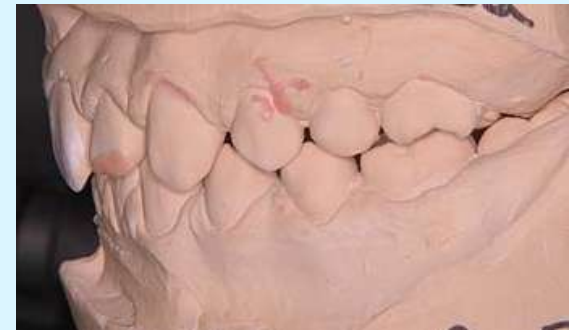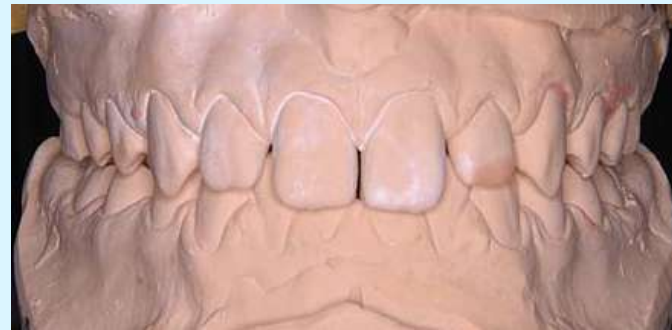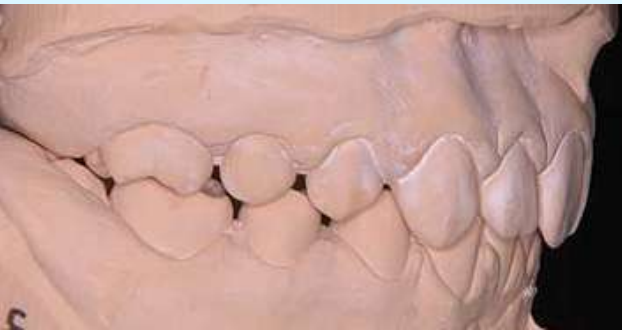2007-05 after 2a FKO



2004-08 before FKO



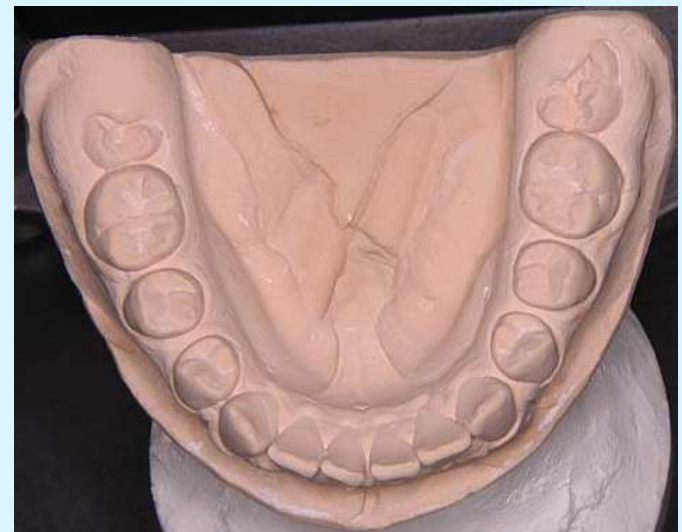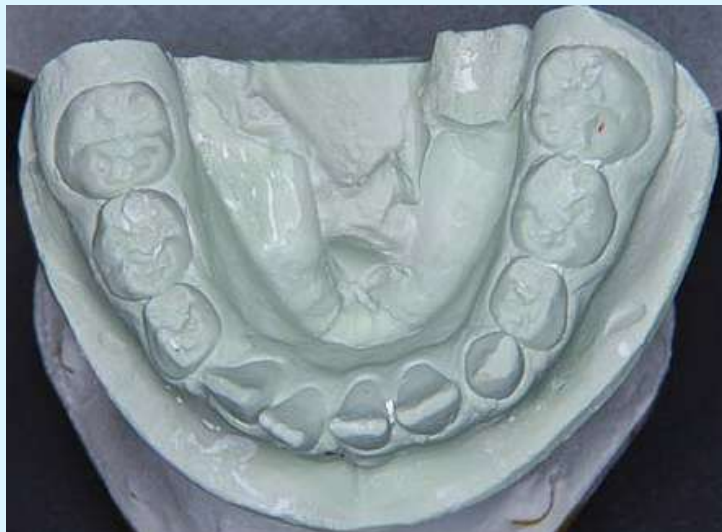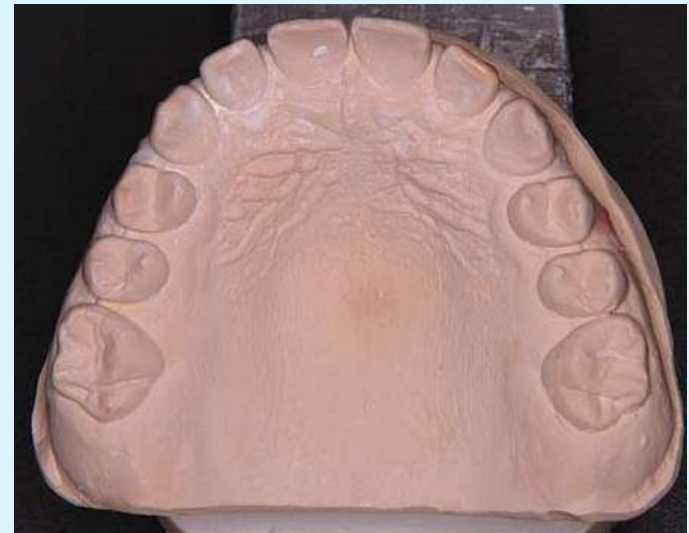2007-05 after 2a FKO



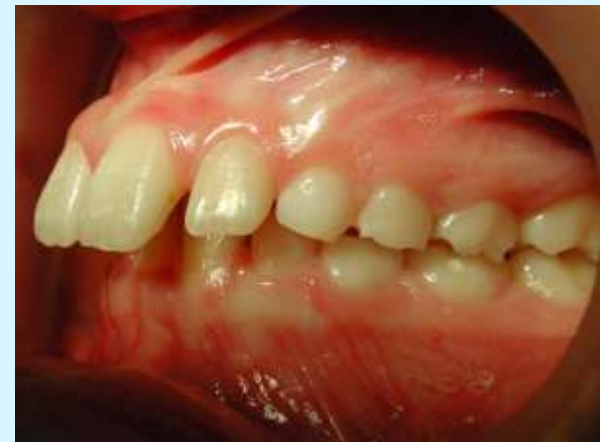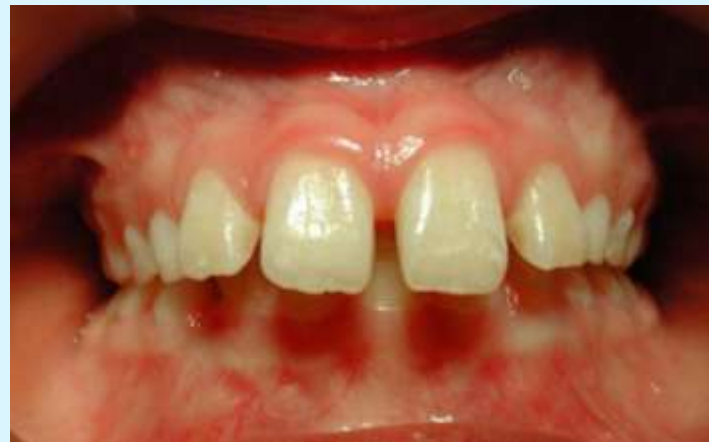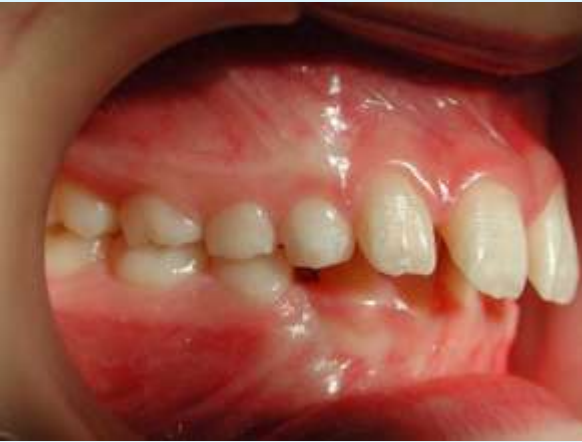2004-08 before FKO



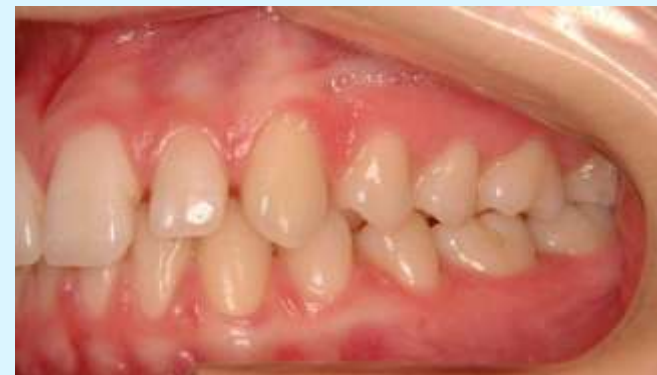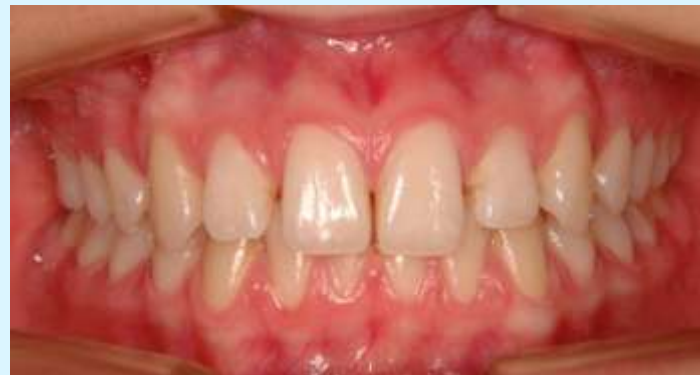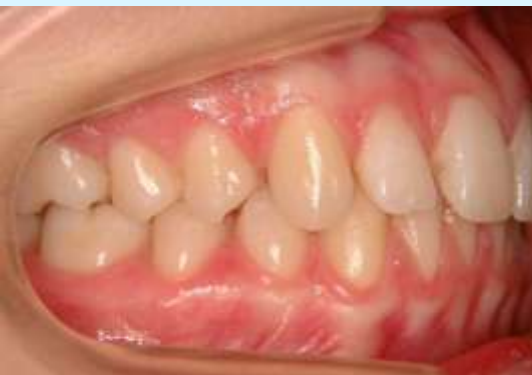2007-05 after 2a FKO



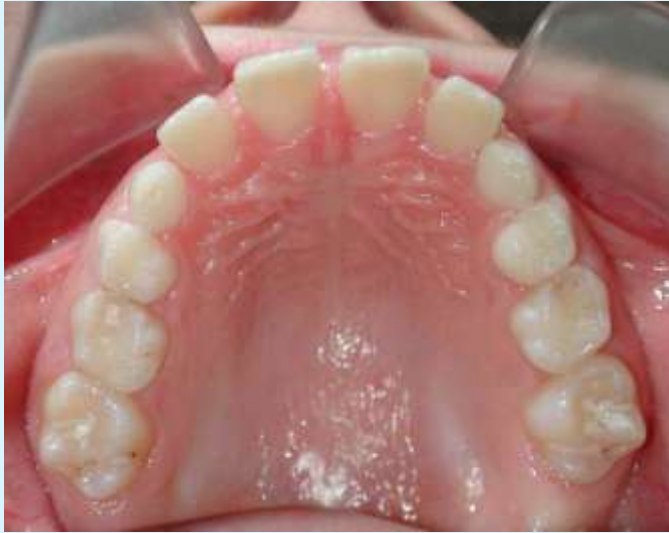2004-08 before FKO



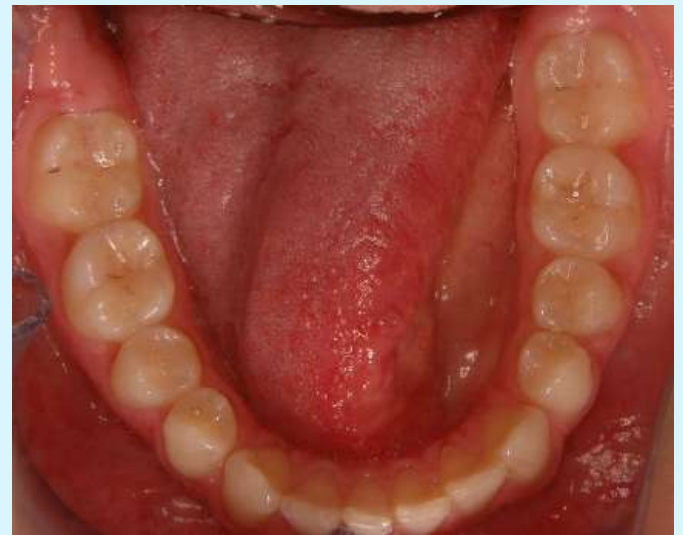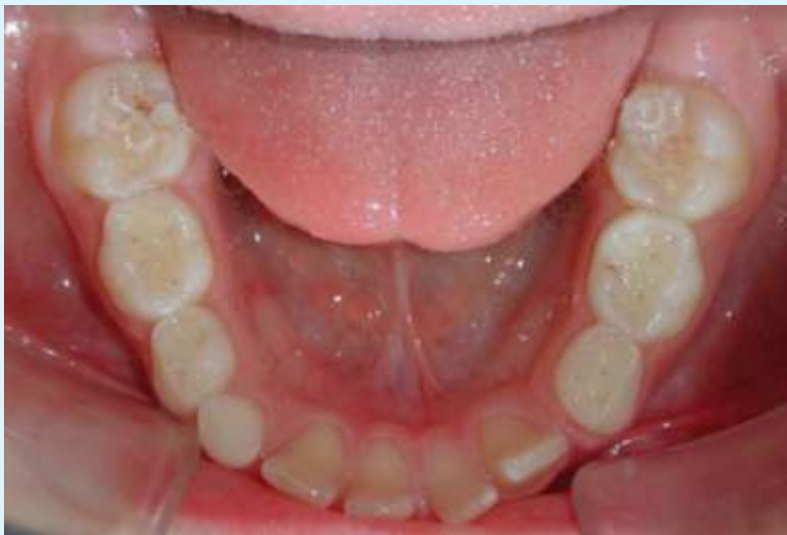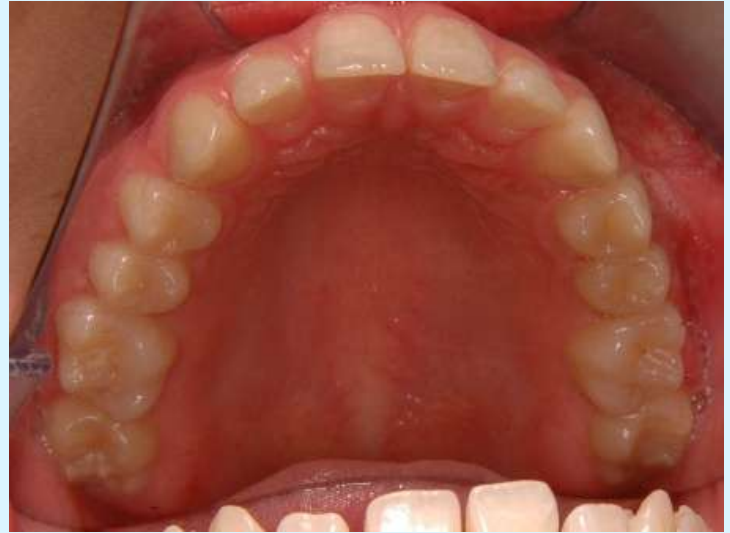2007-05 after 2a FKO



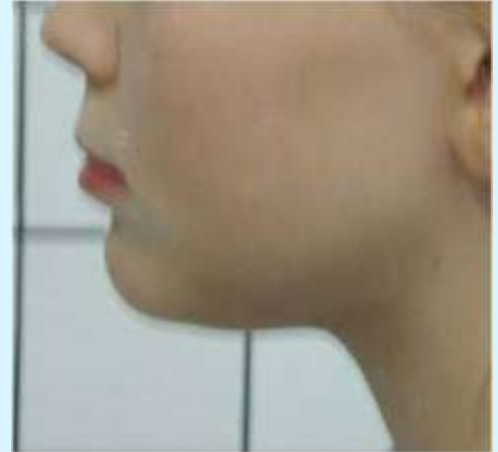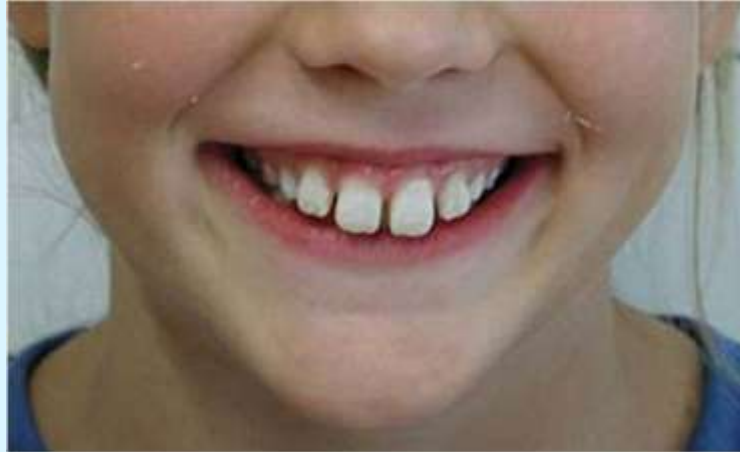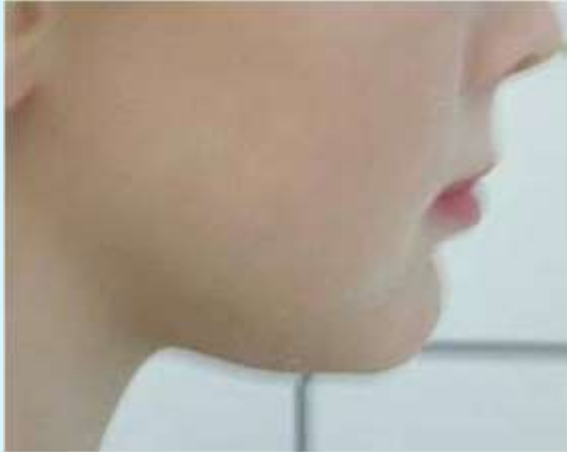2004-08 before FKO



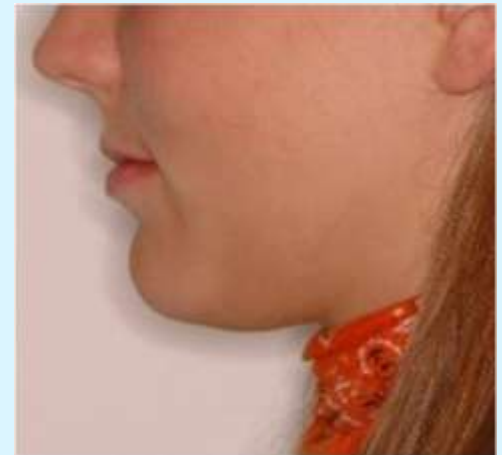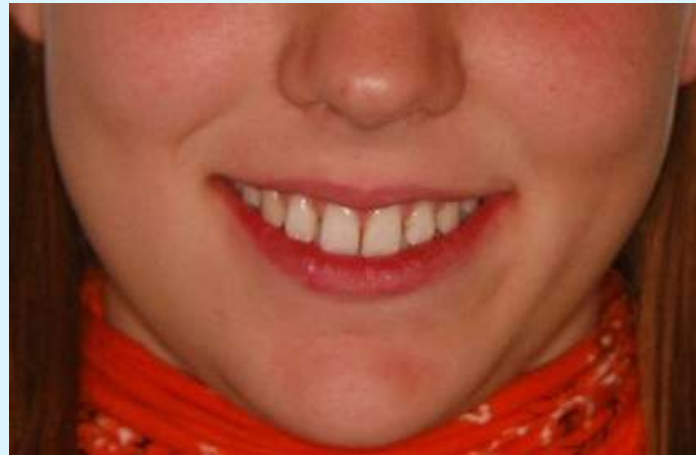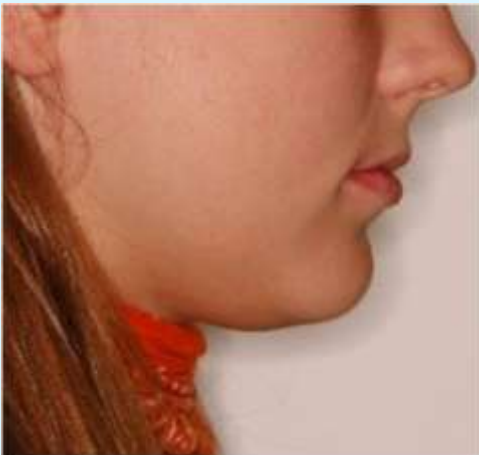2007-05 after 2a FKO



2004-08 before FKO



2007-05 after 2a FKO



Curriculum

- 2004-08 → Beginning of FKO with Fränkel 1c
- 2007-05 → only ant. displacement in the lower part of the orig. Fränkel 1c for further anterior conditioning of the mandibular
- Very good compliance!!!!!!!!!!!!!!
- 2009-07 → after eruption of the second molars the patient does not need any fixed KFO treatment!!
- Patient and her family are very happy!!